frontiers in Medicine

TYPE Case Report
PUBLISHED 09 November 2026
DOI 10.3389/fmed.2026.1957144

Check for updates

OPEN ACCESS

EDITED BY
Dong Liu,
China-Japan Friendship Hospital, China

REVIEWED BY
Jose Luis Patier De La Peña,
Ramón y Cajal University Hospital, Spain
Jinzhi Wang,
Chinese Academy of Medical Sciences & Peking Union Medical College, China

*CORRESPONDENCE
Zheng Zhang
faithword@163.com

†These authors have contributed equally to this work and share first authorship

RECEIVED 03 August 2026
REVISED 19 October 2026
ACCEPTED 21 October 2026
PUBLISHED 09 November 2026

CITATION
Lu X, Liu C, Wang Y, Wang D, Zhang L and Zhang Z (2026) Hereditary hemorrhagic telangiectasia type 1 with an ENG nonsense mutation presenting with severe pulmonary hypertension and recurrent pulmonary arteriovenous malformations in a nonagenarian: a case report.
Front. Med. 13:1957144.
doi: 10.3389/fmed.2026.1957144

COPYRIGHT
© 2026 Lu, Liu, Wang, Wang, Zhang and Zhang. This is an open-access article distributed under the terms of the Creative Commons Attribution License (CC BY). The use, distribution or reproduction in other forums is permitted, provided the original author(s) and the copyright owner(s) are credited and that the original publication in this journal is cited, in accordance with accepted academic practice. No use, distribution or reproduction is permitted which does not comply with these terms.

Hereditary hemorrhagic telangiectasia type 1 with an ENG nonsense mutation presenting with severe pulmonary hypertension and recurrent pulmonary arteriovenous malformations in a nonagenarian: a case report

Xiaojiong Lu[1†], Chenxi Liu[2†], Ying Wang[1], Dongxia Wang[1], Lina Zhang[1] and Zheng Zhang[1*]

[1]Chinese People's Liberation Army Rocket Force Characteristic Medical Center, Beijing, China, [2]The Graduate Training Base of Jinzhou Medical University, Chinese People's Liberation Army Rocket Force Characteristic Medical Center, Beijing, China

Background: Hereditary hemorrhagic telangiectasia type 1 (HHT1) is caused by mutations in the ENG gene, with functional deficiency of endoglin serving as the core pathogenic mechanism leading to multiple arteriovenous malformations. Nonsense mutations in ENG typically result in a truncated protein and induce haploinsufficiency, representing a key pathogenic mechanism underlying HHT1.
Case presentation: We report a 90-year-old patient with HHT1 presenting with spontaneous epistaxis, lingual telangiectasias, and recurrent pulmonary arteriovenous malformations (PAVMs). The patient had undergone surgical resection of PAVMs in 1956 and 2000, and presented this time with recurrent PAVMs complicated by pulmonary hypertension. Genetic testing identified a heterozygous nonsense mutation c.229C>T (p.Gln77Ter) in the ENG gene.
Conclusion: This case highlights the need for lifelong surveillance for PAVMs recurrence in ENG mutation carriers. Furthermore, it underscores that in very elderly patients with HHT, management should shift toward an individualized, patient-centered conservative approach.

KEYWORDS
ENG gene, epistaxis, hereditary hemorrhagic telangiectasia, pulmonary arteriovenous malformation, pulmonary hypertension

1 Introduction

Hereditary hemorrhagic telangiectasia (HHT), also known as Osler-Weber-Rendu syndrome, is an autosomal dominant vascular disorder with an estimated prevalence of 1/5,000 (1). Pulmonary arteriovenous malformations (PAVMs) and pulmonary hypertension (PH) are well-recognized complications that can lead to severe clinical sequelae (2). The primary causative genes are *ENG* and *ACVRL1*, which encode endoglin and activin receptor-like kinase 1 (ALK-1), respectively. Both proteins serve as key endothelial receptors in the transforming growth factor-β (TGF-β) superfamily

signaling pathway (3). *ENG* mutations cause HHT1, which is mainly associated with pulmonary and cerebral arteriovenous malformations (AVM), whereas *ACVRL1* mutations cause HHT2, which is more frequently linked to hepatic VAM (3, 4). We report the case of a 90-year-old patient who presented with recurrent PH and PAVMs. The patient was admitted with exertional dyspnea. Physical examination revealed spontaneous epistaxis and lingual telangiectasias. Subsequent imaging studies confirmed recurrent PH and PAVMs. Genetic testing identified a heterozygous nonsense mutation in *ENG* gene (c.229C>T, p.Gln77Ter), confirming the diagnosis of hereditary HHT1. This case highlights the importance of considering HHT in patients with recurrent PH and PAVMs.

2 Case presentation

2.1 Clinical Presentation and Diagnosis

A 90-year-old man presented with worsening exertional dyspnea of 6-month duration, along with fatigue, reduced exercise tolerance, and anorexia, but no chest pain, palpitations, or dizziness. Despite receiving home oxygen therapy, dyspnea had significantly worsened over the 4 days prior to admission. The patient's past medical history was notable for surgical resection of the left lower lobe in 1956 due to a pulmonary arteriovenous fistula, followed by interventional embolization of a left upper lobe arteriovenous fistula in 2000. He had a 20-year history of atrial fibrillation (AF), for which he was on long-term oral bisoprolol fumarate (2.5 mg qd) and dabigatran etexilate (0.11 g bid) for anticoagulation. In addition, he had a 9-year history of chronic lymphocytic leukemia (CLL) without active treatment, and a 50-year history of a left foot cavernous hemangioma that had not been treated.

On admission, the patient presented with an oxygen saturation of 80% on room air and bilateral lower extremity edema. Physical examination revealed a temperature of 36.2°C, a heart rate of 99 bpm with an irregularly irregular rhythm, and a respiratory rate of 20 breaths/min. Telangiectasias were observed on the tongue (Figure 1A), a cavernous hemangioma on the left foot (Figure 1B), and nasal mucosal bleeding was noted on electronic nasopharyngoscopy (Figure 1C). Laboratory findings showed a C-reactive protein (CRP) level of 1.50 mg/L, a white blood cell (WBC) count of 36.56×10^9/L, a neutrophil percentage of 10.6%, and a lymphocyte percentage of 87.8%. Under 33% fraction of inspired oxygen, arterial blood gas analysis showed PCO_2 of 46.1 mmHg, PO_2 of 62.2 mmHg, and SaO_2 of 93.4%. Echocardiography revealed marked enlargement of both atria and the right ventricle. The peak tricuspid regurgitation velocity was 4.1 m/s, corresponding to an estimated systolic pulmonary artery systolic pressure (PASP) of 83 mmHg, consistent with pulmonary hypertension (Figure 2). Contrast echocardiography was performed via injection of agitated saline through the right median cubital vein. Sequential opacification of the right atrium and right ventricle was observed, followed by the appearance of approximately 20 to 30 microbubbles in the left heart chambers at the seventh cardiac cycle under both resting conditions and after the Valsalva maneuver, indicating an intrapulmonary shunt (Figure 3). Pulmonary computed tomography angiography (CTA) revealed tortuous and dilated veins in the posterior segment of the right upper lobe, with indistinct demarcation from the adjacent pulmonary artery, along with enlargement of the pulmonary trunk and the right lower lobe pulmonary artery (Figure 4). In addition, thoracic ultrasound demonstrated bilateral pleural effusions. These imaging findings were consistent with PH and PAVMs. Based on the Curaçao diagnostic criteria, the patient was clinically diagnosed with HHT, supported by the presence of recurrent epistaxis, telangiectasias on the tongue, and pulmonary arteriovenous fistulas (5).

Whole exome sequencing (WES) of peripheral blood samples identified a heterozygous nonsense variant in the *ENG* gene: c.229C>T, resulting in the substitution of glutamine at position 77 by a stop codon (*ENG*:p.Gln77Ter), which was confirmed by Sanger sequencing (Figure 5). The patient reported that his mother had experienced similar epistaxis symptoms, suggesting that the variant may have been inherited from her. However, genetic confirmation could not be obtained. Notably, the patient's younger son, who carried the same variant, remained clinically asymptomatic. This variant has been deposited in ClinVar (ID: 651893). According to the ACMG/AMP guidelines, this variant was classified as Likely Pathogenic (LP). The evidence codes applied are as follows: PVS1 (Very Strong): The variant introduces a premature stop codon in exon 2, leading to nonsense-mediated mRNA decay (NMD) and subsequent endoglin haploinsufficiency, which is a known loss-of-function mechanism for HHT1. PM2_Supporting (Supporting): Absent from gnomAD (<6 alleles/AF <0.00004), per HHT VCEP threshold (6, 7). Therefore, the combination of PVS1 and PM2_Supporting supports the Likely Pathogenic classification, consistent with the ClinVar record.

2.2 Treatment

The patient's CHA_2DS_2-VASc score was 3 (age ≥75 years, 2 points; heart failure, 1 point), indicating a high annual risk of stroke or systemic embolism and a clear indication for long-term oral anticoagulation. The HAS-BLED score was 2 (age >65 years, 1 point; history of recurrent epistaxis, 1 point), reflecting a moderate bleeding risk. However, current evidence indicates that an elevated HAS-BLED score does not constitute a contraindication to anticoagulation. Instead, it should prompt enhanced monitoring and correction of modifiable risk factors. For this patient with a CHA_2DS_2-VASc score of 3 and a clear indication for anticoagulation, the benefit of stroke prevention was considered to outweigh the bleeding risk. In accordance

Abbreviations

ENG, Endoglin; HHT, Hereditary Hemorrhagic telangiectasia; PAVMs, Pulmonary arteriovenous malformations; PH, Pulmonary hypertension; ALK1, Activin receptor-like kinase 1; TGF-β, Transforming growth factor-β; AVM, Arteriovenous malformations; AF, Atrial fibrillation; CLL, Chronic lymphocytic leukemia; CRP, C-reactive protein; WBC, White blood cell; PASP, Pulmonary artery systolic pressure; CTA, Computed tomography angiography; WES, Whole exome sequencing; ACMG, American College of Medical Genetics and Genomics; LP, Likely pathogenic; RA, Right atrium; RV, Right ventricle; LA, Left atrium; LV, Left ventricle; AA, Ascending aorta; MPA, Main pulmonary artery; RPA, Right pulmonary artery; LPA, Left pulmonary artery; MIP, Maximum intensity projection.

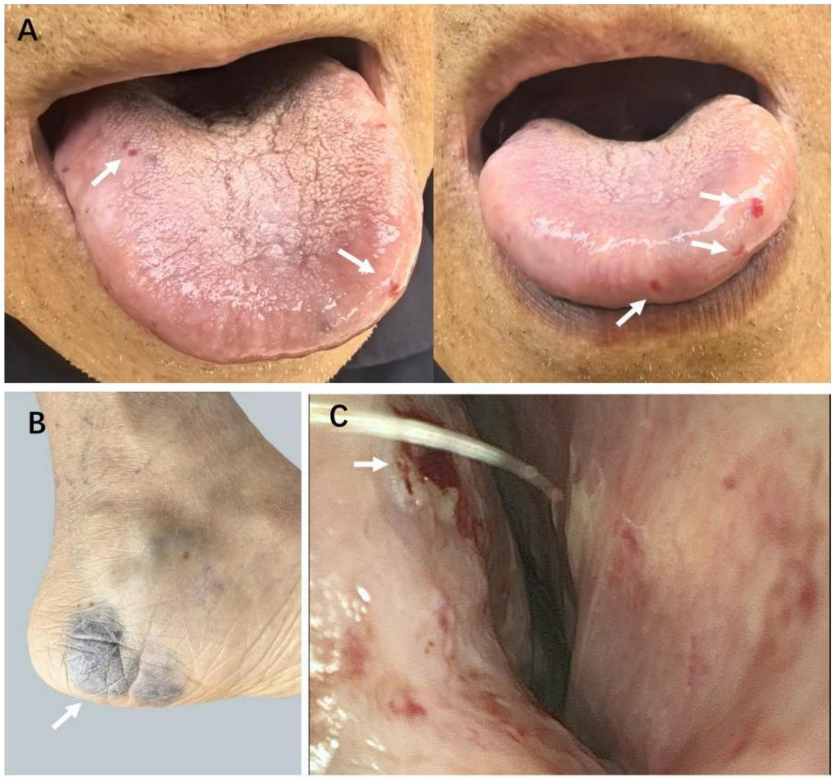

FIGURE 1
Multisite manifestations of HHT. **(A)** Lingual telangiectasias (white arrows); **(B)** Left plantar cavernous hemangioma (white arrow); **(C)** Nasoendoscopic view showing epistaxis (white arrow).

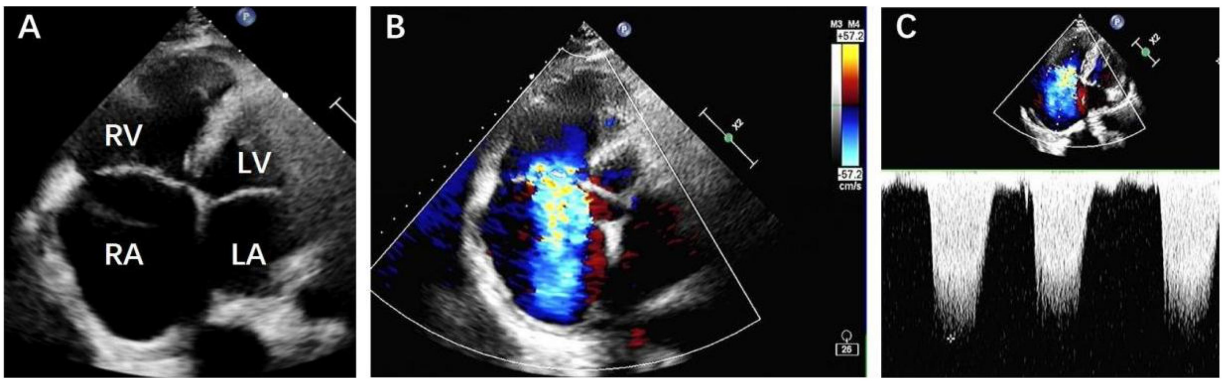

FIGURE 2
Transthoracic echocardiography. **(A)** Apical four-chamber view showing a dilated right ventricle (RV) and right atrium (RA); **(B)** Color Doppler imaging demonstrating severe tricuspid regurgitation; **(C)** Tricuspid regurgitation velocity and pressure gradient.

with guideline recommendations, the dose of dabigatran etexilate was reduced from 150 mg bid to 110 mgbid (8).

According to the Second International Guidelines for the Diagnosis and Management of HHT, embolization is recommended for PAVMs with a feeding artery diameter ≥3 mm to prevent paradoxical embolic stroke and brain abscess. CTA revealed that the feeding artery diameter of the right upper lobe PAVMs was 7 mm. Therefore, the patient met the guideline criteria for interventional treatment. The patient was fully informed of these guideline recommendations and the potential risks of declining intervention. However, the patient refused further interventional treatment. Given the surgical risks associated with advanced age, long-term anticoagulation, recurrent epistaxis, and multiple comorbidities (atrial fibrillation, chronic lymphocytic leukemia, and heart failure), the patient's informed decision was respected. Consequently, no further interventional treatment was performed, and a conservative management strategy was adopted. The treatment regimen

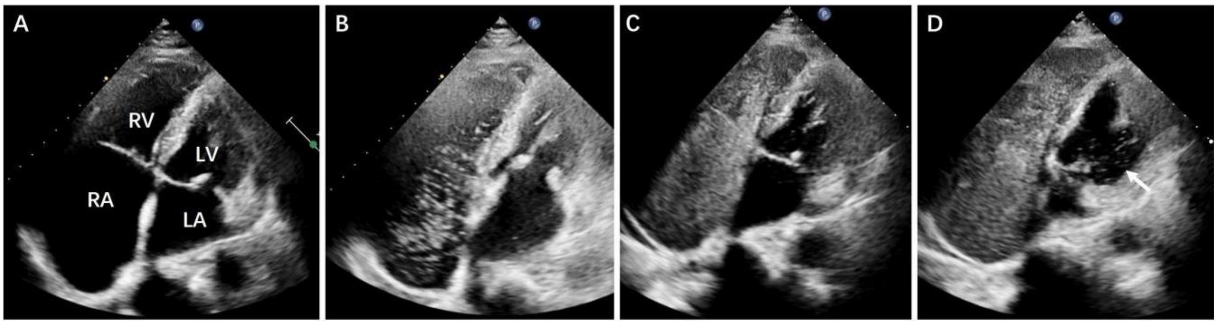

FIGURE 3
Positive agitated saline contrast echocardiography. **(A)** Apical four-chamber view; **(B)**After injection of agitated saline via the right antecubital vein, the right heart chambers (RA, RV) opacify densely with bubble echoes; **(C)** No microbubbles were observed in the left atrium (LA) and left ventricle (LV) in the early phase after injection; **(D)** At the seventh cardiac cycle, numerous microbubbles were observed in the LA and LV. Similar findings were observed both at rest and after the Valsalva maneuver. White arrows: microbubbles.

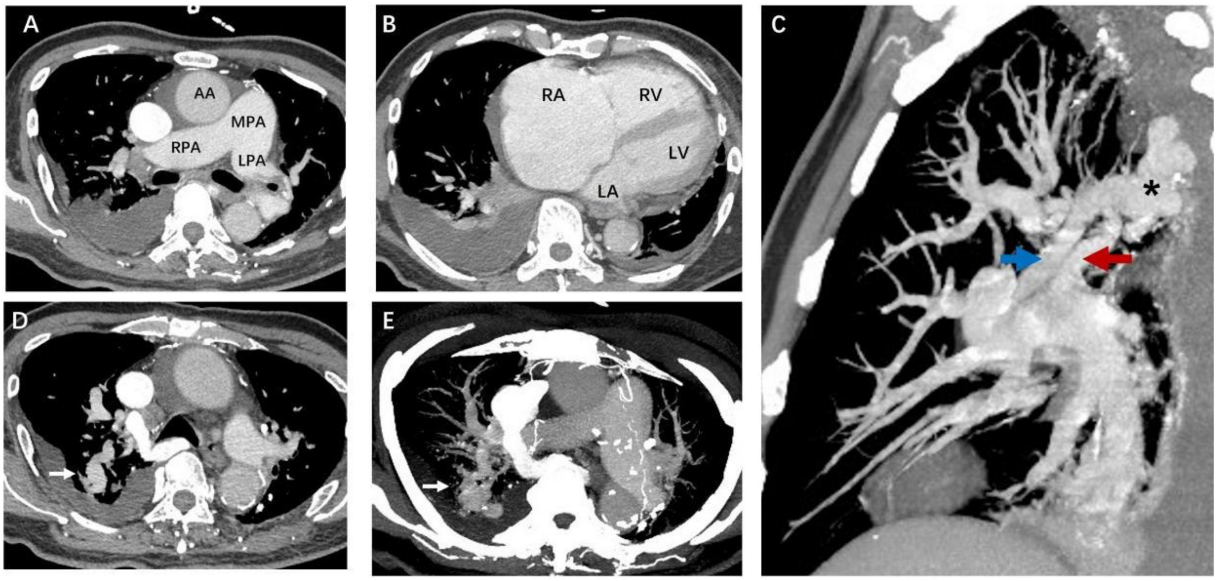

FIGURE 4
Computed tomography angiography (CTA) images. **(A)** Axial view at the level of the pulmonary artery bifurcation showing the ascending aorta (AA), main pulmonary artery (MPA), right pulmonary artery (RPA), and left pulmonary artery (LPA). **(B)** Axial four-chamber view of the heart demonstrating the RA, RV, LA and LV. **(C)** Coronal maximum intensity projection (MIP) reconstruction of the pulmonary vasculature showing the PAVMs in the right upper lobe. The blue arrow indicates the draining pulmonary vein, the red arrow points to the feeding pulmonary artery, and the asterisk (*) marks the arteriovenous convergence malformation. **(D)** Axial view showing a PAVMs in the right upper lobe (white arrow). **(E)** Axial view demonstrating the PAVMs (white arrow).

included moderate-flow oxygen therapy, oral diuretics (spironolactone 20 mg qd and torsemide 5 mg qd), closed chest tube drainage, and nutritional support. After implementation of this regimen, the patient's dyspnea improved significantly.

2.3 Follow-up

Follow-up nursing events are shown in Table 1. The patient was prescribed maintenance diuretic therapy with spironolactone 20 mg qd and torasemide 5 mg qd. At the 5-day follow-up visit, echocardiography revealed a reduction in tricuspid regurgitation velocity to 2.4–3.8 m/s, with an estimated PASP ranging from 28 to 62 mmHg, representing a marked improvement from admission. At the 4-month follow-up, the patient was able to ambulate without supplemental oxygen, maintaining an SpO_2 above 90% in room air, with a significantly improved quality of life.

3 Discussion

We report a case of a 90-year-old male patient with HHT1, notable for recurrent PAVMs and severe PH. Genetic testing revealed a classic heterozygous nonsense variant in the ENG gene, c.229C>T (p.Gln77Ter).

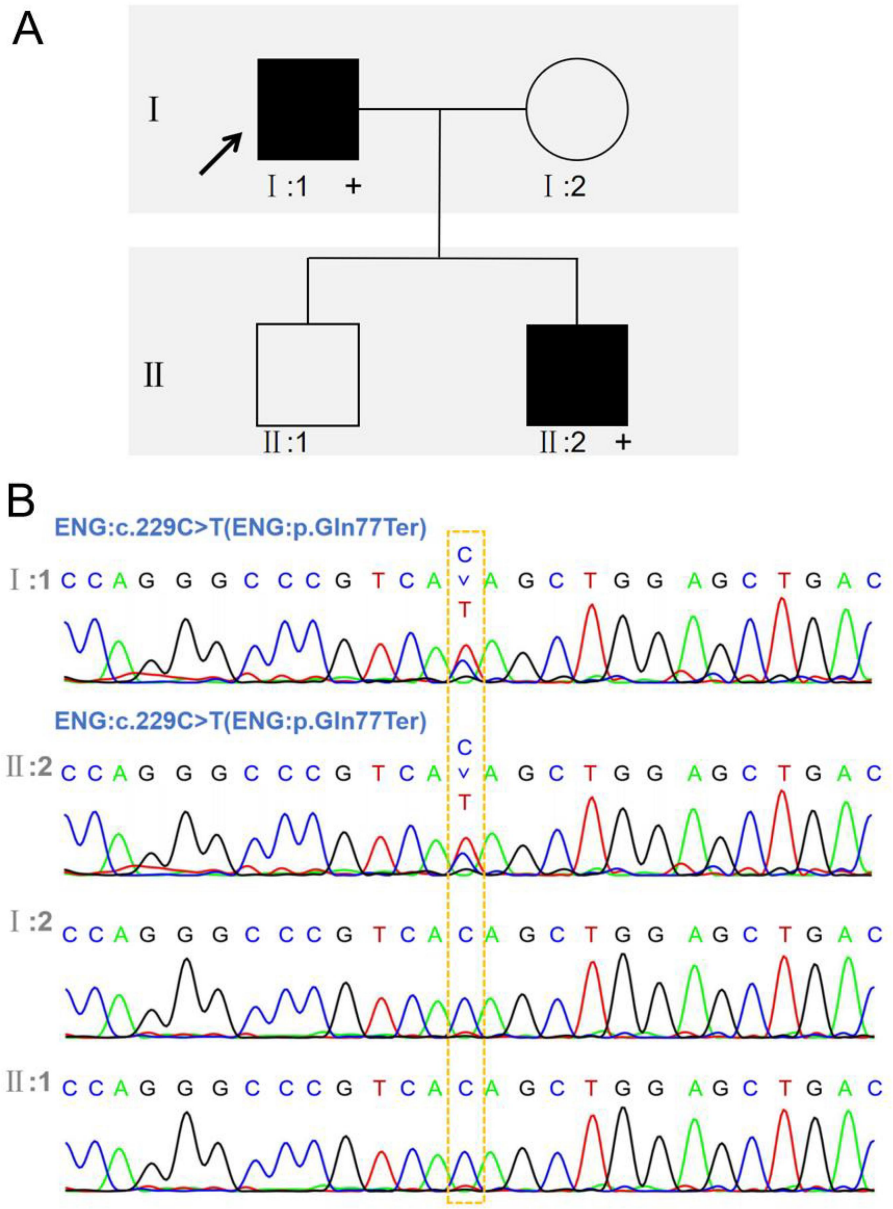

FIGURE 5
Pedigree chart of the proband and sanger sequencing results. **(A)** Pedigree chart. **(B)** Sanger sequencing results Arrow: proband; Black shading: individuals with ENG variant.

As demonstrated in the Case Presentation, the patient presented with severe PH and a recurrent right upper lobe PAVM, complicated by long-standing atrial fibrillation and bi-atrial enlargement. The rapid reduction in estimated PASP after diuretic therapy strongly suggests a significant post-capillary (WHO Group 2) component, meaning PAH-specific therapies were appropriately avoided. Based on the Curaçao diagnostic criteria, a clinical diagnosis of HHT was established. Genetic screening by WES identified a heterozygous nonsense variant in the ENG gene, c.229C>T (p.Gln77Ter), which was confirmed by Sanger sequencing. According to the ACMG/AMP guidelines, this ENG variant was classified as LP, supported by PVS1 and PM2 suporting evidence. Notably, although the proband's son (II:2) carries the same ENG variant, he remains self-reported asymptomatic and has not yet undergone imaging evaluation. This phenomenon may reflect age-dependent penetrance and variable expressivity, and it underscores the need for long-term monitoring of mutation carriers during the asymptomatic period. The ENG gene encodes endoglin, a TGF-β co-receptor that maintains endothelial quiescence by balancing ALK5/Smad2/3 and ALK1/Smad1/5/8 signaling (9, 10).The c.229C>T (p.Gln77Ter) variant introduces a premature stop codon, likely triggering nonsense-mediated mRNA decay and endoglin haploinsufficiency. This disrupts signaling balance, promoting excessive endothelial proliferation and abnormal vascular dilation —the core pathogenesis of HHT1 (11–14). Similar genotype-phenotype associations have been reported in other ENG-related HHT cases (15, 16).

Previous reports of ENG-related recurrent PAVMs have mainly involved young or middle-aged patients. In striking contrast, our patient represents an exceptionally rare phenotype: a 90-year-old

TABLE 1 Timeline of nursing event-related data.

Time Point	PASP (mmHg)	SpO_2 (%)	Interventions/Clinical events
1956	/	/	Surgical resection of left lower lobe pulmonary arteriovenous fistula
2000	/	/	Interventional embolization of left upper lobe pulmonary arteriovenous fistula
Admission	83	80	Initiated on moderate-flow oxygen therapy, oral diuretics (spironolactone 20 mg qd and torasemide 5 mg qd), closed chest drainage, and nutritional support
Follow-up visit 1 (Day 5)	28–62	93	Continued on the same diuretic regimen
Follow-up visit 2 (Month 4)	/	92	Continued on the same diuretic regimen

individual with recurrent PAVMs over a 70-year clinical course. He underwent surgical resection in 1956 and embolization in 2000, and in 2026 a new, clinically significant PAVM with a 7 mm feeding artery was identified. The intervals between interventions were 44 and 26 years, strongly suggesting that ENG haploinsufficiency confers a lifelong, persistent susceptibility to new vascular malformations that cannot be eliminated by localized treatment and that reflects an underlying endothelial risk. This rare presentation and prolonged survival have important implications for the long-term management of elderly patients with HHT. Current international guidelines recommend embolization for patients with PAVMs and a feeding artery diameter ≥3 mm to prevent paradoxical embolic stroke and brain abscess (5). However, in very elderly patients with multiple comorbidities, this anatomical curative strategy must be carefully weighed against procedural risk and bleeding tendency. In the present case, the patient had been receiving long-term dabigatran for atrial fibrillation and had recurrent epistaxis, both of which substantially increased the perioperative bleeding risk. Consequently, the patient declined further intervention. The success of our conservative approach, reflected in symptom relief (oxygen supplementation and diuretics) and a stable functional status at the 4-month follow-up, suggests a paradigm shift in the management of elderly patients with HHT. For a 90-year-old patient, this approach indicates that the focus should shift from aggressive, non-selective anatomical intervention toward individualized, symptom-guided surveillance strategies. Such an approach prioritizes shared decision-making and respect for patient autonomy, balancing the theoretical risk of paradoxical embolism against the immediate, tangible risks of procedural complications. This case provides valuable clinical evidence that conservative, patient-centered care is a feasible and safe alternative for very elderly patients with HHT and recurrent PAVMs. It further emphasizes the need for sustained vigilance even in elderly patients with a history of PAVM treatment. Moreover, although the c.229C>T (p.Gln77Ter) mutation has been previously recorded in ClinVar, its association with this exceptionally long-term recurrence phenotype provides strong evidence linking severe Endoglin truncation to persistent vascular malformation recurrence.

4 Conclusion

This report describes a case of a 90-year-old patient with HHT1 carrying the ENG c.229C>T variant, who exhibited an exceptionally rare 70-year pattern of PAVMs recurrence. The successful use of a conservative management strategy in this fragile, anticoagulated nonagenarian highlights the importance of integrating guideline recommendations with patient autonomy. In very elderly patients, the management of HHT-related PAVMs should shift toward individualized, symptom-guided surveillance. This case also underscores the necessity of lifelong monitoring for PAVMs recurrence in individuals carrying ENG nonsense mutations.

Data availability statement

The original contributions presented in the study are included in the article/Supplementary Material, further inquiries can be directed to the corresponding author/s.

Ethics statement

The studies involving humans were approved by Ethics Committee of Chinese People's Liberation Army Rocket Force Characteristic Medical Center. The studies were conducted in accordance with the local legislation and institutional requirements. The participants provided their written informed consent to participate in this study. Written informed consent was obtained from the individual(s) for the publication of any potentially identifiable images or data included in this article.

Author contributions

XL: Software, Visualization, Writing – original draft. CL: Software, Visualization, Writing – original draft. YW: Formal analysis, Resources, Writing – original draft. DW: Software, Writing – original draft. LZ: Validation, Writing – original draft. ZZ: Conceptualization, Methodology, Project administration, Resources, Supervision, Writing – review & editing.

Funding

The author(s) declared that financial support was not received for this work and/or its publication.

Acknowledgments

We would like to express our sincere gratitude to all the participants in this study and those who have contributed to the global medical cause. Additionally, we are deeply appreciative of

the anonymous reviewers for their meticulous reading of our work and the valuable comments they provided.

Conflict of interest

The author(s) declared that this work was conducted in the absence of any commercial or financial relationships that could be construed as a potential conflict of interest.

Generative AI statement

The author(s) declared that generative AI was not used in the creation of this manuscript.

Any alternative text (alt text) provided alongside figures in this article has been generated by Frontiers with the support of artificial intelligence and reasonable efforts have been made to ensure accuracy, including review by the authors wherever possible. If you identify any issues, please contact us.

Publisher's note

All claims expressed in this article are solely those of the authors and do not necessarily represent those of their affiliated organizations, or those of the publisher, the editors and the reviewers. Any product that may be evaluated in this article, or claim that may be made by its manufacturer, is not guaranteed or endorsed by the publisher.

References

1. Parrot A, Barral M, Amiot X, Bachmeyer C, Wagner I, Eyries M, et al. La maladie de rendu-osler (télangiectasie hémorragique héréditaire). *Rev Mal Respir*. (2023) 40(5):391–405. doi: 10.1016/j.rmr.2023.02.007

2. Circo S, Gossage JR. Pulmonary vascular complications of hereditary haemorrhagic telangiectasia. *Curr Opin Pulm Med*. (2014) 20(5):421–8. doi: 10.1097/MCP.0000000000000076

3. Sabbà C, Pasculli G, Lenato Gm, Suppressa P, Lastella P, Memeo M, et al. Hereditary hemorrhagic telangiectasia: clinical features in ENG and ALK1 mutation carriers. *J Thromb Haemost*. (2007) 5(6):1149–57. doi: 10.1111/j.1538-7836.2007.02531.x

4. Karlsson T, Cherif H. Mutations in the ENG, ACVRL1, and SMAD4 genes and clinical manifestations of hereditary haemorrhagic telangiectasia: experience from the center for osler's disease, Uppsala University Hospital. *Ups J Med Sci*. (2018) 123(3):153–7. doi: 10.1080/03009734.2018.1483452

5. Faughnan ME, Mager JJ, Hetts SW, Palda VA, Lang-Robertson K, Buscarini E, et al. Second international guidelines for the diagnosis and management of hereditary hemorrhagic telangiectasia. *Ann Intern Med*. (2020) 173(12):989–1001. doi: 10.7326/M20-1443

6. Richards S, Aziz N, Bale S, Bick D, Das S, Gastier-Foster J, et al. Standards and guidelines for the interpretation of sequence variants: a joint consensus recommendation of the American college of medical genetics and genomics and the association for molecular pathology. *Genet Med*. (2015) 17(5):405–24. doi: 10.1038/gim.2015.30

7. DeMille D, McDonald J, Bernabeu C, Racher H, Olivieri C, Cantarini C, et al. Specifications of the ACMG/AMP variant curation guidelines for hereditary hemorrhagic telangiectasia genes-ENG and ACVRL1. *Hum Mutat*. (2024) 2024:3043736–13. doi: 10.1155/2024/3043736

8. Lip GYH, Banerjee A, Boriani G, Chiang C, Fargo R, Freedman B, et al. Antithrombotic therapy for atrial fibrillation: cHEST guideline and expert panel report. *CHEST*. (2018) 154(5):1121–201. doi: 10.1016/j.chest.2018.07.040

9. Oh SP, Seki T, Goss KA, Imamura T, Yi Y, Donahoe PK, et al. Activin receptor-like kinase 1 modulates transforming growth factor-beta 1 signaling in the regulation of angiogenesis. *Proc Natl Acad Sci U S A*. (2000) 97(6):2626–31. doi: 10.1073/pnas.97.6.2626

10. Lebrin F, Deckers M, Bertolino P, Tendijke P. TGF-beta receptor function in the endothelium. *Cardiovasc Res*. (2005) 65(3):599–608. doi: 10.1016/j.cardiores.2004.10.036

11. Bergsma AJ, Kroos M, Hoogeveen-Westerveld M, Halley D, Van Der Ploeg AT, Pijnappel WW. Identification and characterization of aberrant GAA pre-mRNA splicing in pompe disease using a generic approach. *Hum Mutat*. (2015) 36(1):57–68. doi: 10.1002/humu.22705

12. Tual-Chalot S, Oh SP, Arthur HM. Mouse models of hereditary hemorrhagic telangiectasia: recent advances and future challenges. *Front Genet*. (2015) 6:25. doi: 10.3389/fgene.2015.00025

13. Lebrin F, Goumans MJ, Jonker L, Carvalho RLC, Valdimarsdottir G, Thorikay M, et al. Endoglin promotes endothelial cell proliferation and TGF-beta/ALK1 signal transduction. *Embo j*. (2004) 23(20):4018–28. doi: 10.1038/sj.emboj.7600386

14. Torsney E, Charlton R, Diamond AG, Burn J, Soames JV, Arthur HM. Mouse model for hereditary hemorrhagic telangiectasia has a generalized vascular abnormality. *Circulation*. (2003) 107(12):1653–7. doi: 10.1161/01.CIR.0000058170.92267.00

15. Liu D, Xu F, Gao Q, Zhai Z. Case report: pulmonary arterial hypertension in ENG-related hereditary hemorrhagic telangiectasia. *Front Cardiovasc Med*. (2022) 9:1020762. doi: 10.3389/fcvm.2022.1020762

16. Schutyser W, Budts W, Verhamme P. Percutaneous embolization of pulmonary arteriovenous malformations in adult patient with rendu-osler-weber: a case report. *Eur Heart J Case Rep*. (2023) 7(11):ytad533. doi: 10.1093/ehjcr/ytad533