Received: 11 June 2026 | Revised: 6 October 2026 | Accepted: 26 October 2026

DOI: 10.1002/pcn5.70442

PCN Reports
Psychiatry and Clinical Neurosciences
Open Access

CASE REPORT

Massive ascites with preserved serum albumin in adult anorexia nervosa: Impact on eating behavior and weight-based treatment assessment

Masaya Mashimoto MD[1] | Toma Kora MD[1] | Yurie Sakamoto MD[1] | Atsutaka Masuda MD, PhD[2] | Hiromi Chiba MD, PhD[1] | Motohiro Ozone MD, PhD[1]

[1]Department of Neuropsychiatry, Kurume University School of Medicine, Kurume-city, Fukuoka, Japan

[2]Division of Gastroenterology, Department of Internal Medicine, Kurume University School of Medicine, Kurume-city, Fukuoka, Japan

Correspondence
Masaya Mashimoto MD, Department of Neuropsychiatry, Kurume University School of Medicine, 67 Asahimachi, Kurume-city, Fukuoka 830-0011, Japan.
Email: mashimoto_masaya@med.kurume-u.ac.jp

Funding information
None

Abstract

Background: Ascites is a rare complication of anorexia nervosa (AN) and is typically associated with hypoalbuminemia. Its influence on eating behavior and on the evaluation of treatment response remains poorly characterized.

Case Presentation: A 30-year-old woman with AN presented with massive ascites despite a preserved serum albumin level, a presentation not previously reported in adults. Imaging, ascitic fluid analysis, and serological testing excluded cirrhosis, malignancy, infection, and autoimmune serositis. The fluid showed a high serum-ascites albumin gradient (SAAG, 2.1 g/dL) with preserved protein (3.1 g/dL) and normal lactate dehydrogenase. Although the SAAG was high, there was no evidence of portal hypertension, and the mechanism remains undetermined. Serum and ascitic carbohydrate antigen 125 were elevated and normalized as the ascites resolved. Ascites-related symptoms, including early satiety, abdominal pain, and nausea, further reduced oral intake, while fluctuations in body fluid obscured the weight gain expected from nutritional rehabilitation, making weight-based assessment of treatment efficacy difficult. The ascites resolved with nutritional therapy and diuretics.

Conclusion: Ascites can develop in adult patients with AN even when serum albumin is preserved. Beyond the psychopathology of AN, somatic symptoms caused by ascites may influence eating behavior and contribute to weight loss. Because fluctuations in body fluid can confound weight-based assessment of treatment response, comprehensive clinical evaluation incorporating abdominal imaging, rather than body weight alone, is warranted.

KEYWORDS

anorexia nervosa, ascites, malnutrition, physical complications, serum-ascites albumin gradient

This is an open access article under the terms of the Creative Commons Attribution License, which permits use, distribution and reproduction in any medium, provided the original work is properly cited.
© 2026 The author(s). *Psychiatry and Clinical Neurosciences Reports* published by John Wiley & Sons Australia, Ltd on behalf of Japanese Society of Psychiatry and Neurology.

BACKGROUND

Anorexia nervosa (AN) is a psychiatric disorder characterized by diverse medical complications arising from severe malnutrition.[1] Whereas cardiovascular, endocrine, bone metabolic, and gastrointestinal complications are well recognized, ascites is rare, and its clinical significance in psychiatric practice remains insufficiently examined.

Ascites and edema in AN have been reported in various conditions, including kwashiorkor-type pathology with hypoalbuminemia,[2] refeeding edema,[3] noncirrhotic portal hypertension,[4–6] acute liver injury,[7] and pancreatitis,[8] most of which are accompanied by hypoalbuminemia. Although ascites with a preserved serum albumin level has been reported in an 11-year-old patient,[9] we identified no adult case in which ascites developed despite preserved serum albumin.

Patients with AN frequently report gastrointestinal symptoms such as anorexia, postprandial fullness, constipation, and nausea, which often intensify dietary restriction.[10,11] Ascites may exacerbate these symptoms, inducing early satiety and postprandial discomfort through impaired gastric accommodation and increased intra-abdominal pressure,[12,13] potentially accelerating caloric reduction and weight loss. However, how ascites affects eating behavior and the assessment of treatment response in AN has received limited attention.

Herein, we report an adult patient with AN who developed massive ascites despite preserved serum albumin, in whom the ascites exacerbated gastrointestinal symptoms and intensified dietary restriction, while fluctuations in body fluid confounded weight-based assessment of treatment response.

CASE PRESENTATION

A 30-year-old Japanese woman with progressive malnutrition was admitted to our Department of Psychiatry in August of year X. Her maximum body weight during high school was 44.0 kg. She began losing weight in her early twenties and was diagnosed with an eating disorder at another clinic in September of year X-2, weighing 38.4 kg. Her history included Sjogren's syndrome (positive anti-SS-A and anti-U1-RNP, negative anti-SS-B), without features suggestive of systemic lupus erythematosus or mixed connective tissue disease.

In July of year X-1, she developed abdominal distension, lower abdominal pain, and postprandial nausea, and ultrasonography revealed ascites. The subsequent workup comprised blood, ascitic fluid, and imaging evaluations. Hepatic, renal, and thyroid function were normal, and serum albumin was preserved at 4.3 g/dL. Inflammatory markers were not elevated. Carbohydrate antigen 125 (CA125) was elevated in both serum (205 U/mL; reference, <35 U/mL) and ascitic fluid, whereas other tumor markers were normal (Table 1). Contrast-enhanced CT and MRI confirmed ascites but showed no cirrhosis, portal hypertension, malignancy, or splenomegaly (Figure 1). Paracentesis yielded pale-yellow, clear fluid with a high serum-ascites albumin gradient (SAAG), preserved protein, and normal lactate dehydrogenase. Cytological and microbiological examinations were negative, and no definitive cause was identified (Table 1).

The patient had exhibited an intense fear of weight gain, persistent dietary restriction, and body image disturbance before the onset of ascites. Thereafter, early satiety, lower abdominal pain, and nausea attributed to the ascites further exacerbated her restriction and led to progressive weight loss. The ascites did not resolve spontaneously, and serial imaging showed gradually increasing fluid. In June of year X, she was admitted to Endocrinology and Metabolism for evaluation of a possible endocrine disorder. Hormone testing revealed low luteinizing hormone (<0.3 mIU/mL), low follicle-stimulating hormone (2.2 mIU/mL), and markedly reduced insulin-like growth factor 1 (29 ng/mL), with normal thyroid and adrenal function; hypothyroidism and adrenal insufficiency were excluded. These findings were consistent with functional hypothalamic suppression and nutritional growth hormone resistance secondary to AN rather than organic pituitary disease. Ultrasonography revealed large-volume ascites in both the upper and lower abdomen (Figure 2). During the 2-week admission, her weight decreased from 35.8 to 33.1 kg. In August of year X, she was admitted to our Department of Psychiatry for treatment of AN.

On admission, height was 161.7 cm and weight 32.6 kg (BMI 12.4 kg/m^2). Hypothermia, hypotension, bradycardia, and lower-extremity edema were present, whereas serum albumin was normal (4.2 g/dL). She was amenorrheic, markedly underweight, and exhibited severe caloric restriction, intense fear of weight gain, and body image disturbance. She denied vomiting and reported laxative use within the recommended dose. Per DSM-5 criteria,[14] she was diagnosed with AN, restricting type, of extreme severity (BMI < 15 kg/m^2).

She attributed her decreased intake to work-related stress beginning around year X-1 and reported that, after the onset of ascites, early satiety, abdominal pain, nausea, and the perception that abdominal distension represented weight gain further reduced her intake. Nutritional therapy began at 1100 kcal/day with monitoring for refeeding syndrome, but initial intake was approximately half the prescribed amount. Cognitive reframing was provided to clarify that the distension reflected ascites rather than body fat, with psychoeducation on adequate oral intake. From hospital Day 5, she consumed nearly the full amount. The edema subsided, and although her weight initially fell to 29.3 kg on Day 12, it thereafter trended upward. Because abdominal distension persisted, caloric intake was advanced cautiously.

Abdominal CT on Day 48 still showed large-volume ascites (Figure 3). Echocardiography excluded heart failure, an interferon-gamma release assay was negative for tuberculosis, and endoscopy showed no esophageal varices. On Day 49, oral spironolactone was started at 25 mg/day and titrated to 100 mg/day, under strict inpatient supervision given the risk of diuretic misuse. Owing to insufficient response, furosemide (20–60 mg/day) was substituted on Day 57, but its effect was minimal, and hypokalemia on Day 90 prompted a return to spironolactone. Her weight increased to 34.0 kg on Day 96, then fell to 31.5 kg on Day 110, while serial imaging demonstrated progressive reduction of ascites; CT on day 132 confirmed marked improvement (Figure 4). The weight loss was therefore attributed primarily to fluid shifts rather than reduced body mass. CA125 normalized to 25.6 U/mL. Although fear of eating persisted, caloric intake rose to a maximum of 3000 kcal/day, and weight recovered gradually. On Day 179, ultrasonography showed ascites reduced to a

TABLE 1 Blood and ascitic fluid findings during the initial evaluation of ascites (July–October, year X − 1).

Category	Parameter	Reference range	Blood	Ascitic fluid	Interpretation
Complete blood count	White blood cells ($\times 10^3/\mu L$)	3.3–8.6	2.6	—	Mild leukopenia
	Hemoglobin (g/dL)	11.6–14.8	11.3	—	Mild anemia
	Platelets ($\times 10^4/\mu L$)	15.8–34.8	19.2	—	Normal
Biochemistry	AST (U/L)	13–30	32	—	Slightly elevated
	ALT (U/L)	7–30	26	—	Normal
	γ-GTP (U/L)	9–32	16	—	Normal
	ALP (U/L)	38–113	40	—	Normal
	Total bilirubin (mg/dL)	0.4–1.2	1.0	—	Normal
	Total protein (g/dL)	6.6–8.1	6.6	—	Lower limit of normal
	Albumin (g/dL)	4.1–5.1	4.3	—	Preserved serum albumin level
	BUN (mg/dL)	8–20	10	—	Normal
	Creatinine (mg/dL)	0.46–0.79	0.69	—	Normal
	Sodium (mEq/L)	138–145	136	—	Mild hyponatremia
	Potassium (mEq/L)	3.6–4.8	3.8	—	Normal
	Amylase (U/L)	44–132	132	—	Upper limit of normal
	LDH (U/L)	124–222	160	—	Normal
	C-reactive protein (mg/dL)	≤0.14	<0.04	—	Not elevated
Endocrine	Free T4 (ng/dL)	0.93–1.70	0.95	—	Lower limit of normal
	TSH (mIU/L)	0.61–4.23	2.43	—	Normal
Autoimmunity	C3 (mg/dL)	73–138	70	—	Mildly decreased
	C4 (mg/dL)	11–31	23	—	Normal
	IgG (mg/dL)	861–1747	924	—	Normal
	IgA (mg/dL)	93–393	85	—	Mildly decreased
	IgM (mg/dL)	50–269	59	—	Normal
	IgG4 (mg/dL)	11.0–121.0	7.4	—	Not elevated; IgG4-related disease unlikely
	Anti-dsDNA antibody	≤12.0	<1.2	—	Negative
	Anti-U1-RNP antibody	<1.0	46.1	—	Positive
	Anti-Sm antibody	—	Negative	—	Negative
	MPO-ANCA	<3.5	<1.0	—	Negative
	PR3-ANCA	<3.5	<1.0	—	Negative
	Soluble IL-2 receptor (U/mL)	157–474	191	—	Normal
Tumor markers	CA125 (U/mL)	≤35.0	205	356.0	Elevated in both
	CEA (ng/mL)	≤5.0	0.6	<0.3	Normal; malignancy unlikely
	CA19-9 (U/mL)	≤37.0	8.2	2.8	Normal; malignancy unlikely
	AFP (ng/mL)	—	—	1.3	Low; malignancy unlikely
	CA15-3 (U/mL)	—	—	<1.5	Low; malignancy unlikely
Ascitic fluid chemistry	Total protein (g/dL)	—	—	3.1	High protein concentration
	Albumin (g/dL)	—	—	2.2	Used for SAAG calculation
	SAAG (g/dL)	—	—	2.1	High (≥1.1 g/dL)
	LDH (U/L)	—	—	64	Not elevated

(Continues)

TABLE 1 (Continued)

Category	Parameter	Reference range	Blood	Ascitic fluid	Interpretation
	Amylase (U/L)	—	—	72	Pancreatic ascites unlikely
	Lipase (U/L)	—	—	36	Pancreatic ascites unlikely
	ADA (U/L)	—	—	3.4	Low (<40 U/L); tuberculous peritonitis unlikely
Ascitic fluid cell analysis	Total cell count (/μL)	—	—	75	Low cellularity
	Mononuclear cells (/μL)	—	—	72	Mononuclear predominance
	Large cells (/μL)	—	—	3	No atypia
Cytology and culture	Cytology	—	—	Negative	No malignant cells
	Bacterial culture	—	—	Negative	No bacterial growth
	Mycobacterial culture	—	—	Not performed	Low clinical suspicion based on low ADA

Abbreviations: ADA, adenosine deaminase; AFP, α-fetoprotein; ALP, alkaline phosphatase; ALT, alanine aminotransferase; ANCA, antineutrophil cytoplasmic antibody; AST, aspartate aminotransferase; BUN, blood urea nitrogen; CA, carbohydrate antigen; CEA, carcinoembryonic antigen; γ-GTP, γ-glutamyl transpeptidase; IgG4, immunoglobulin G4; LDH, lactate dehydrogenase; MPO, myeloperoxidase; PR3, proteinase 3; RNP, ribonucleoprotein; SAAG, serum-ascites albumin gradient; Sm, Smith; TSH, thyroid-stimulating hormone.

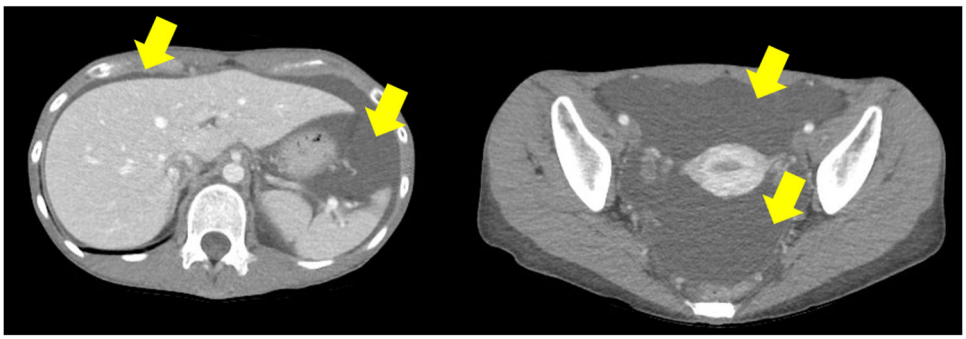

FIGURE 1 Contrast-enhanced abdominal computed tomography in July of year X−1, demonstrating ascites (arrows) without findings suggestive of cirrhosis, portal hypertension, malignancy, or splenomegaly.

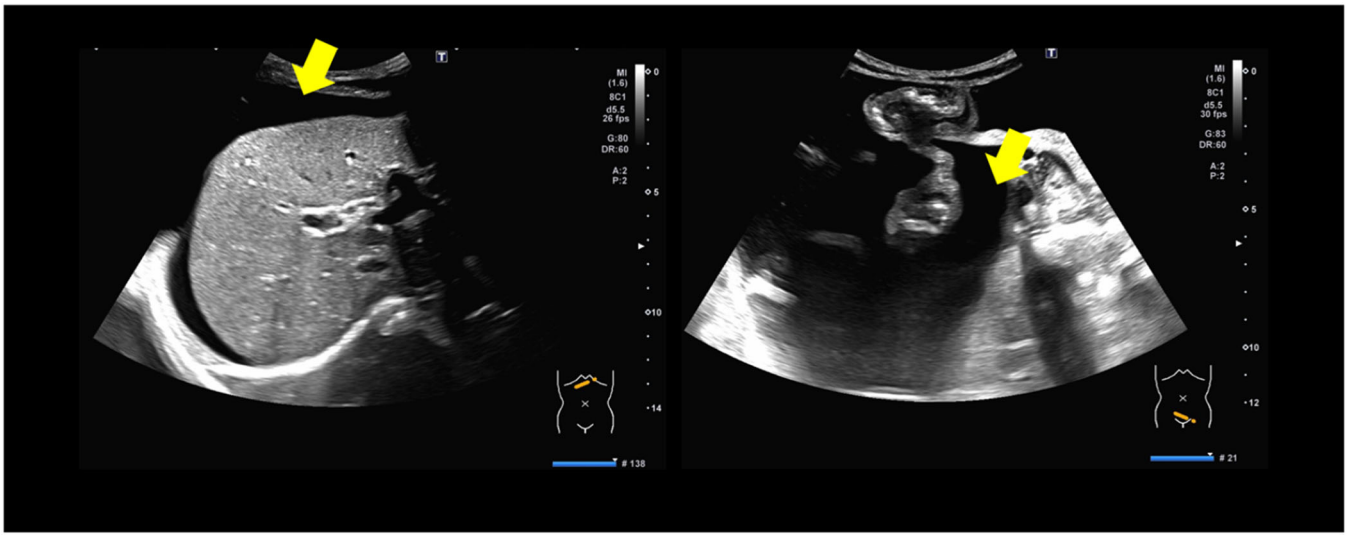

FIGURE 2 Abdominal ultrasonography demonstrating large volumes of ascites in the upper and lower abdomen (arrows).

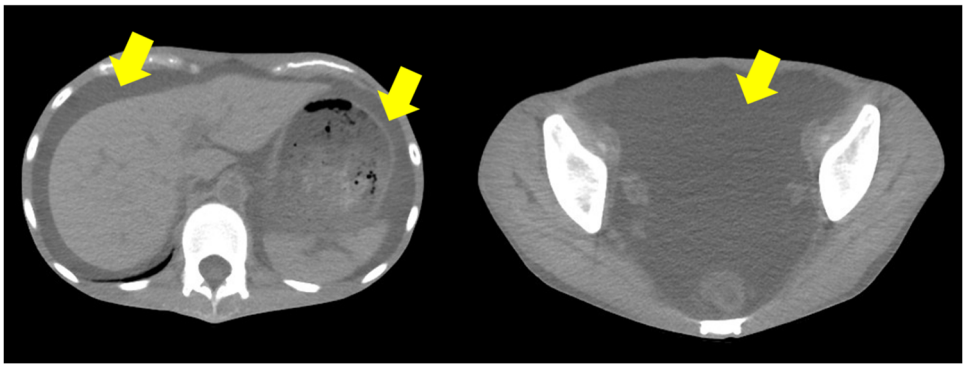

FIGURE 3 Abdominal computed tomography on hospital Day 48, demonstrating persistent large-volume ascites throughout the upper and lower abdomen, with a marked increase compared with Figure 1 (arrows). The findings are consistent with the ascites observed on ultrasonography (Figure 2).

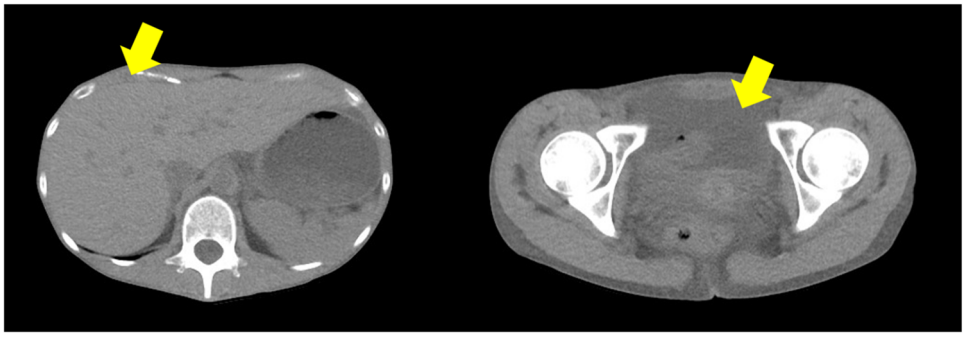

FIGURE 4 Abdominal computed tomography on hospital Day 132. Compared with Figure 3, the ascites showed marked improvement, with only trace fluid in the upper abdomen and a small amount in the lower abdomen (arrows).

physiological level, and spironolactone was discontinued. Mild re-accumulation followed but, without exacerbation of abdominal symptoms, was managed with observation. She was discharged on Day 211 at 36.0 kg (BMI 13.8 kg/m^2).

DISCUSSION

The present case represents a rare instance of ascites in an adult patient with AN in the absence of hypoalbuminemia. The ascites exacerbated dietary restriction and accelerated weight loss through early satiety and postprandial discomfort, while fluctuations in body fluid confounded the interpretation of body weight as a measure of therapeutic response. Treatment response in such patients should therefore be assessed through comprehensive clinical evaluation incorporating abdominal imaging, rather than by body weight alone.

Impact of ascites on eating behavior

Ascites may directly influence eating behavior in AN. Dietary restriction in this disorder arises from core psychopathology such as fear of weight gain and body image disturbance; in our patient, these were evident before the onset of ascites and persisted after its resolution. In addition, the impaired gastric accommodation and increased intra-abdominal pressure produced by ascites can induce early satiety and postprandial discomfort, further reducing caloric intake.[12,13] Thus, when ascites complicates AN, somatic factors may compound the underlying psychopathology and accelerate the decline in oral intake and weight loss.

Impact of ascites on treatment evaluation

Where fluid shifts occur, weight gain from nutritional intake and weight loss from mobilization of retained fluid may coexist, so the observed change in body weight reflects only the net difference. The retained fluid was not limited to ascites: peripheral edema was also present, so body weight reflected total body fluid. A change in weight does not map directly onto a change in ascitic volume; although correlated, ascites accounts for only part of any weight change.[15] These factors make body weight an unreliable measure of treatment response in AN complicated by ascites. When expected weight gain is not achieved, restrictive behaviors such as food avoidance or vomiting must be considered; here, vomiting could not be entirely excluded, as assessment relied on self-report and ultrasonographic

confirmation of residual gastric contents. Fluctuations in ascitic volume further confounded this differential, and distinguishing behavioral factors from fluid shifts proved difficult. Serial imaging offered partial support but, capturing only the ascitic component and providing only a semiquantitative estimate, did not fully resolve this uncertainty.

Pathogenesis of ascites in the present case

The serum albumin level was preserved, and imaging showed no cirrhosis, malignancy, heart failure, infection, or autoimmune serositis. Although the patient had Sjogren's syndrome with positive anti-U1-RNP antibody and a mildly reduced C3 level, she had no clinical or imaging features of active connective tissue disease and a normal C-reactive protein. The ascitic fluid showed low cellularity and negative cytology, arguing against active autoimmune serositis, and the ascites resolved without immunosuppression. The elevated serum and ascitic CA125 normalized in parallel with resolution of the ascites, consistent with a prior report of AN-associated ascites with reversible CA125 elevation without malignancy.[16] Preserved albumin argued against kwashiorkor-type pathology, and onset before refeeding made refeeding edema unlikely.

The ascitic fluid showed a high SAAG (2.1 g/dL) with preserved protein (3.1 g/dL) and normal lactate dehydrogenase. Although a high SAAG generally suggests portal hypertension, our patient showed no findings supporting it: the platelet count was normal, and neither splenomegaly nor esophageal varices were observed. Koga et al.[4,5] reported long-standing AN with portal hypertension, varices, and ascites in the context of self-induced vomiting and laxative misuse despite no overt cirrhosis; unlike those cases, our patient showed neither morphological evidence of portal hypertension nor hypoalbuminemia. Furthermore, the ascites resolved with nutritional rehabilitation and diuretics, a course difficult to explain by portal hypertension. Fan et al.[9] reported an 11-year-old girl with AN who developed massive ascites despite preserved serum albumin; laparoscopic biopsies revealed chronic inflammation and fibrosis in the small intestine and mesentery, and the authors attributed the ascites to chronic inflammation of the intestinal serosa, mesentery, and peritoneal surface of the liver. As in our patient, the ascitic fluid was of low cellularity, thrombocytopenia and splenomegaly were absent, and the ascites resolved with nutritional rehabilitation. Although that case was pediatric, these similarities suggest that a comparable malnutrition-related serosal process may have contributed to the ascites in our patient. However, because laparoscopy and peritoneal biopsy were not performed, the mechanism of ascites formation could not be determined, and accumulation of similar cases is warranted.

LIMITATIONS

Several limitations apply. First, generalizability is limited by the single-case design. Second, the mechanism of ascites formation was not directly investigated; laparoscopy with peritoneal biopsy, liver biopsy, and hepatic venous pressure gradient measurement were not performed because of their invasiveness. Therefore, although portal hypertension appeared unlikely, the contribution of a malnutrition-related serosal process, as suggested in a previous pediatric report,[9] remains speculative. Third, the relationships among ascitic volume, eating behavior, and body weight were assessed observationally, precluding a quantitative causal link. Despite these limitations, the case illustrates that ascites can affect both the clinical course and the assessment of treatment response in AN.

CONCLUSION

Ascites can develop in adult patients with AN even when serum albumin is preserved. It may influence eating behavior through somatic symptoms such as early satiety and postprandial discomfort and may confound weight-based treatment evaluation through fluctuations in body fluid. When ascites is identified in AN, comprehensive clinical assessment incorporating abdominal imaging, rather than reliance on body weight alone, is required. Further systematic study is needed to elucidate the pathogenesis and establish therapeutic strategies for AN complicated by ascites.

AUTHOR CONTRIBUTIONS

Masaya Mashimoto interviewed and treated the patient, performed the literature search, and wrote and revised the first draft of the manuscript. Toma Kora,Yurie Sakamoto, and Atsutaka Masuda interviewed and treated the patient and revised the manuscript. Hiromi Chiba and Motohiro Ozone wrote and revised parts of the manuscript. All authors contributed to the manuscript and approved the final version of the manuscript.

ACKNOWLEDGMENTS

The authors used Claude (Anthropic) solely for language editing and to improve the clarity of the English manuscript. The authors reviewed and verified all AI-generated content to ensure accuracy and integrity. The authors have funding to report.

CONFLICT OF INTEREST STATEMENT

The authors declare no conflict of interest.

DATA AVAILABILITY STATEMENT

Data sharing is not applicable to this article as no new datasets were generated or analyzed during this study.

ETHICS APPROVAL STATEMENT

This case report did not require ethics committee approval per our institutional policy. It was conducted in accordance with the principles of the Declaration of Helsinki.

PATIENT CONSENT STATEMENT

Written informed consent was obtained from the patient for the publication of this case report, including all clinical details and

accompanying images. A copy of the written consent is available for review by the Editor-in-Chief of this journal upon request.

CLINICAL TRIAL REGISTRATION

Not applicable as this is a case report.

REFERENCES

1. Trapani S, Rubino C. Medical complications of anorexia nervosa. Pediatrics. 2025;156(2):e2024070304.
2. Palm CVB, Frølich JS, Snogdal LS, Støving RK. Kwashiorkor: an unexpected complication to anorexia nervosa. BMJ Case Rep. 2016; 2016:bcr2016215638.
3. Rigaud D, Boulier A, Tallonneau I, Brindisi MC, Rozen R. Body fluid retention and body weight change in anorexia nervosa patients during refeeding. Clin Nutr. 2010;29:749–55.
4. Koga A, Toda K, Tatsushima K, Matsuubayashi S, Tamura N, Imamura M, et al. Portal hypertension in prolonged anorexia nervosa with laxative abuse: a case report of three patients. Int J Eating Disord. 2019;52:211–5.
5. Koga A, Murakami M, Kurihra Y, Ishida T, Hosokawa M, Tamura N, et al. Portal hypertension in prolonged anorexia nervosa with laxative abuse: a case report with liver and kidney biopsy data. Eat Weight Disord. 2021;26:733–8.
6. Takata K, Nagata T, Uchida Y, Kitaguchi T, Higashi T, Fukuda H, et al. Gastroesophageal varices and hyperplastic nodules of the liver in a patient with anorexia nervosa. Intern Med. 2021;60:3107–12.
7. Rautou P-E, Cazals-Hatem D, Moreau R, Francoz C, Feldmann G, Lebrec D, et al. Acute liver cell damage in patients with anorexia nervosa: a possible role of starvation-induced hepatocyte autophagy. Gastroenterology. 2008;135:840–8 840–8.
8. Isaacs P, Saunders AJ, Rosen BK, Sladen GE. Anorexia nervosa and pancreatic ascites. Postgrad Med J. 1986;62:1151–2.
9. Fan H-H, Lin I-C, Chen J-E, Lee W-H, Fang S-B. Anorexia nervosa manifesting as massive ascites, hypercholesterolemia, and sequential binge eating in an 11-year-old girl: a case report. Medicine. 2020; 99:e21739.
10. Cooper M, Collison AO, Collica SC, Pan I, Tamashiro KL, Redgrave GW, et al. Gastrointestinal symptomatology, diagnosis, and treatment history in patients with underweight avoidant/restrictive food intake disorder and anorexia nervosa: Impact on weight restoration in a meal-based behavioral treatment program. Int J Eat Disord. 2021;54:1055–62.
11. Salvioli B, Pellicciari A, Iero L, Di Pietro E, Moscano F, Gualandi S, et al. Audit of digestive complaints and psychopathological traits in patients with eating disorders: a prospective study. Dig Liver Dis. 2013;45:639–44.
12. Chapman B, Sinclair M, Gow PJ, Testro AG. Malnutrition in cirrhosis: more food for thought. World J Hepatol. 2020;12:883–96.
13. Aqel BA, Scolapio JS, Dickson RC, Burton DD, Bouras EP. Contribution of ascites to impaired gastric function and nutritional intake in patients with cirrhosis and ascites. Clin Gastroenterol Hepatol. 2005;3:1095–100.
14. American Psychiatric Association. Diagnostic and statistical manual of mental disorders (DSM-5 (R)). 5th ed. Arlington, TX: American Psychiatric Association Publishing; 2013.
15. Sakaida I, Okita K. Correlation between changes in bodyweight and changes in ascites volume in liver cirrhosis patients with hepatic edema in short-term diuretic therapy. Hepatol Res. 2014; 44:735–9.
16. Suwabe T, Taguchi M, Takeshita A, Ozawa Y. Marked ascites and serum carbohydrate antigen (CA) 125 elevation in a patient with anorexia nervosa. Int J Eat Disord. 2005;38:94–6.

How to cite this article: Mashimoto M, Kora T, Sakamoto Y, Masuda A, Chiba H, Ozone M. Massive ascites with preserved serum albumin in adult anorexia nervosa: impact on eating behavior and weight-based treatment assessment. Psychiatry Clin Neurosci Rep. 2026;5:e70442.
https://doi.org/10.1002/pcn5.70442