Journal of Surgical Case Reports, 2026, 2026(11), rjag1065
https://doi.org/10.1093/jscr/rjag1065
Published: 20 November 2026
Case Report

OXFORD

Death by emphysematous pancreatitis in a matter of hours: a case report

James A. Freeman-Greene*, Nicholas Low, Aswin Shanmugalingam, Jia Xi Julian Li

Department of Surgery, Blacktown Hospital, Blacktown Rd, Blacktown, NSW 2148, Australia

*Corresponding author. Department of Surgery, Blacktown Hospital, Blacktown Rd, Blacktown, NSW 2148, Australia. E-mail: james.freemangreene@health.nsw.gov.au

Abstract

We present a fatal case of severe acute emphysematous pancreatitis in an otherwise healthy 77-year-old male. The patient presented acutely with severe epigastric pain and vomiting. Initial computed tomography (CT) showed interstitial oedematous pancreatitis. Despite early intensive care admission, multidisciplinary review, and evidence-based management, the patient rapidly developed multiorgan failure. Repeat CT less than 24 h later demonstrated near-total pancreatic necrosis with extensive intrapancreatic gas and pneumoperitoneum. Emergency laparotomy revealed extensive necrotizing pancreatitis, pancreatic ascites, and a gangrenous gallbladder, requiring necrosectomy, and cholecystectomy. Despite maximal intensive care support, he died ∼48 h after presentation. This case highlights that, despite advances in critical care, imaging, and surgical technique, acute pancreatitis remains unpredictable and can take a fulminant course with rapid progression to multiorgan failure and death even in a first world healthcare setting.

Keywords **acute pancreatitis, emphysematous pancreatitis, necrotizing pancreatitis, pancreatic necrosis, multiorgan failure**

Introduction

Acute pancreatitis is a common indication for emergency surgical admissions. While most cases present as mild to moderate disease that follows a self-limiting course, ∼15%–20% of cases progress to severe acute pancreatitis [1] characterized by persistent organ failure, and potentially leading to death. This case describes the exceptionally rapid progression of acute pancreatitis from initially mild interstitial disease to near-total pancreatic necrosis, emphysematous changes, and fatal multiorgan failure within 48 h despite early tertiary-level care and multidisciplinary management.

Case presentation

A 77-year-old man presented to a tertiary teaching hospital in Australia with less than a day of severe epigastric pain, diaphoresis, and vomiting. His background included hypertension, gastro-oesophageal reflux disease, and diverticular disease. There was no history of previous abdominal surgeries, cholelithiasis, biliary symptoms, or alcohol use.

On presentation, he was haemodynamically stable (blood pressure 146/102, heart rate 67) but was tachypnoeic (respiratory rate 30/min) requiring 4 l/min of supplemental oxygen via nasal prongs to maintain saturation of 95%. He was afebrile. Abdominal examination revealed a soft abdomen, with tenderness localized to the epigastrium and left upper quadrant but without signs of peritonism.

Initial laboratory investigations revealed a lipase of 11 827 U/l, white cell count 17.9×10^9/l, C-reactive protein 6 mg/l, total bilirubin 26 umol/l, lactate 3.2 mmol/l, glucose 8.2 mmol/l, AST 50 U/l, and LDH 2.7 mmol/l. An admission Ranson score of 2 stratified his condition as unlikely to be severe pancreatitis. There was no pleural effusion on admission chest X-ray. Admission Bedside Index of Severity for Acute Pancreatitis (BISAP) score of 2 identified him as at increased risk of severe disease and mortality. Despite the low Ranson score, an early ICU referral was made due to the overall clinical picture.

Contrast-enhanced computed tomography (CT) of the abdomen at ∼3.5 h from onset of symptoms demonstrated imaging features of acute pancreatitis, with pancreatic enlargement and peripancreatic inflammatory changes (Fig. 1). The imaging was in keeping with acute interstitial oedematous pancreatitis with no necrosis. Based on the initial imaging findings, the pancreas demonstrated features consistent with Balthazar grade C, corresponding to a modified CT severity index of 2 (mild disease).

Evidence-based management for acute pancreatitis was instituted comprising close haemodynamic monitoring, aggressive crystalloid fluid resuscitation, protein pump inhibitor therapy, analgesia, antiemetics, and venous thromboembolism prophylaxis [2] with early surgical and intensive care unit review, as well as involving the hepatobiliary surgical team. Despite an initially low predicted risk of severe pancreatitis, the patient was admitted to the ICU given his early presentation and potential for deterioration. Subsequently, clinical concern for abdominal compartment syndrome, evolving

Received: 29 September 2026. **Accepted:** 26 October 2026
© The Author(s) 2026. Published by Oxford University Press and JSCR Publishing Ltd.
This is an Open Access article distributed under the terms of the Creative Commons Attribution License (https://creativecommons.org/licenses/by/4.0/), which permits unrestricted reuse, distribution, and reproduction in any medium, provided the original work is properly cited.

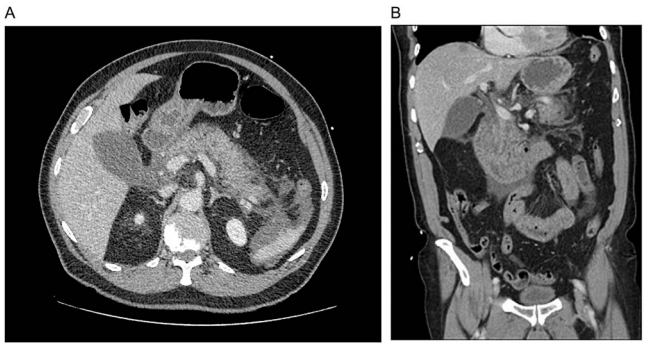

Figure 1 Index CT demonstrates stranding and mild peripancreatic fluid, particularly within the tail of the pancreas—Balthazar Grade C. The gallbladder appears unremarkable. No free gas present throughout the scan.

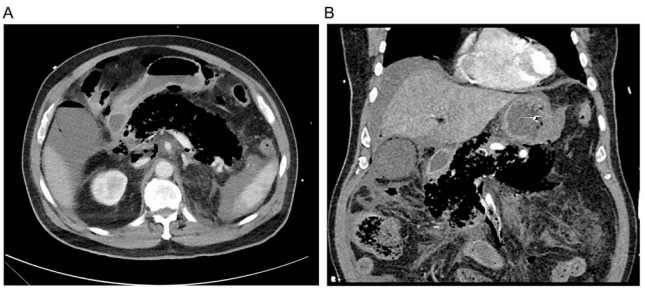

Figure 2 Portal venous and arterial phases of the CT demonstrate severe necrotizing pancreatitis with >90% of pancreas replaced with gas, intramural gas in the gallbladder and pneumoperitoneum, as well as portal vein compression from the inflammatory process.

respiratory failure, and a rising lactate prompted endotracheal intubation.

Overnight, the patient developed severe systemic inflammatory response syndrome (SIRS) contributing to worsening multiorgan failure with circulatory shock requiring escalating vasopressor support, acute kidney injury (with a peak creatinine of 189 umol/l and an eGFR of 29 ml/min/1.73 m^2), and rising lactate (peaking at 7.7 mmol/l). Hyperbilirubinemia (149 umol/l) prompted investigation with an abdominal ultrasound which demonstrated a distended gallbladder containing sludge, mild gallbladder wall thickening (4 mm), and concern for intramural gas and possible emphysematous cholecystitis. No definite cholelithiasis or biliary duct dilatation was identified.

The patient's significant clinical deterioration prompted a repeat CT scan which was performed less than 24 h after the initial study. This demonstrated severe necrotizing emphysematous pancreatitis with gas locules replacing almost all the pancreatic parenchyma, widespread pelvic free fluid, and significant pneumoperitoneum (Fig. 2). Despite the presence of significant pneumoperitoneum, contrast-enhanced CT demonstrated no contrast extravasation to suggest an associated gastrointestinal perforation or fistula. The intra-abdominal gas appeared to originate within the pancreatic parenchyma, with subsequent extension into the peritoneal cavity accounting for the pneumoperitoneum. This likely reflected the progression of pancreatic necrosis accompanied by gas production from intra-abdominal anaerobic organisms. The CT findings were in keeping with a Balthazar grade E with almost 95% necrosis that yielded a modified CT severity index 10 and re-classified his disease as severe.

Following discussion with the hepatopancreatobiliary service, the patient was transferred to a quaternary referral centre with the capacity to provide both image-guided drainage and emergency surgical intervention. In view of the patient's progressive deterioration despite maximal intensive care support, characterized by escalating inotropic requirements, worsening lactic acidosis, deteriorating pH and progressive multiorgan failure, emergency exploratory laparotomy, and pancreatic necrosectomy were undertaken as salvage treatment, with the aims of achieving sepsis source control and excluding additional intra-abdominal pathology not evident on CT. Worsening abdominal compartment syndrome provided a further indication for urgent operative intervention, as percutaneous drainage alone would not adequately address this complication. Following discussion with the patient's family, the decision to proceed with surgery was made collaboratively, with the aim of maximizing the patient's chance of survival in the context of his previously good premorbid health.

Intra-operative findings included a necrotizing haemorrhagic pancreas (predominantly involving the body and tail), a gangrenous gallbladder, extensive pancreatic ascites, and retroperitoneal fluid. No gastrointestinal perforation or fistula was identified. Cholecystectomy, evacuation of retroperitoneal fluid, and extensive pancreatic necrosectomy were undertaken (Fig. 3). A laparostomy was performed with an AbThera™ dressing.

Postoperatively the patient remained critically unwell with worsening multiorgan failure, increasing noradrenaline requirements to 18 ml/h and a serum lactate reaching 13 mmol/l. Despite maximal ICU support, the patient unfortunately continued to deteriorate and he died ∼48 h after presenting to hospital.

Discussion

This case demonstrates that acute pancreatitis can progress rapidly to fulminant multiorgan failure in a matter of hours despite early presentation, prompt diagnosis and guideline-driven, evidence-based management. Our patient presented early to a tertiary teaching hospital, where he was accurately diagnosed and appropriately treated. Initial imaging demonstrated interstitial oedematous pancreatitis without necrosis or local complications. Within hours, this had evolved to near total necrosis with emphysematous changes despite optimal management, a rate of radiological progression with few reported cases in the current literature.

The Revised Atlanta Classification remains the international standard for grading the severity of acute pancreatitis. It defines severe acute pancreatitis as the presence of persistent organ failure beyond 48 h, limiting early risk stratification at presentation. Furthermore, it recognizes that early radiological imaging is an unreliable predictor of disease severity, as pancreatic necrosis and local complications may not manifest for several days after symptom onset, a limitation illustrated by this patient's reassuring initial CT scan [3]. Consequently, accurate assessment of disease severity upon presentation remains an ongoing challenge.

Clinical scoring systems such as APACHE II, Ranson's criteria, and the BISAP, as well as radiological indices such as the CT Severity Index, are intended to address this diagnostic uncertainty. Recent systematic reviews and meta-analyses, however, demonstrate that these tools have only moderate predictive value, with no single scoring system consistently outperforming others in identifying patients who

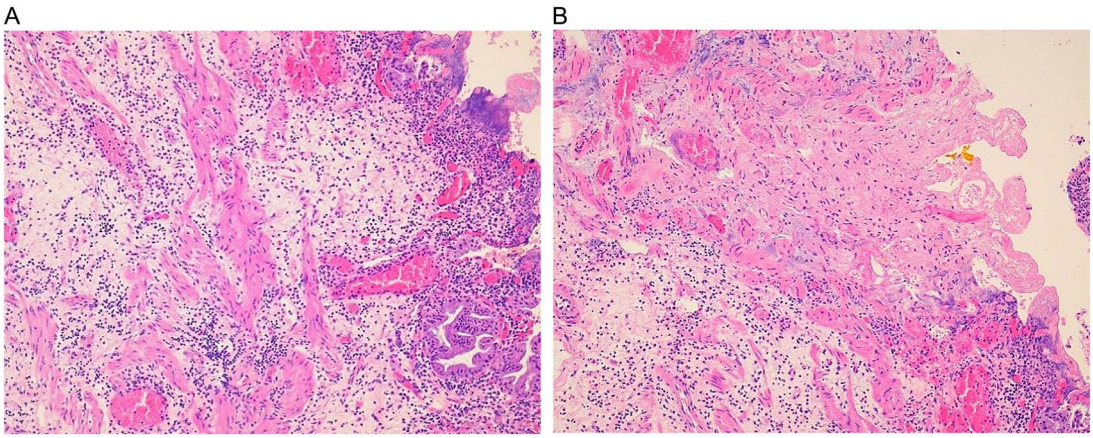

Figure 3 (A) Haematoxylin and eosin stain of gallbladder demonstrating an inflammatory mural infiltrate consistent with acute necrotizing cholecystitis, characterized by mucosal/mural necrosis, vascular congestion, haemorrhage, and patchy neutrophilic infiltration. (B) Haematoxylin and eosin stain of pancreas demonstrating extensive pancreatic parenchymal necrosis characterized by loss of cellular and nuclear detail, inflammatory infiltrate, and haemorrhage.

will deteriorate [4–6]. Therefore, current guidelines recommend that prognostic scores complement, rather than replace, clinical judgement and serial assessment.

Even with accurate stratification and timely escalation of treatment, a subset of patients will deteriorate despite appropriate management. Overall, mortality in pancreatitis is low, but rises to 15%–30% in severe acute pancreatitis even with early tertiary level care, particularly in those who develop persistent organ failure and infected pancreatic necrosis [7–9]. Despite early interventions according to modern management guidelines, the heterogenous nature of the disease is such that a subset take an unexpectedly fulminant course characterized by extensive pancreatic necrosis, a profound SIRS response, multi-organ failure, and rapid deterioration as demonstrated in this case.

Operative management in pancreatitis is associated with significant morbidity and mortality. As such it is reserved for critically ill patients with complications of pancreatitis and employs a 'step-up' strategy of intervention [10, 11]. Contemporary evidence supports delaying necrosectomy, provided there is no clinical deterioration, for at least 3–4 weeks after the onset of necrotizing pancreatitis to allow necrotic tissues to become walled off and well-demarcated [12]. However, abdominal compartment syndrome refractory to non-operative management, as seen in this case, is a recognized indication for urgent surgical decompression [8].

In this patient, clinical deterioration and multi-organ failure was likely multifactorial from rapidly progressive necrotizing pancreatitis with radiological features suspicious for infected necrosis, a gangrenous gallbladder, and evolving abdominal compartment syndrome. These diagnoses, along with worsening physiological parameters and escalating inotropic requirements despite maximal intensive care support prompted emergency surgery to address abdominal compartment syndrome, manage the gangrenous gallbladder and exclude other surgically reversible pathology that may not have been apparent on CT imaging. The severity of the patient's deterioration and the suspicion of infected necrosis also informed the decision to pursue urgent operative source control.

Although recent studies demonstrate that step-up approaches, progressing from conservative management to minimally invasive drainage and, if required, laparoscopic necrosectomy, have improved outcomes compared with immediate open surgical necrosectomy [10, 11], these recommendations must be considered in the context of individual circumstances. In this case, emergency surgery was undertaken as a salvage intervention in the setting of life-threatening deterioration, when the time required for a staged step-up approach was clinically untenable. Nevertheless, the limited evidence supporting emergency necrosectomy in this context precludes any generalization of this approach beyond similarly exceptional circumstances. Overall, mortality in patients requiring any intervention remains substantial [13] reflecting the severity of the underlying disease and systemic process rather than the surgical approach itself.

Conclusion

This case demonstrates that, despite contemporary evidence-based care at a tertiary and quaternary centre, comprehensive imaging and specialist expertise, acute pancreatitis can take a fulminant and unsalvageable course, illustrating the unpredictable and at times inexorable natural history of this condition. Additionally, this case highlights the limitation of current scoring systems or radiological findings to predict severity and guide treatment. Clinical acumen, close observation and serial assessment remain paramount in the management of patients critically ill with acute pancreatitis.

Conflicts of interest

None declared.

Funding

None declared.

References

1. Freeman ML, Banks PA. Practice guidelines in acute pancreatitis. *Am J Gastroenterol* 2006;**101**:2379–400. https://doi.org/10.1111/j.1572-0241.2006.00856.x
2. Takada T, Isaji S, Mayumi T *et al.* JPN clinical practice guidelines 2021 with easy-to-understand explanations for the management

of acute pancreatitis. *J Hepatobiliary Pancreat Sci* 2022;**29**:1057–83. https://doi.org/10.1002/jhbp.1146
3. Thoeni RF. The revised Atlanta classification of acute pancreatitis: its importance for the radiologist and its effect on treatment. *Radiology* 2012;**262**:751–64. https://doi.org/10.1148/radiol.11110947
4. van den Berg FF, de Bruijn AC, van Santvoort HC *et al.* Early laboratory biomarkers for severity in acute pancreatitis: a systematic review and meta-analysis. *Pancreatology* 2020;**20**:1302–11. https://doi.org/10.1016/j.pan.2020.09.007
5. Zhu J, Wu L, Wang Y *et al.* Predictive value of the Ranson and BISAP scoring systems for the severity and prognosis of acute pancreatitis: a systematic review and meta-analysis. *PloS One* 2024;**19**:e0302046. https://doi.org/10.1371/journal.pone.0302046
6. Capurso G, de Leon P, Pisani R *et al.* Clinical usefulness of scoring systems to predict severe acute pancreatitis: a systematic review and meta-analysis with pre and post-test probability assessment. *United European Gastroenterol J* 2023;**11**:825–36. https://doi.org/10.1002/ueg2.12464
7. Petrov MS, Shanbhag S, Chakraborty M *et al.* Organ failure and infection of pancreatic necrosis as determinants of mortality in patients with acute pancreatitis. *Gastroenterology* 2010;**139**:813–20. https://doi.org/10.1053/j.gastro.2010.06.010
8. Leppäniemi A, Tolonen M, Tarasconi A *et al.* 2019 WSES guidelines for the management of severe acute pancreatitis. *World J Emerg Surg* 2019;**14**:27. https://doi.org/10.1186/s13017-019-0247-0
9. Johnson CD, Besselink MG, Carter R. Acute pancreatitis. *BMJ* 2014;**349**:g4859. https://doi.org/10.1136/bmj.g4859
10. van Santvoort HC, Besselink MG, Bakker OJ *et al.* A step-up approach or open necrosectomy for necrotizing pancreatitis. *N Engl J Med* 2010;**362**:1491–502. https://doi.org/10.1056/NEJMoa0908821
11. Tenner S, Vege SS, Sheth SG *et al.* American College of Gastroenterology guidelines: management of acute pancreatitis. *Am J Gastroenterol* 2024;**119**:419–37. https://doi.org/10.14309/ajg.0000000000002645
12. Isaji S, Takada T, Kawarada Y *et al.* JPN guidelines for the management of acute pancreatitis: surgical management. *J Hepatobiliary Pancreat Surg* 2006;**13**:48–55. https://doi.org/10.1007/s00534-005-1051-7
13. Trikudanathan G, Wolbrink DRJ, van Santvoort HC *et al.* Current concepts in severe acute and necrotizing pancreatitis: an evidence-based approach. *Gastroenterology* 2019;**156**:1994–2007.e3. https://doi.org/10.1053/j.gastro.2019.01.269

© The Author(s) 2026. Published by Oxford University Press and JSCR Publishing Ltd. This is an Open Access article distributed under the terms of the Creative Commons Attribution License (https://creativecommons.org/licenses/by/4.0/), which permits unrestricted reuse, distribution, and reproduction in any medium, provided the original work is properly cited.
Journal of Surgical Case Reports, 2026, **2026**(11), rjag1065
https://doi.org/10.1093/jscr/rjag1065
Case Report