Journal of Surgical Case Reports, 2026, 2026(11), rjag1064
https://doi.org/10.1093/jscr/rjag1064
Published: 20 November 2026
Case Series

OXFORD

Contrasting presentations of gallstone ileus: delayed diagnosis and successful laparoscopic-assisted enterolithotomy in two elderly women

Huma Amjad* and Alladden I. Elshiere

General Surgery, Wexford General Hospital, Newtown Road, Carricklawn, Wexford Y35 Y17D, Ireland

*Corresponding author. General Surgery, Wexford General Hospital, Newtown Road, Carricklawn, Wexford Y35 Y17D, Ireland. Email: huma.amjad567@gmail.com

Abstract

Gallstone ileus is an uncommon but important cause of mechanical small bowel obstruction in older adults and is associated with significant morbidity owing to delayed diagnosis. We present two elderly women with gallstone ileus who experienced contrasting diagnostic pathways and postoperative recovery despite successful management with laparoscopic-assisted enterolithotomy. In the first patient, computed tomography (CT) promptly demonstrated Rigler's triad, allowing early surgical intervention. In the second, symptoms were initially attributed to recent semaglutide dose escalation, while ultrasonography suggested acute cholecystitis, delaying definitive CT imaging and diagnosis. Both patients underwent laparoscopic-assisted enterolithotomy without cholecystectomy or fistula repair. These cases highlight the importance of maintaining a high index of suspicion for gallstone ileus in elderly patients presenting with persistent obstructive symptoms, the diagnostic superiority of CT imaging, and the feasibility of laparoscopic-assisted enterolithotomy as definitive treatment in appropriately selected patients.

Keywords **gallstone ileus, small bowel obstruction, enterolithotomy, laparoscopic surgery, computed tomography, cholecystoduodenal fistula**

Introduction

Gallstone ileus is a rare complication of cholelithiasis, accounting for approximately 1–4% of all cases of mechanical small bowel obstruction [1] and up to 25% of non-strangulating small bowel obstruction in patients over 65 years of age [2]. It results from the passage of a gallstone through a biliary-enteric fistula, most commonly a cholecystoduodenal fistula, with subsequent impaction within the small bowel, usually at the terminal ileum. Although uncommon, gallstone ileus remains associated with considerable morbidity and mortality because affected patients are typically elderly with multiple comorbidities, and diagnosis is frequently delayed by its non-specific clinical presentation.

Computed tomography (CT) has become the imaging modality of choice because of its high sensitivity for identifying Rigler's triad of pneumobilia, small bowel obstruction, and an ectopic gallstone [3], thereby facilitating early diagnosis and operative planning. Despite advances in imaging, the optimal surgical strategy remains controversial. Gallstone ileus is associated with substantial morbidity and mortality, with reported mortality rates ranging from 12% to 27% [4].

While one-stage surgery combining enterolithotomy, cholecystectomy, and fistula closure definitively addresses the underlying biliary pathology, enterolithotomy alone is generally preferred in elderly or medically frail patients because it is associated with lower operative morbidity and mortality. Minimally invasive techniques, including laparoscopic-assisted enterolithotomy, have emerged as safe alternatives in carefully selected patients.

We present two elderly women with gallstone ileus who followed markedly different diagnostic pathways despite having the same underlying pathology. One patient underwent prompt CT imaging leading to early definitive management, whereas the diagnosis in the second patient was delayed because her symptoms were initially attributed to recent semaglutide dose escalation and ultrasonography suggested acute cholecystitis. Both patients were successfully treated with laparoscopic-assisted enterolithotomy without cholecystectomy or fistula repair. These cases illustrate the diagnostic challenges of gallstone ileus, highlight the importance of early cross-sectional imaging, and support laparoscopic-assisted enterolithotomy as an effective treatment strategy in selected patients.

Case series

Case 1

A woman in her seventies presented to the emergency department with a 3-day history of colicky abdominal pain, bilious vomiting,

Received: 13 September 2026. **Accepted:** 22 October 2026
© The Author(s) 2026. Published by Oxford University Press and JSCR Publishing Ltd.
This is an Open Access article distributed under the terms of the Creative Commons Attribution License (https://creativecommons.org/licenses/by/4.0/), which permits unrestricted reuse, distribution, and reproduction in any medium, provided the original work is properly cited.

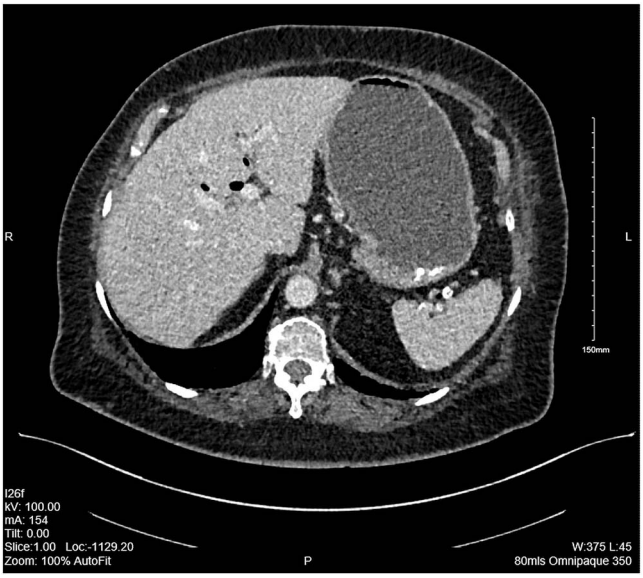

Figure 1 Contrast-enhanced CT scan of the abdomen demonstrating pneumobilia with a contracted gallbladder closely abutting the duodenum, findings consistent with a cholecystoduodenal fistula.

progressive abdominal distension, and absolute constipation for 48 hours. Her medical history included hypertension and type 2 diabetes mellitus, with no previous abdominal surgery.

On examination, she was haemodynamically stable but clinically dehydrated. Her abdomen was distended with diffuse tenderness but without guarding or peritonism, and bowel sounds were hyperactive. Laboratory investigations demonstrated a white cell count of 10.5×10^9/L, C-reactive protein (CRP) of 349.7 mg/L, mild cholestatic liver enzyme derangement, and hypokalaemia consistent with persistent vomiting.

Plain abdominal radiography demonstrated multiple dilated small bowel loops with air–fluid levels, consistent with small bowel obstruction but without an identifiable cause. Contrast-enhanced CT of the abdomen and pelvis subsequently demonstrated markedly dilated proximal small bowel with a transition point in the distal ileum caused by a 3.2-cm rim-calcified intraluminal gallstone. Pneumobilia and a contracted gallbladder closely adherent to the duodenum were also identified, consistent with a cholecystoduodenal fistula (Fig. 1). There was no radiological evidence of bowel ischaemia or perforation. The presence of small bowel obstruction, pneumobilia, and an ectopic gallstone confirmed the diagnosis of gallstone ileus.

Following intravenous fluid resuscitation, nasogastric decompression, electrolyte correction, and broad-spectrum antibiotics, the patient underwent laparoscopic-assisted enterolithotomy. A large gallstone impacted approximately 25 cm proximal to the ileocaecal valve was identified (Fig. 2). A longitudinal enterotomy was performed directly over the stone, which was removed intact, and the enterotomy was closed transversely with interrupted absorbable sutures to minimise luminal narrowing. Cholecystectomy and fistula repair were not attempted because of the increased operative risk associated with extensive dissection in an elderly patient.

The postoperative course was uncomplicated. Bowel function returned on postoperative day three, oral intake was gradually resumed, and the patient was discharged home on postoperative day six. Follow-up at two and six weeks demonstrated complete recovery without recurrent bowel obstruction or biliary symptoms.



Figure 2 Intraoperative image of an impacted gallstone in the distal ileum (patient 1).

Case 2

A second woman in her seventies presented with an 11-day history of persistent vomiting, intermittent diarrhoea, progressive abdominal distension, and an unintentional weight loss of approximately 6 kg. Her medical history included type 2 diabetes mellitus, obesity, hypothyroidism, and obstructive sleep apnoea. She had recently undergone an increase in her semaglutide dose and initially attributed her symptoms to medication-related gastrointestinal side effects.

On admission, she was haemodynamically stable but clinically dehydrated. Examination demonstrated epigastric tenderness without guarding or peritonism. Laboratory investigations revealed a CRP of 141.9 mg/L with mild cholestatic liver enzyme derangement, while serum electrolytes remained within normal limits.

Given the biochemical abnormalities and upper abdominal tenderness, abdominal ultrasonography was performed initially and demonstrated gallbladder wall thickening suggestive of acute cholecystitis. However, bowel visualisation was limited and no obstructing gallstone or evidence of small bowel obstruction was identified. Intravenous antibiotics were commenced, but despite treatment the patient's vomiting persisted and abdominal distension progressively worsened. Ongoing clinical concern prompted contrast-enhanced CT imaging four days after admission, which demonstrated dilated small bowel loops with a 3.5-cm ectopic gallstone impacted within the proximal-to-mid ileum, together with pneumobilia, confirming gallstone ileus (Fig. 3). No evidence of bowel ischaemia or perforation was present.

Following resuscitation and nasogastric decompression, the patient underwent laparoscopic-assisted enterolithotomy. The obstructed bowel segment was exteriorised through a small midline incision, a longitudinal enterotomy was performed, and the impacted gallstone was removed intact. Dense inflammatory adhesions surrounding the gallbladder and duodenum precluded safe cholecystectomy or fistula dissection, and enterolithotomy alone was therefore performed.

Recovery was complicated by transient postoperative ileus with delayed tolerance of enteral nutrition, requiring temporary nasogastric decompression, dietetic support, physiotherapy, and gradual nutritional rehabilitation. Bowel function returned by postoperative

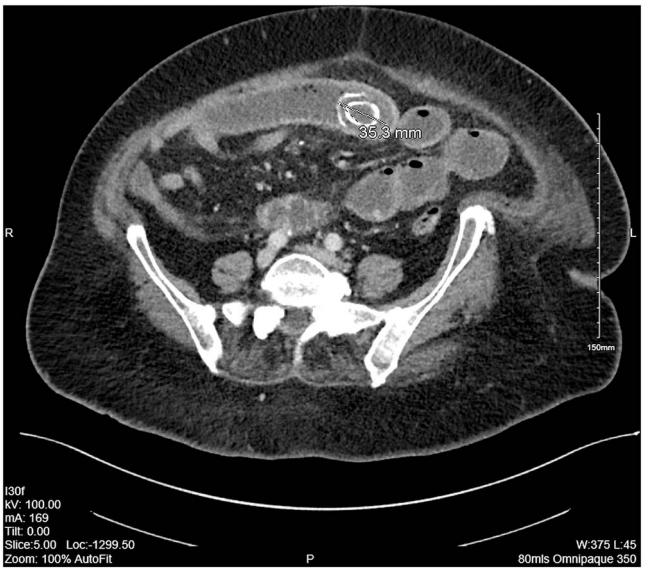

Figure 3 Axial contrast-enhanced CT scan of the abdomen demonstrating a rim-calcified intraluminal gallstone within the mid ileum, with associated proximal small bowel dilatation.

day ten, allowing progressive reintroduction of oral intake before discharge. At four-week follow-up, the patient had returned to her baseline functional status without recurrent obstructive symptoms or postoperative complications.

Discussion

Gallstone ileus remains an uncommon but clinically important cause of mechanical small bowel obstruction in older adults. Although it accounts for only 1–4% of all cases of small bowel obstruction [1], its incidence increases substantially in the elderly population, particularly among women with longstanding cholelithiasis. Despite advances in diagnostic imaging and perioperative care, delayed diagnosis continues to contribute significantly to the morbidity associated with this condition. The contrasting clinical courses of our patients demonstrate how differences in diagnostic timing can influence postoperative recovery despite similar operative management. Although evidence remains limited because of the rarity of the condition, several contemporary case series have demonstrated that laparoscopic-assisted enterolithotomy is feasible in carefully selected patients, with the potential advantages of smaller incisions, reduced postoperative pain and shorter hospital stay compared with conventional laparotomy. However, high-quality comparative studies remain lacking.

The first patient underwent early CT imaging after initial assessment, allowing prompt identification of Rigler's triad and timely surgical intervention. In contrast, diagnosis in the second patient was delayed because her symptoms were initially attributed to recent semaglutide dose escalation and ultrasonography demonstrated findings suggestive of acute cholecystitis. Gastrointestinal adverse effects such as nausea, vomiting, abdominal discomfort and delayed gastric emptying are well recognised with glucagon-like peptide-1 (GLP-1) receptor agonists and may overlap with the presenting symptoms of mechanical bowel obstruction. Although there is no evidence that semaglutide caused gallstone ileus in our patient, it contributed to an alternative diagnostic pathway that delayed definitive cross-sectional imaging. As the use of GLP-1 receptor agonists continues to increase, clinicians should remain vigilant and avoid attributing persistent or progressive obstructive symptoms solely to medication-related adverse effects without excluding surgical pathology. These cases also highlight the importance of avoiding premature diagnostic closure. In Patient 2, the recent escalation of semaglutide therapy provided a plausible alternative explanation for persistent vomiting, delaying cross-sectional imaging. Although medication-related gastrointestinal symptoms are common with GLP-1 receptor agonists, persistent abdominal distension, failure to tolerate oral intake, and evolving features of bowel obstruction should prompt early CT evaluation to exclude mechanical causes. As GLP-1 receptor agonists become increasingly prescribed worldwide, awareness of this potential diagnostic pitfall is likely to become increasingly relevant in emergency surgical practice.

Our cases also reinforce the central role of CT in the diagnosis of gallstone ileus. While abdominal radiography demonstrated non-specific features of small bowel obstruction in both patients, and ultrasonography suggested biliary pathology in the second patient, neither modality established the diagnosis. Contrast-enhanced CT accurately identified the ectopic gallstone, pneumobilia and transition point in both cases, allowing definitive diagnosis and operative planning. CT has been reported to have a sensitivity exceeding 90% for gallstone ileus and remains the imaging modality of choice when this diagnosis is suspected [5]. Early CT should therefore be considered in elderly patients presenting with bowel obstruction, particularly when the clinical picture is atypical or symptoms fail to improve despite initial treatment.

The optimal operative strategy for gallstone ileus remains controversial. One-stage surgery, comprising enterolithotomy, cholecystectomy and fistula closure, provides definitive treatment but requires extensive dissection in an acutely inflamed operative field and has historically been associated with higher morbidity and mortality. Consequently, enterolithotomy alone is generally recommended for elderly or medically frail patients [6], reserving definitive biliary surgery for selected individuals with persistent biliary symptoms or recurrent complications. In both of our patients, dense inflammatory adhesions around the gallbladder and duodenum made fistula dissection technically hazardous, and enterolithotomy alone provided effective treatment without recurrent biliary symptoms during follow-up.

Postoperative management plays a critical role in patient recovery. As demonstrated in Patient B, a multidisciplinary approach involving surgical, physiotherapy, and dietetic input can facilitate the return of bowel function and mitigate postoperative complications. Early mobilisation and gradual advancement of enteral nutrition have been identified as key factors in reducing postoperative ileus. A large review of 1001 cases by Reisner and Cohen [7] reported a mortality rate of 16.9%, underscoring the importance of early recognition and timely management. More recent analyses have demonstrated mortality rates below 8% with minimally invasive approaches [8].

An additional feature of this case series is the successful use of laparoscopic-assisted enterolithotomy in both patients. Although conventional laparotomy remains the most commonly reported approach, minimally invasive techniques are increasingly recognised as feasible in haemodynamically stable patients managed by surgeons with appropriate laparoscopic expertise. The laparoscopic approach allows confirmation of the diagnosis, localisation of the obstructing gallstone and limited exteriorisation of the affected bowel through a small incision, thereby reducing abdominal wall trauma while preserving the principles of safe enterolithotomy. Recurrence

following simple enterolithotomy is uncommon, with reported rates below 10% when residual stones are excluded intraoperatively [9]. The favourable outcomes observed in both patients presented support the role of enterolithotomy alone as a safe and effective treatment strategy in elderly patients.

Both of our patients were successfully managed using this technique, although postoperative recovery differed considerably, reflecting the impact of delayed diagnosis and prolonged preoperative obstruction rather than the operative approach itself.

The principal limitation of this report is its small sample size, which precludes generalisation of outcomes. Nevertheless, the value of this case series lies in illustrating two markedly different diagnostic pathways for the same uncommon condition within a single institution. The comparison emphasises the importance of maintaining a high index of suspicion for gallstone ileus, recognising potential diagnostic confounders, and performing early CT imaging in elderly patients with persistent obstructive symptoms. Our experience also supports laparoscopic-assisted enterolithotomy as a safe and effective treatment option for appropriately selected patients.

Conflicts of interest

The authors declare no conflict of interest.

Funding

No funding was received for this study.

Data availability

The data supporting the findings of this study are available from the corresponding author upon reasonable request. No new datasets were generated or analysed during the current study.

Consent

Written informed consent for publication of the clinical details and accompanying images was obtained from both patients.

References

1. Halabi WJ, Kang CY, Ketana N *et al.* Surgery for gallstone ileus: a nationwide comparison of trends and outcomes. *J Gastrointest Surg* 2014;**259**:329–35. https://doi.org/10.1097/SLA.0b013e31827eefed
2. Alzerwi NAN, Idrees B, Alsareii S *et al.* The regularity of the site of impaction in recurrent gallstone ileus: a systematic review and meta-analysis of reported cases. *Can J Gastroenterol Hepatol* 2021;**2021**:5539789.
3. Zabeirou A, Saidou A, Younssa H *et al.* An authentic radiological triad of Rigler allowing the diagnosis of gallstone ileus: a case report. *Radiol Case Rep* 2024;**19**:1565–7. https://doi.org/10.1016/j.radcr.2024.01.022
4. Sánchez-Pérez EA, Álvarez-Álvarez S, Madrigal-Téllez MA *et al.* Gallstone ileus: experience in the Dr Eduardo Liceaga general Hospital of Mexico. *Cir Cir* 2017;**85**:114–20. https://doi.org/10.1016/j.circir.2016.05.018
5. Yu CY, Lin CC, Shyu RY *et al.* Value of CT in the diagnosis and management of gallstone ileus. *World J Gastroenterol* 2005;**11**:2142–7. https://doi.org/10.3748/wjg.v11.i14.2142
6. Inukai K. Gallstone ileus: a review. *BMJ Open Gastroenterol* 2019;**6**:e000344. https://doi.org/10.1136/bmjgast-2019-000344
7. Reisner RM, Cohen JR. Gallstone ileus: a review of 1001 reported cases. *Am Surg* 1994;**60**:441–6.
8. Orellana M, Vegas L, Caceres A *et al.* Laparoscopic management of gallstone ileus: a case report and literature review. *Int J Surg Case Rep* 2021;**85**:106171. https://doi.org/10.1016/j.ijscr.2021.106171
9. Mir SA, Hussain Z, Davey CA *et al.* Management and outcome of recurrent gallstone ileus: a systematic review. *World J Gastrointest Surg* 2015;**7**:152–9. https://doi.org/10.4240/wjgs.v7.i8.152

© The Author(s) 2026. Published by Oxford University Press and JSCR Publishing Ltd. This is an Open Access article distributed under the terms of the Creative Commons Attribution License (https://creativecommons.org/licenses/by/4.0/), which permits unrestricted reuse, distribution, and reproduction in any medium, provided the original work is properly cited.