frontiers in Oncology

TYPE Case Report
PUBLISHED 06 November 2026
DOI 10.3389/fonc.2026.2004627

Check for updates

OPEN ACCESS

EDITED BY
Rakesh Kapoor,
Post Graduate Institute of Medical Education and Research (PGIMER), India

REVIEWED BY
Tan-Huy Chu,
Tam Anh Research Institute, Vietnam
Chikashi Ishioka,
Tohoku University, Japan

*CORRESPONDENCE
Haiyan Liu
fylhy1998@163.com

RECEIVED 20 September 2026
REVISED 15 October 2026
ACCEPTED 26 October 2026
PUBLISHED 06 November 2026

CITATION
Li C, Li M, Wang S, Xu M and Liu H (2026) Case Report: Durable response to tislelizumab monotherapy in microsatellite-stable, BRAF V600E-mutant right-sided colon cancer with extremely high PD-L1 expression. *Front. Oncol.* 16:2004627. doi: 10.3389/fonc.2026.2004627

COPYRIGHT
© 2026 Li, Li, Wang, Xu and Liu. This is an open-access article distributed under the terms of the Creative Commons Attribution License (CC BY). The use, distribution or reproduction in other forums is permitted, provided the original author(s) and the copyright owner(s) are credited and that the original publication in this journal is cited, in accordance with accepted academic practice. No use, distribution or reproduction is permitted which does not comply with these terms.

Case Report: Durable response to tislelizumab monotherapy in microsatellite-stable, BRAF V600E-mutant right-sided colon cancer with extremely high PD-L1 expression

Chen Li[1], Mingyan Li[1], Simin Wang[2], Mingxin Xu[1] and Haiyan Liu[1]*

[1]Department of Oncology, The Second Affiliated Hospital of Shandong First Medical University, Tai'an, Shandong, China, [2]Department of Pathology, The Second Affiliated Hospital of Shandong First Medical University, Tai'an, Shandong, China

Colorectal cancer with proficient mismatch repair (pMMR)/microsatellite stable (MSS) status is generally intrinsically resistant to immune checkpoint inhibitors; tumors with concomitant *BRAF* V600E mutations are highly aggressive, and conventional chemotherapy and targeted therapies have limited efficacy, resulting in a lack of effective personalized treatment options in clinical practice. This report describes a case of locally advanced right-sided colon adenocarcinoma that was pMMR/MSS, harbored a *BRAF* V600E mutation, and exhibited high programmed death-ligand 1 (PD-L1) expression (tumor proportion score [TPS] > 95%). The patient developed intestinal obstruction after failure of first-line conversion therapy. After undergoing palliative gastrojejunostomy and cecostomy, she developed gastroparesis and a liver abscess. Given the extremely high PD-L1 expression, tislelizumab monotherapy was initiated before the patient's general condition had fully recovered. After three cycles, the patient's performance status improved significantly. She then received a combination of tislelizumab and raltitrexed for two cycles; however, chemotherapy was discontinued due to raltitrexed-induced liver injury, and the patient continued maintenance therapy with tislelizumab monotherapy, achieving a partial response (PR) as the best outcome. After nine cycles of maintenance therapy, a new mass appeared in the right adnexal region, indicating disease progression; the overall progression-free survival (PFS) was 14 months. To the best of our knowledge, this is the first reported case of a patient with colorectal adenocarcinoma harboring a *BRAF* V600E mutation, characterized by extremely high PD-L1 expression and pMMR/MSS status, who achieved a PR with a regimen centered on programmed cell death protein 1 (PD-1) inhibitor monotherapy. This case suggests that for

BRAF V600E-mutated colorectal cancer, assessment of PD-L1 expression levels should be considered regardless of mismatch repair status; if extremely high PD-L1 expression is present, even in the pMMR/MSS phenotype, PD-1 inhibitors may offer a potential personalized treatment option for these patients with poor prognosis and limited therapeutic choices.

KEYWORDS

***BRAF* V600E mutation, case report, colorectal cancer, microsatellite stable, PD-1 inhibitor, PD-L1, tislelizumab, tumor proportion score**

1 Introduction

Colorectal cancer is a highly prevalent malignant tumor worldwide, and both the incidence and mortality rates are increasing among younger populations (1). Immune checkpoint inhibitors (ICIs) have transformed the treatment landscape for advanced colorectal cancer; however, clinical benefits are largely restricted to a small subset of deficient mismatch repair (dMMR)/microsatellite instability-high (MSI-H) patients, while proficient mismatch repair (pMMR)/microsatellite stable (MSS) tumors, which constitute over 95% of cases, typically exhibit primary resistance to ICIs (2), leaving limited treatment options and representing a significant unmet clinical need.

The *BRAF* V600E mutation occurs in approximately 10% of colorectal cancer patients and is a well-established marker of poor prognosis. This mutation drives tumor proliferation and metastasis through sustained activation of the mitogen-activated protein kinase (MAPK) pathway (3). Data from the TRIBE study (4) indicate that patients with advanced colorectal cancer and *BRAF* V600E mutations, regardless of receiving FOLFIRI or FOLFOXIRI plus bevacizumab, had a notably shorter median overall survival (OS) compared to those with *BRAF* wild-type tumors (10.7–19.0 months vs. 37.1 months).

Recent studies have suggested that *BRAF*-mutant colorectal cancer is not invariably immunorefractory (5), and responses to immunotherapy-based combinations have occasionally been reported in patients with MSS colorectal cancer and high programmed death-ligand 1 (PD-L1) expression (6, 7). However, whether such patients can benefit from ICI monotherapy remains unreported. This report describes a patient with right-sided colon adenocarcinoma of this molecular subtype who had a PD-L1 tumor proportion score (TPS) > 95%. Given the failure of first-line conversion therapy and the patient's extremely poor performance status and very high PD-L1 expression, a treatment regimen with single-agent tislelizumab was initiated. The patient achieved a durable partial response (PR) with a progression-free survival of 14 months, providing additional clinical evidence for personalized immunotherapy in patients with this subtype.

We present the following case in accordance with the CARE reporting checklist.

2 Case presentation

2.1 Patient information and clinical findings

A 46-year-old female patient was admitted on August 13, 2024, due to an incidentally discovered mass in the right upper abdomen with tenderness. She had no significant past medical history and had not received any prior treatment for this condition. She denied smoking or alcohol use, had no family history of cancer, and was psychologically stable with good family support.

On physical examination, the patient appeared pale, and her vital signs were stable (blood pressure 118/80 mmHg; heart rate 72 beats/min). A firm, tender 5 × 5 cm mass was palpated in the right upper abdomen without rebound tenderness; the remainder of the physical examination was unremarkable.

2.2 Diagnostic assessment

Laboratory tests revealed severe microcytic hypochromic anemia (hemoglobin 55 g/L; reference range 115–150 g/L; mean corpuscular volume 63.4 fL; mean corpuscular hemoglobin 16.6 pg), low serum iron (2.6 μmol/L; reference range 7.8–32.2 μmol/L), and a positive fecal occult blood test. Tumor markers were markedly elevated, including carcinoembryonic antigen 38.67 ng/mL (reference range 0–5 ng/mL) and carbohydrate antigen 19-9 (CA19-9) 579.34 U/mL (reference range 0–35 U/mL). Liver and renal function tests were normal. Serologic screening for hepatitis B, hepatitis C, human immunodeficiency virus, and syphilis was negative. Given the right upper abdominal mass and evidence of gastrointestinal bleeding, a colonic space-occupying lesion was initially suspected.

Abdominal ultrasound showed a hypoechoic mass at the hepatic flexure with multiple enlarged retroperitoneal lymph nodes. Contrast-enhanced computed tomography (CT) of the chest and abdomen revealed scattered linear opacities in both lungs without space-occupying lesions; circumferential wall thickening and a mass-like soft-tissue shadow at the hepatic flexure of the right colon, surrounded by multiple enlarged lymph nodes, some confluent; a filling defect within the superior mesenteric vein, suggesting possible tumor thrombus; and a small, round, slightly hypodense lesion in liver segment S4, for which metastasis could not be excluded. To characterize the S4 lesion, contrast-enhanced magnetic resonance imaging of the upper abdomen was performed; the lesion showed no enhancement, confirming a hepatic cyst and excluding metastasis. The imaging findings required differentiation from colonic lymphoma, gastrointestinal stromal tumor, and other entities.

Colonoscopy revealed a large, irregular, cauliflower-like mass at the hepatic flexure; the tumor was fragile and bled readily on contact, and luminal stenosis prevented passage of the endoscope. Histopathological examination of the biopsy specimen confirmed adenocarcinoma.

10.3389/fonc.2026.2004627

Immunohistochemistry showed intact expression of MLH1, MSH2, MSH6, and PMS2 proteins (pMMR); next-generation sequencing revealed a *BRAF* V600E mutation, a wild-type *POLE* gene, and microsatellite stable (MSS) status; PD-L1 expression testing (SP263 antibody, VENTANA BenchMark XT platform) showed a TPS > 95%. Representative immunohistochemical staining of the four mismatch repair proteins is shown in Figure 1.

Integrating the imaging, endoscopic, and molecular pathology findings, the final diagnosis was right-sided colon adenocarcinoma (cT4N2M0, stage IIIC) that was pMMR/MSS and harbored a *BRAF* V600E mutation; this stage and molecular profile constitute a high-risk phenotype with poor prognosis.

2.3 Therapeutic intervention and clinical course

At initial presentation, the patient had marked anemia and received three blood transfusions, totaling 4.5 units of leukocyte-depleted packed red blood cells; follow-up hemoglobin increased to 107 g/L. To preserve the possibility of surgery, the multidisciplinary team selected a conversion regimen of bevacizumab plus FOLFOXIRI. Bevacizumab (400 mg) was administered intravenously on day 1; FOLFOXIRI consisted of irinotecan (200 mg, day 2), oxaliplatin (100 mg, day 3), leucovorin (500 mg, day 3), and fluorouracil (2875 mg as a 48-hour continuous intravenous infusion), with cycles repeated every three weeks. Because the patient still had melena at treatment initiation (September 1, 2024) and was considered at risk of gastrointestinal bleeding, bevacizumab was withheld during the first cycle, and only FOLFOXIRI was administered. On September 23, 2024, repeat fecal occult blood testing was negative, indicating control of gastrointestinal bleeding, and the planned chemotherapy-targeted therapy combination was then initiated for one cycle. After a total of two cycles of conversion therapy, imaging showed stable disease. Following consultation with the Department of General Surgery, continuation of the same regimen for two additional cycles was recommended. However, during the fourth cycle, the patient developed intestinal obstruction. Conservative management was ineffective, and laparoscopic exploration was performed on December 4, 2024, revealing a 5 × 6 cm firm mass at the hepatic flexure penetrating through the full thickness of the bowel wall and directly invading the descending duodenum and the right lobe of the liver; the mass was fixed, with no ascites or peritoneal seeding, making radical resection unfeasible. The procedure was converted to open surgery, and palliative gastrojejunostomy and cecostomy were performed. Based on intraoperative findings, this episode of obstruction was definitively attributed to tumor progression.

Postoperatively, the patient's recovery was poor, and she developed secondary gastroparesis and a liver abscess; her Eastern Cooperative Oncology Group (ECOG) performance status score was 3. Due to the severe infection and markedly impaired performance status, all anticancer treatments were suspended, and the patient was managed with broad-spectrum antibiotics, hepatoprotective agents, and nutritional support.

After control of the liver abscess, she remained poorly tolerant of chemotherapy, and her performance status remained at 3. Considering her clinical condition and the very high PD-L1 expression, tislelizumab monotherapy (200 mg intravenously every 3 weeks) was initiated on February 6, 2025. After two cycles, follow-up CT revealed marked shrinkage of the primary mass, from 3.16 cm at baseline to 2.14 cm (a 32% reduction), indicating a partial response (PR). After completion of three cycles of monotherapy, the patient's general condition improved significantly, and her ECOG score recovered to 1. From April 22 to May

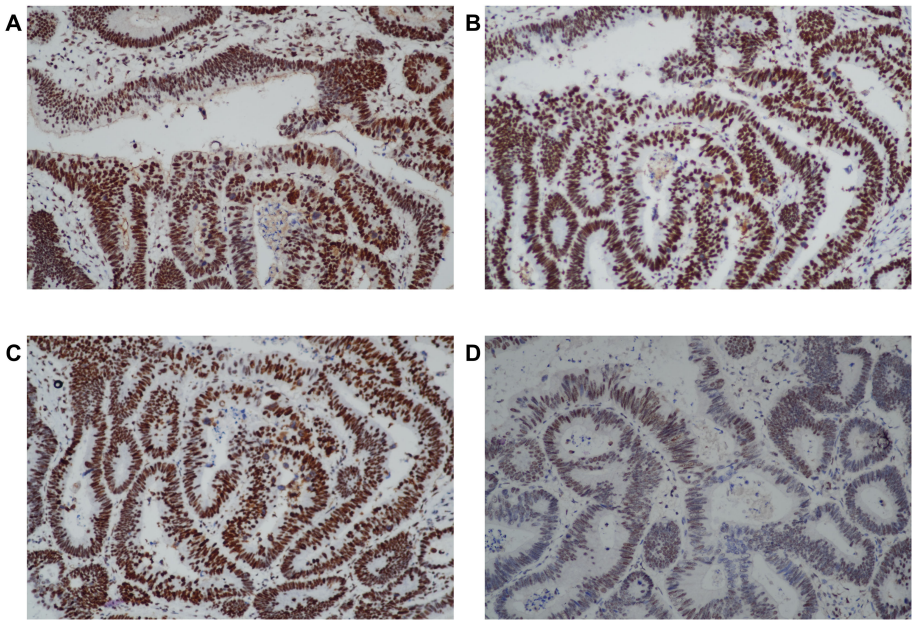

FIGURE 1
Mismatch repair protein expression in the primary tumor. Immunohistochemical staining showed intact nuclear expression of MLH1 **(A)**, MSH2 **(B)**, MSH6 **(C)**, and PMS2 **(D)** in tumor cells, confirming proficient mismatch repair (pMMR) and microsatellite-stable (MSS) status. Magnification, ×200.

21, 2025, treatment was modified to two cycles of tislelizumab combined with raltitrexed (4 mg intravenously every three weeks). During this period, abnormal liver function was observed. Serologic markers for hepatitis A, B, C, and E viruses were all negative. Methylprednisolone sodium succinate (40 mg) was ineffective; drug-induced liver injury caused by raltitrexed was suspected, and chemotherapy was therefore discontinued.

Given the patient's poor tolerance to chemotherapy and high PD-L1 expression, maintenance therapy with tislelizumab monotherapy (200 mg every three weeks) was initiated on July 10, 2025. At follow-up after two cycles, the response remained a PR, achieving durable tumor control. Representative CT images at baseline and at best response are presented in Figure 2. As of March 2026, the patient had completed nine cycles of maintenance monotherapy and had cumulatively received 14 tislelizumab treatments with no immune-related adverse events reported, and her quality of life had improved markedly.

A follow-up examination in April 2026 revealed a new mass in the right adnexal region, considered to represent metastatic disease; the condition was assessed as progressive, with a progression-free survival (PFS) of 14 months. Re-biopsy of the primary lesion showed a PD-L1 TPS of 5%, a marked decrease from baseline. PD-L1 expression at baseline and at progression is shown in Figure 3. The patient subsequently received penpulimab in combination with bevacizumab and trifluridine/tipiracil (TAS-102). A follow-up examination 5 months later showed near-complete disappearance of the right adnexal lesion; the disease remained stable, and the patient's quality of life was good. The patient maintained good adherence throughout the entire treatment course. A detailed timeline of the treatment course and efficacy evaluations is shown in Figure 4.

3 Discussion

This case represents the first reported instance of durable response to programmed cell death protein 1 (PD-1) inhibitor monotherapy in a patient with pMMR/MSS, *BRAF* V600E-mutated right-sided colon adenocarcinoma and extreme PD-L1 expression (TPS > 95%). The patient harbored both pMMR/MSS and *BRAF* V600E mutations—features that are theoretically associated with immune insensitivity and poor prognosis. After failure of first-line conversion therapy, she received tislelizumab-based treatment and achieved 14 months of progression-free survival without any immune-related adverse events. We speculate that the therapeutic response may be primarily attributed to the following mechanisms:

First, recent studies on the tumor microenvironment of *BRAF* V600E-mutated colorectal cancer provide an immunological rationale for the response observed in this case. Bolzacchini et al. (8) conducted gene expression profiling in 89 patients with advanced *BRAF*-mutated colorectal cancer who were immunotherapy-naive and found that 52% of cases exhibited active antitumor immune infiltration, while 42% of metastatic lesions displayed high levels of

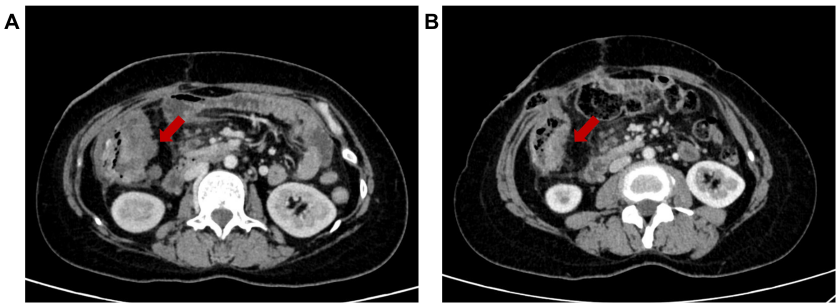

FIGURE 2
Radiological response to tislelizumab-based therapy. Contrast-enhanced CT images of the primary ascending colon tumor **(A)** at baseline (February 2025) and **(B)** at best response (June 2025), demonstrating marked tumor shrinkage consistent with a partial response. Arrows indicate the target lesion.

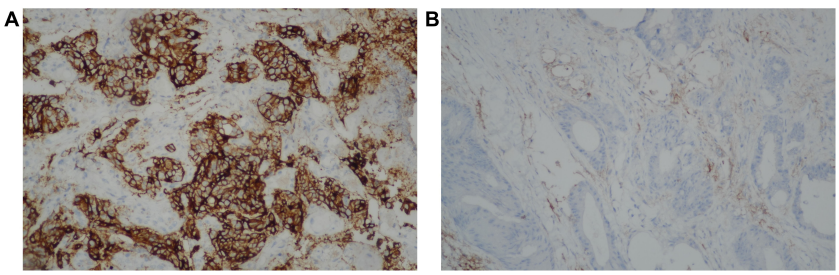

FIGURE 3
PD-L1 expression in the primary tumor at baseline and at disease progression. **(A)** At diagnosis (August 2024), PD-L1 immunohistochemistry (SP263 antibody, VENTANA BenchMark XT platform) revealed extremely high expression with a tumor proportion score (TPS > 95%). **(B)** Re-biopsy of the primary tumor at progression (April 2026; same assay platform) showed markedly decreased PD-L1 expression (TPS 5%). Magnification, ×200.

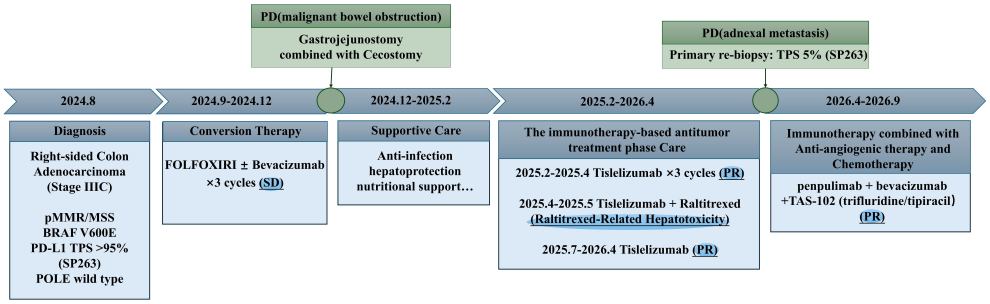

FIGURE 4
Timeline of the therapeutic course and clinical outcomes. The arrows indicate the sequence of treatments and key events from diagnosis to the latest follow-up. PD, progressive disease; PR, partial response; SD, stable disease.

tumor-inflammation features, reflecting a robust adaptive immune response. Cen et al. (9) reported that *BRAF*-mutated colon cancers demonstrate greater immune cell infiltration, lower tumor purity, and more pronounced expression of immune checkpoints such as PD-1, PD-L1, CTLA-4, LAG-3, and TIM-3 compared to wild-type tumors. Moreover, in the METIMMOX study (5), although the alternating regimen of chemotherapy plus nivolumab did not improve overall efficacy in patients with advanced MSS colorectal cancer, all three patients with *BRAF* mutations achieved a complete response, with PFS ranging from 20.7 to 35.0 months. Furthermore, Morris et al. (10) treated 26 patients with MSS, BRAF V600E-mutant metastatic colorectal cancer with encorafenib combined with cetuximab and nivolumab, achieving an objective response rate of 50% and a median progression-free survival of 7.4 months. Notably, exploratory transcriptomic analysis indicated that responders were enriched for immune activation signatures at baseline. Taken together, the above evidence suggests that BRAF V600E-mutated pMMR/MSS colorectal cancer is not uniformly immunoresistant, and these features may serve as a basis for identifying patients who could benefit from immunotherapy.

Second, in addition to harboring the *BRAF* V600E mutation, this patient had another rare immunomarker feature: a baseline PD-L1 TPS exceeding 95%. A high TPS suggests an active PD-1/PD-L1 immune-suppressive axis within the tumor microenvironment, providing a biological basis for PD-1 inhibitors to reverse T-cell inhibition and restore antitumor immunity (11). In the context of the *BRAF* V600E mutation, PD-L1 can be constitutively upregulated through transcription factors downstream of the MAPK pathway, such as c-JUN/YAP and LEF-1; however, whether such tumor-intrinsic PD-L1 expression can predict benefit from immunotherapy remains unclear (12). Notably, re-biopsy of the primary lesion at disease progression revealed that the PD-L1 TPS had decreased to 5%. This dynamic change suggests that the extremely high baseline PD-L1 expression was not fixed by the oncogenic program but rather represents adaptive expression under immune pressure. Thus, despite the MSS phenotype, this tumor may have harbored a genuinely pre-activated immune microenvironment. This finding further suggests a possible dose–response relationship between PD-L1 expression level and the efficacy of immunotherapy, which merits further investigation.

Additionally, the patient had previously received a conversion therapy regimen containing oxaliplatin and short-term combination therapy with raltitrexed. These chemotherapeutic agents may promote the transformation of "cold" tumors into "hot" tumors by inducing immunogenic cell death and enhancing CD8+ T-cell infiltration, thereby potentiating the antitumor effects of ICIs (13, 14). In this case, however, the patient received only two cycles of combination chemotherapy before discontinuation due to hepatotoxicity attributed to raltitrexed; subsequent maintenance with tislelizumab monotherapy sustained the remission, suggesting that the pre-existing state of immune activation may have been a key factor in the observed clinical outcome.

Cases with molecular characteristics similar to this one have been reported in the literature. Fang et al. (6) reported a patient with MSS colorectal adenocarcinoma harboring a *BRAF* V600E mutation and a combined positive score (CPS) of 35 who achieved over 17 months of progression-free survival following treatment with nivolumab combined with bevacizumab. Theodorou et al. (7) reported a case of poorly differentiated adenocarcinoma of the sigmoid colon characterized by a *BRAF* V600E mutation, pMMR/MSS, and a PD-L1 TPS of 80%; after multiple lines of therapy, the patient received a combination of encorafenib, cetuximab, and nivolumab, achieving a PR with a PFS of 15.7 months.

Notably, the regimen used in that case was identical to the triplet evaluated by Morris et al. However, in the subsequent randomized phase II SWOG S2107 trial (15) comparing this triplet with encorafenib plus cetuximab, adding nivolumab did not improve progression-free survival (median 5.8 vs. 6.3 months; hazard ratio, 1.10; P = 0.64) or overall survival (13.5 vs. 11.6 months; P = 0.29). These findings indicate that most unselected patients do not benefit from the addition of immunotherapy. The concomitant high PD-L1 expression in the case reported by Theodorou et al. may thus represent a clinically accessible reference for identifying patients likely to benefit.

Although all the aforementioned cases involved combination therapies, the response in the present case was achieved with monotherapy, suggesting that sensitivity to immunotherapy in patients with high PD-L1 expression, pMMR/MSS, and *BRAF* V600E mutations is not restricted to combination regimens. Identifying which patients in this subtype benefit from immunotherapy, and characterizing their underlying immune microenvironment, warrant further investigation.

The reliability of this report rests on three key aspects. First, MSS status was confirmed using a dual-platform approach combining immunohistochemical staining for four mismatch repair proteins and next-generation sequencing. Second, the temporal relationship

between treatment response and prior therapy was clearly established, with PR occurring before chemotherapy was added and sustained clinical benefit observed after switching to monotherapy, supporting a plausible causal association. Third, the follow-up duration was more than 19 months since the initiation of immunotherapy.

As a single-case report, the generalizability of these findings is inherently limited. Due to resource constraints, comprehensive assessments of *POLD1*, tumor mutational burden (TMB), tumor-infiltrating lymphocytes, gut microbiota, and systemic inflammation markers were not feasible; therefore, the relative contributions of these factors to the observed treatment response cannot be determined.

4 Conclusion

Nonetheless, this case suggests that for patients with *BRAF* V600E-mutated colorectal cancer, PD-L1 expression testing should be routinely considered irrespective of MMR status. If PD-L1 is highly expressed, PD-1/PD-L1 inhibitors may represent a viable personalized treatment option worthy of exploration, even among those with pMMR/MSS tumors. Future prospective, large-scale studies integrating multidimensional biomarkers (e.g., TMB and the gut microbiome) are warranted to precisely identify which patients with pMMR/MSS or BRAF V600E-mutated colorectal cancer are most likely to benefit from immunotherapy.

5 Patient perspective

When I was admitted in August 2024 at the age of 46 with an abdominal mass, I never imagined it would turn out to be colon cancer. After intestinal obstruction and palliative surgery left me bedridden and feeling hopeless, my doctor explained that my tumor expressed particularly high PD-L1 and offered me an immunotherapy option beyond standard treatment. Within months of starting this treatment in February 2025, my strength and weight gradually returned, and follow-up scans showed that the tumor had shrunk. I want others with this disease to know: do not give up, trust your doctors and trust science—even when the guidelines offer no options, there may still be a way forward.

Data availability statement

The original contributions presented in the study are included in the article/supplementary material. Further inquiries can be directed to the corresponding author.

Ethics statement

The studies involving humans were approved by The Second Affiliated Hospital of Shandong First Medical University. The studies were conducted in accordance with the local legislation and institutional requirements. Written informed consent for participation was not required from the participants or the participants' legal guardians/next of kin in accordance with the national legislation and institutional requirements. Written informed consent was obtained from the individual(s) for the publication of any potentially identifiable images or data included in this article.

Author contributions

CL: Conceptualization, Writing – original draft, Data curation, Investigation, Writing – review & editing. ML: Writing – review & editing, Conceptualization, Investigation, Writing – original draft, Supervision. SW: Data curation, Writing – review & editing, Formal Analysis, Validation. HL: Writing – original draft, Writing – review & editing, Conceptualization, Project administration, Supervision. MX: Investigation, Writing – original draft, Data curation.

Funding

The author(s) declared that financial support was not received for this work and/or its publication.

Conflict of interest

The author(s) declared that this work was conducted in the absence of any commercial or financial relationships that could be construed as a potential conflict of interest.

Generative AI statement

The author(s) declared that generative AI was not used in the creation of this manuscript.

Any alternative text (alt text) provided alongside figures in this article has been generated by Frontiers with the support of artificial intelligence and reasonable efforts have been made to ensure accuracy, including review by the authors wherever possible. If you identify any issues, please contact us.

Publisher's note

All claims expressed in this article are solely those of the authors and do not necessarily represent those of their affiliated organizations, or those of the publisher, the editors and the reviewers. Any product that may be evaluated in this article, or claim that may be made by its manufacturer, is not guaranteed or endorsed by the publisher.

References

1. Han B, Zheng R, Zeng H, Wang S, Sun K, Chen R, et al. Cancer incidence and mortality in China, 2022. *J Natl Cancer Cent.* (2024) 4:47–53. doi: 10.1016/j.jncc.2024.01.006

2. André T, Shiu K-K, Kim T, Jensen B, Jensen L, Punt C, et al. Pembrolizumab in microsatellite-instability-high advanced colorectal cancer. *N Engl J Med.* (2020) 383:2207–18. doi: 10.1056/NEJMoa2017699

3. Grothey A, Fakih M, Tabernero J. Management of BRAF-mutant metastatic colorectal cancer: a review of treatment options and evidence-based guidelines. *Ann Oncol.* (2021) 32:959–67. doi: 10.1016/j.annonc.2021.03.206

4. Cremolini C, Loupakis F, Antoniotti C, Lupi C, Sensi E, Lonardi S, et al. FOLFOXIRI plus bevacizumab versus FOLFIRI plus bevacizumab as first-line treatment of patients with metastatic colorectal cancer: updated overall survival and molecular subgroup analyses of the open-label, phase 3 TRIBE study. *Lancet Oncol.* (2015) 16:1306–15. doi: 10.1016/S1470-2045(15)00122-9

5. Ree A, Šaltytė Benth J, Hamre H, Kersten C, Hofsli E, Guren M, et al. First-line oxaliplatin-based chemotherapy and nivolumab for metastatic microsatellite-stable colorectal cancer—the randomised METIMMOX trial. *Br J Cancer.* (2024) 130:1921–8. doi: 10.1038/s41416-024-02696-6

6. Fang C, Lin J, Zhang T, Luo J, Nie D, Li M, et al. Metastatic colorectal cancer patient with microsatellite stability and BRAFV600E mutation showed a complete metabolic response to PD-1 blockade and bevacizumab: a case report. *Front Oncol.* (2021) 11:652394. doi: 10.3389/fonc.2021.652394

7. Theodorou I, Heregger R, Greil R, Weiss L, Huemer F. Successful Encorafenib and Cetuximab re-challenge combined with Nivolumab in BRAF V600E mutated, mismatch-repair-proficient metastatic colorectal cancer – a case report from the AGMT mCRC registry. *Clin Colorectal Cancer.* (2026) 25:297–301. doi: 10.1016/j.clcc.2026.01.004

8. Bolzacchini E, Libera L, Church S, Sahnane N, Bombelli R, Digiacomo N, et al. Tumor antigenicity and a pre-existing adaptive immune response in advanced BRAF mutant colorectal cancers. *Cancers.* (2022) 14:3951. doi: 10.3390/cancers14163951

9. Cen S, Liu K, Zheng Y, Shan J, Jing C, Gao J, et al. BRAF mutation as a potential therapeutic target for checkpoint inhibitors: a comprehensive analysis of immune microenvironment in BRAF mutated colon cancer. *Front Cell Dev Biol.* (2021) 9:705060. doi: 10.3389/fcell.2021.705060

10. Morris V, Parseghian C, Bahrambeigi V, Abdelfattah N, Xiao L, Agrawal A, et al. Phase 1/2 trial of encorafenib, cetuximab, and nivolumab in microsatellite stable BRAFV600E metastatic colorectal cancer. *Cancer Cell.* (2025) 43:2106–18.e3. doi: 10.1016/j.ccell.2025.08.002

11. Borst J, Busselaar J, Bosma D, Ossendorp F. Mechanism of action of PD-1 receptor/ligand targeted cancer immunotherapy. *Eur J Immunol.* (2021) 51:1911–20. doi: 10.1002/eji.202048994

12. Cataldi C, Karaoğlan B, Liotta E, De Dosso S. Decoding immunotherapy response in colorectal cancer: translational insights beyond MSI. *Cancers.* (2026) 18:852. doi: 10.3390/cancers18050852

13. Tesniere A, Schlemmer F, Boige V, Kepp O, Martins I, Ghiringhelli F, et al. Immunogenic death of colon cancer cells treated with oxaliplatin. *Oncogene.* (2010) 29:482–91. doi: 10.1038/onc.2009.356

14. Antoniotti C, Rossini D, Pietrantonio F, Salvatore L, Lonardi S, Tamberi S, et al. Upfront fluorouracil, leucovorin, oxaliplatin, and irinotecan plus bevacizumab with or without atezolizumab for patients with metastatic colorectal cancer: updated and overall survival results of the ATEZOTRIBE study. *J Clin Oncol.* (2024) 42:2637–44. doi: 10.1200/JCO.23.02728

15. Morris V, Colby S, Kopetz S, Guthrie K, Chapin W, Breakstone R, et al. SWOG S2107: Randomized phase II trial of encorafenib and cetuximab with or without nivolumab for patients with previously treated MSS, BRAF V600E metastatic colorectal cancer (mCRC). *J Clin Oncol.* (2026) 44:3504. doi: 10.1200/JCO.2026.44.16_suppl.3504