frontiers in Oncology

TYPE Case Report
PUBLISHED 06 November 2026
DOI 10.3389/fonc.2026.1898019

Check for updates

OPEN ACCESS

EDITED BY
Ioanna Maria Grypari,
University of Ioannina, Greece

REVIEWED BY
Persefoni Margariti,
Institute of Continuing Medical Education of Ioannina, Greece
Liwaa Mahdi,
Faculty of Medicine-University of Kufa, Iraq
Konstantina Kostimpa,
University Hospital of Ioannina, Greece

*CORRESPONDENCE
Li Zhao
15926239912@163.com
Yeming Wang
804995318@qq.com

RECEIVED 04 June 2026
REVISED 10 October 2026
ACCEPTED 15 October 2026
PUBLISHED 06 November 2026

CITATION
Zhao L and Wang Y (2026) Persistence of pulmonary infiltrates despite effective anti-infective therapy as a diagnostic clue for pembrolizumab-induced pneumonitis: a case report. *Front. Oncol.* 16:1898019. doi: 10.3389/fonc.2026.1898019

COPYRIGHT
© 2026 Zhao and Wang. This is an open-access article distributed under the terms of the Creative Commons Attribution License (CC BY). The use, distribution or reproduction in other forums is permitted, provided the original author(s) and the copyright owner(s) are credited and that the original publication in this journal is cited, in accordance with accepted academic practice. No use, distribution or reproduction is permitted which does not comply with these terms.

Persistence of pulmonary infiltrates despite effective anti-infective therapy as a diagnostic clue for pembrolizumab-induced pneumonitis: a case report

Li Zhao* and Yeming Wang*

Department of Intensive Care Medicine, Taikang Tongji (Wuhan) Hospital, Hubei, Wuhan, China

Introduction: Pembrolizumab-based bladder preservation strategies are increasingly applied in invasive high-grade urothelial carcinoma, yet checkpoint inhibitor pneumonitis (CIP) remains an underrecognized, potentially fatal adverse event. Diagnosis can be markedly delayed when concurrent infection is present.

Case presentation: A 63-year-old man with invasive high-grade urothelial carcinoma developed complete tumor response after receiving disitamab vedotin plus pembrolizumab following chemotherapy intolerance. He subsequently presented with urinary tract infection and septic shock. Aggressive anti-infective and hemodynamic support promptly reversed shock and normalized systemic inflammatory markers. Nevertheless, follow-up chest computed tomography demonstrated persistent bilateral ground-glass opacities and consolidation without any improvement. Pre-treatment chest radiography had been normal, positron emission tomography–computed tomography showed marked bilateral pulmonary fluorodeoxyglucose uptake without bladder recurrence, and extensive microbiological workup excluded uncontrolled infection. The dissociation between well-controlled infection and stationary pulmonary lesions, together with typical imaging features, raised strong suspicion of pembrolizumab-induced CIP.

Conclusion: In patients receiving PD-1 inhibitors, persistent pulmonary infiltrates despite effective anti-infective therapy should raise strong suspicion of checkpoint inhibitor pneumonitis and prompt dedicated diagnostic evaluation. This phenotype—the dissociation between resolving systemic infection and stationary lung lesions—may serve as a practical clue to consider CIP earlier, particularly when invasive diagnostic tools are unavailable; however, it is a suggestive rather than confirmatory finding and requires validation in larger cohorts.

KEYWORDS
bladder preservation, checkpoint inhibitor pneumonitis, invasive high-grade urothelial carcinoma, pembrolizumab, septic shock

1 Introduction

Bladder cancer is one of the most common urinary system malignancies worldwide (1). For patients with invasive high-grade urothelial carcinoma (IHGUC) who refuse radical cystectomy or are unfit for surgery, bladder preservation therapy using PD-1 inhibitors plus antibody–drug conjugates (ADCs) has emerged as a promising option, achieving favorable tumor response rates (2). For patients intolerant to chemotherapy, HER2-targeted ADCs such as disitamab vedotin have become an important therapeutic alternative (3).

However, immune checkpoint inhibitors may induce immune-related adverse events (irAEs), among which checkpoint inhibitor pneumonitis (CIP), a specific subtype of immune-mediated lung injury (IMLI), is particularly challenging (4). Its clinical presentation—including cough, dyspnea, and bilateral ground-glass opacities—frequently overlaps with infectious pneumonia, leading to diagnostic delays and unnecessary antimicrobial exposure (5).

We report a patient with IHGUC who developed pembroli zumab-induced CIP during bladder preservation therapy. A distinct diagnostic feature was that after successful anti-infective and anti-shock treatment, pulmonary lesions remained unchanged, strongly supporting CIP rather than infection. This case highlights a potentially useful diagnostic phenotype—persistent pulmonary infiltrates despite effective infection control—that should alert clinicians to consider CIP and to pursue further evaluation, thereby avoiding delays in appropriate management. We present it as a hypothesis-generating observation rather than a validated diagnostic criterion.

2 Case presentation

2.1 Clinical history and baseline treatment

A 63-year-old man was diagnosed with invasive high-grade urothelial carcinoma (IHGUC) following transurethral resection of bladder tumor (TURBT). He refused radical cystectomy. Initial first-line chemotherapy with gemcitabine plus cisplatin was discontinued after one cycle due to intractable grade 3 nausea and vomiting. He subsequently received second-line bladder preservation therapy with disitamab vedotin combined with pembrolizumab, administered every 3 weeks. Complete tumor remission was confirmed by cystoscopy and imaging after four cycles of combination therapy.

2.2 Acute presentation and initial management

Twelve weeks after the first dose of pembrolizumab, the patient presented to the emergency department with a 4-day history of chills, fever (maximum temperature 39.2°C), and progressive hypotension. Initial laboratory tests showed elevated white blood cell count, procalcitonin, and interleukin-6. He was diagnosed with urinary tract infection complicated by septic shock and immediately transferred to the intensive care unit. At admission, the patient reported occasional cough with yellow sputum of small amount, but no dyspnea. Physical examination revealed a respiratory rate of 20 breaths/min. Arterial blood gas analysis showed a PaO_2 of 128 mmHg with an FiO_2 of 50% (PaO_2/FiO_2 ratio of 256 mmHg). An echocardiogram performed on the same day demonstrated a normal left ventricular ejection fraction (LVEF) of 65%, with no significant valvular disease or wall motion abnormalities.

Broad-spectrum antimicrobial therapy (meropenem, linezolid, and voriconazole) was initiated empirically, along with norepinephrine for hemodynamic support, organ protection, and fluid resuscitation, in accordance with the 2021 Surviving Sepsis Campaign guidelines (6).

2.3 Key diagnostic dissociation

Within 72 hours of treatment, the patient demonstrated a rapid and robust systemic response: hemodynamic stability was restored, fever resolved, and vasopressor support was successfully discontinued. By day 7 of antimicrobial therapy, procalcitonin and interleukin-6 had declined by more than 90% from their peak values, and the white blood cell count had normalized, confirming effective eradication of the underlying urinary tract infection. The cumulative fluid balance was +3,413 mL on the first ICU day and -1,941 mL by the second ICU day (with a urine output of 5,361 mL, aided by furosemide 20 mg daily). By day 7, the patient's cough and sputum had significantly improved, and the respiratory rate had decreased to 15 breaths/min. Notably, despite this clinical respiratory improvement and negative fluid balance, the follow-up chest CT performed on day 7 demonstrated no interval change in pulmonary abnormalities compared with admission imaging. This striking dissociation between controlled systemic infection and persistent pulmonary pathology formed the cornerstone of the diagnostic evaluation.

2.4 Imaging and microbiological confirmation

A pre-treatment chest radiograph obtained prior to initiation of immunotherapy was normal, with clear lung fields and no evidence of pre-existing chronic lung disease. Admission chest CT revealed bilateral diffuse ground-glass opacities, prominent peribronchovas cular infiltrates, patchy consolidation, and small bilateral pleural effusions. Admission chest CT revealed bilateral diffuse ground-glass opacities, prominent peribronchovascular infiltrates, patchy consolidation, and small bilateral pleural effusions.

Whole-body positron emission tomography–computed tomography (PET-CT) demonstrated intense, diffuse ^{18}F-FDG uptake throughout both lung parenchyma (maximum standardized uptake value, SUVmax=8.2), consistent with active inflammatory processes. No pathological FDG uptake was identified in the bladder (SUVmax=1.3), confirming sustained complete tumor remission and ruling out metastatic disease. (Figure 1).

Extensive microbiological workup, including three sets of blood cultures obtained before and after antimicrobial initiation, sputum Gram stain and culture, galactomannan assay, and a comprehensive respiratory virus polymerase chain reaction panel, yielded uniformly negative results, excluding ongoing bacterial or fungal pneumonia.

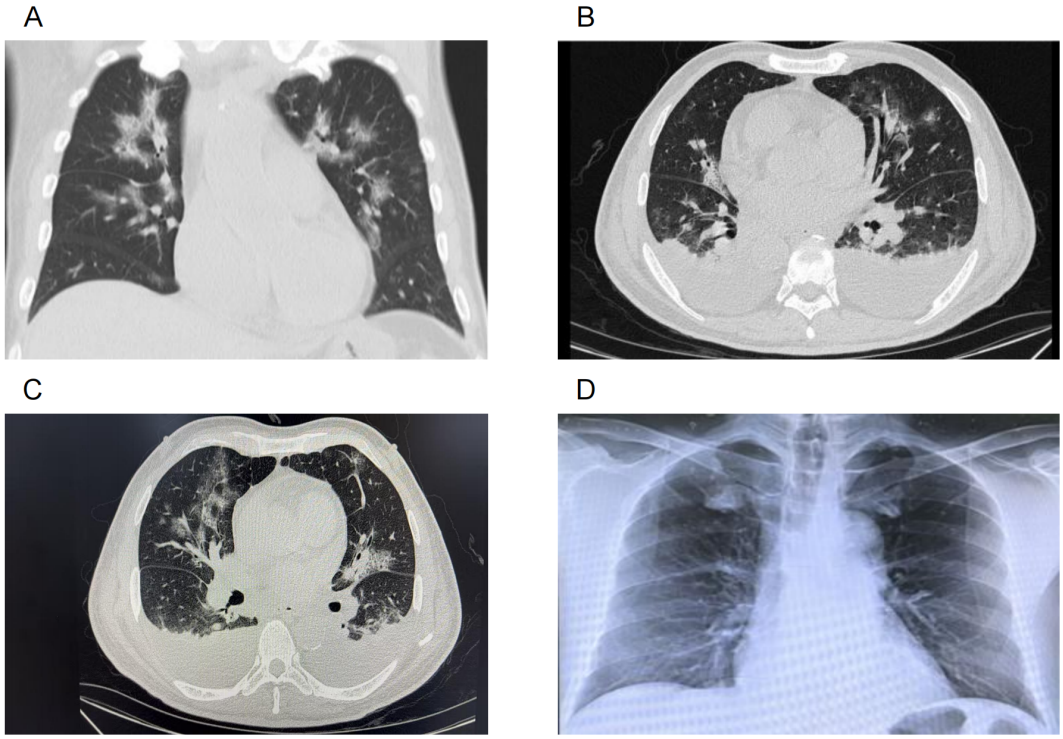

FIGURE 1
Comparison of lung imaging before and after pembrolizumab treatment. **(A)** Coronal chest CT after pembrolizumab treatment, showing bilateral diffuse ground-glass opacities and consolidation. **(B)** Axial chest CT at the upper thorax, demonstrating peribronchovascular patchy infiltrates consistent with immune-mediated lung injury. **(C)** Axial chest CT at the lower thorax in lung window, demonstrating persistent bilateral patchy consolidation and ground-glass opacities despite effective anti-infective therapy and diuresis.These findings are suggestive of, but not diagnostic of, checkpoint inhibitor pneumonitis. **(D)** Pre-treatment chest radiograph showing clear lung fields with no abnormal infiltrates.

The patient was transferred from the intensive care unit to the general ward for continued monitoring and further diagnostic evaluation.

3 Results

3.1 Diagnostic evidence for pembrolizumab-induced checkpoint inhibitor pneumonitis

The most striking feature of this patient's clinical course was a profound dissociation between the rapid resolution of systemic infection and the complete lack of improvement in pulmonary pathology, which formed the cornerstone of the diagnostic evaluation for pembrolizumab-induced checkpoint inhibitor pneumonitis (CIP).

Following initiation of guideline-directed therapy, the patient demonstrated a prompt and robust systemic response to anti-infective treatment. Hemodynamic stability was restored within 48 hours, and all measured inflammatory markers declined by more than 90% from their peak values by day 7: procalcitonin fell from 28.6 ng/mL to 1.2 ng/mL, interleukin-6 from 1245 pg/mL to 87 pg/mL, and white blood cell count from 21.3×10^9/L to 6.8×10^9/L. This rapid normalization of systemic inflammation confirmed that the antimicrobial regimen was highly effective against the underlying urinary tract infection.

In marked contrast to this systemic improvement, serial chest CT imaging showed no evidence of resolution of the pulmonary infiltrates. The bilateral diffuse ground-glass opacities, patchy consolidation, and small pleural effusions observed on admission remained identical in extent and severity on day 7 imaging. This pattern is atypical for bacterial or fungal pneumonia, which usually demonstrates at least partial radiographic improvement within 3-7 days of appropriate antimicrobial therapy. Nevertheless, absence of early radiographic improvement alone does not exclude infection, and other non-infectious causes of lung injury remained in the differential diagnosis. While other differentials—including acute lung injury (ALI) from septic shock, volume overload, or drug toxicity—were considered, several features argued against them: systemic inflammatory markers normalized within 72 hours, cumulative fluid balance became negative, and there was no radiographic regression at Day 7. These findings made resolving sepsis-induced ALI and simple fluid overload less likely, although they could not be excluded with absolute certainty. Furthermore, the patient received no other known pneumotoxic medications besides pembrolizumab and disitamab vedotin, the latter of which has a very low reported incidence (< 2%) of pneumonitis.

The diagnosis of Grade 2 CIP (as per CTCAE v5.0) was made based on the presence of symptoms (cough with sputum) and radiographic findings. Further evidence supporting an immune-

mediated etiology derived from baseline and functional imaging. A pre-treatment chest radiograph obtained prior to pembrolizumab initiation showed clear lung fields without infiltrates, excluding pre-existing chronic lung disease as a contributing factor. Whole-body PET-CT demonstrated intense, diffuse ^{18}F-FDG uptake throughout both lung parenchyma, with a maximum standardized uptake value (SUVmax) of 8.2, consistent with active inflammatory processes. No pathological FDG uptake was identified in the bladder (SUVmax 1.3), confirming sustained complete tumor remission and excluding metastatic disease as a cause of the pulmonary findings.

Extensive microbiological evaluation provided no evidence of ongoing pulmonary infection. Three sets of blood cultures obtained before and after antimicrobial initiation remained negative, as did sputum Gram stain and culture, galactomannan assay, and a comprehensive respiratory virus polymerase chain reaction panel. Additionally, the onset of pulmonary abnormalities occurred 12 weeks after the first dose of pembrolizumab, falling within the well-documented median time window for CIP of 8–12 weeks (range 2–24 weeks) (5).

Taken together, the combination of persistent pulmonary infiltrates despite effective anti-infective therapy, typical radiological and functional imaging features, negative microbiological workup, normal baseline pulmonary status, and compatible temporal relationship with pembrolizumab exposure supported a presumptive diagnosis of pembrolizumab-induced CIP.

3.2 Clinical outcome

Following diagnosis, the patient remained hemodynamically stable without supplemental oxygen requirement. The dry cough and sputum gradually resolved completely. He was discharged from the hospital on day 14. A follow-up chest CT performed 4 weeks after discharge demonstrated a significant reduction in the bilateral ground-glass opacities and consolidation. He continued outpatient follow-up with serial chest imaging to monitor for any recurrence.

4 Discussion

4.1 The pivotal diagnostic clue: dissociation between systemic infection resolution and persistent pulmonary infiltrates

This case illustrates a potentially valuable diagnostic phenotype of pembrolizumab-induced checkpoint inhibitor pneumonitis (CIP): persistent pulmonary infiltrates despite successful control of systemic infection and septic shock. The dissociation between resolved septic shock and stationary lung lesions served as the pivotal clue that redirected the diagnosis from infectious pneumonia toward.

CIP frequently presents with symptoms and imaging findings that overlap substantially with those of infectious pneumonia, making timely differentiation challenging, as highlighted in a 2025 comprehensive radiological review (7). This diagnostic dilemma is compounded when patients develop concurrent infections, as in the present case, where urinary tract infection with septic shock provided a plausible infectious explanation for the patient's acute deterioration. In their seminal multicenter analysis, Naidoo et al. reported an overall incidence of pembrolizumab-induced CIP of approximately 3–5%, with a subset developing severe or fatal disease (5). A meta-analysis by Su et al. further demonstrated that PD-1 inhibitors are associated with a 34% higher risk of all-grade CIP compared with PD-L1 inhibitors (RR 1.34, 95%CI 1.06-1.69), and a trend toward increased grade 3–5 CIP (RR 1.63, 95%CI 0.99-2.69) (8). The nonspecific presentation, combined with this relatively low incidence, contributes to frequent diagnostic delays (4).

The diagnosis in this case was not based on the severity of the pneumonitis (which was Grade 2), but rather on the distinct clinical trajectory: the failure of the lung lesions to regress in parallel with the rapid systemic recovery. This "stationary lung" sign may serve as a practical bedside clue. What distinguishes the present case is the binary nature of this diagnostic dissociation: an infectious pneumonia would be expected to show at least partial radiographic improvement within 3–7 days of appropriate antimicrobial therapy, in parallel with clinical recovery and declining inflammatory markers. The complete lack of such improvement makes infection an unlikely primary driver of the pulmonary pathology, although it does not exclude it definitively. This distinction is important: the proposed sign is intended to prompt consideration of CIP and further workup, not to replace microbiological or histopathological confirmation. This pattern may be particularly useful in resource-limited clinical settings where advanced microbiological investigations and bronchoscopy are not readily available, supporting a presumptive rather than definitive diagnosis based on clinical and radiological trajectories. Therefore, while histopathology remains the gold standard, this clinical phenotype should be regarded as a supportive clue that informs—but does not replace—comprehensive diagnostic evaluation.

4.2 Biological plausibility of this unique phenotype

The biological plausibility of this dissociation stems from the distinct inflammatory pathways involved in infectious pneumonia and CIP. Infectious pneumonia is driven by systemic innate immune activation against pathogens, characterized by elevated circulating proinflammatory cytokines and rapid resolution with antimicrobial therapy.

In contrast, pembrolizumab-induced CIP is mediated by local reactivation of antigen-specific T cells in the lung parenchyma, a process that is unaffected by antibiotics. This compartmentalized inflammation is a hallmark of immune-mediated lung injury (IMLI) and explains why pulmonary lesions persist despite normalization of systemic inflammatory markers. The intense ^{18}F-FDG uptake observed on PET-CT further supports the presence of local active inflammation in the lungs, even in the absence of systemic infection.

The diagnosis was further supported by normal baseline lung imaging, bilateral FDG uptake on PET-CT without tumor recurrence, and negative extensive microbiological workup. The CT

pattern of bilateral ground-glass opacities with patchy consolidation also corresponds to the most commonly reported radiological features of CIP (7, 9).

4.3 Attribution and differential diagnostic uncertainty

Several alternative explanations for the pulmonary findings cannot be fully excluded. First, the patient received both pembrolizumab and disitamab vedotin. Although ADC-related pneumonitis is less common than ICI-related CIP (incidence <2% vs. 3-5% for pembrolizumab) (13), and the incidence of grade ≥3 pneumonitis in the RC48-C014 trial was comparable to pembrolizumab monotherapy (11), a contributory role of disitamab vedotin cannot be definitively ruled out. Second, because bronchoalveolar lavage and transbronchial biopsy were not performed, a partially treated or atypical infection, as well as other non-infectious causes of lung injury, cannot be excluded with absolute certainty despite the extensive negative microbiological workup. Third, the diagnosis of CIP in this case was based on the convergence of clinical, radiological, functional imaging, and microbiological evidence rather than on histopathological confirmation. These limitations should be considered when interpreting the proposed diagnostic clue.

4.4 Clinical implications for practice

This case has several important implications for clinical practice. First, clinicians should maintain a high index of suspicion for CIP in patients receiving PD-1 inhibitors who present with pulmonary infiltrates, even in the setting of concurrent infection. Second, the observation that pulmonary infiltrates persist despite effective anti-infective therapy should trigger consideration of CIP and dedicated diagnostic evaluation rather than reflexive escalation of antimicrobial therapy.

Regarding management, the 2024 ASCO Clinical Practice Guideline emphasizes that diagnosis requires comprehensive exclusion of infection and that systemic corticosteroid therapy should be initiated promptly once CIP is confirmed (10). The complete tumor response achieved with disitamab vedotin plus pembrolizumab is consistent with the phase 3 RC48-C014 trial, which demonstrated superior efficacy of this combination over chemotherapy in advanced urothelial carcinoma (11). Importantly, there is currently no evidence to suggest that combining disitamab vedotin with pembrolizumab synergistically increases the risk of CIP, and the incidence of grade ≥3 pneumonitis in the RC48-C014 trial was comparable to that reported with pembrolizumab monotherapy (11). However, clinicians should remain vigilant regarding the potential for overlapping toxicities when combining these agents. Additionally, we emphasize that even in the absence of bronchoscopy or biopsy—which are often infeasible in critically ill patients—this phenotype of "resolution of sepsis with stationary lung infiltrates" may provide sufficient clinical confidence to promptly initiate corticosteroids, thereby preventing progression to higher-grade pneumonitis, provided that infection has been thoroughly evaluated and other causes considered.

4.5 Limitations

Several limitations should be acknowledged. As a single case report, the generalizability of our findings is limited. The proposed diagnostic sign cannot establish diagnostic accuracy, sensitivity, or specificity for CIP, and its applicability to other cancer types, treatment regimens, and patient populations remains uncertain. Validation in larger, prospectively followed cohorts is required before it can be adopted as a diagnostic criterion. Bronchoalveolar lavage and transbronchial biopsy were not performed due to the patient's critical condition and the clinical equipoise regarding the risk-benefit ratio, which would have provided additional evidence to further exclude infection and characterize the inflammatory profile of the lung lesions (12).However, we believe the combination of negative extensive microbiological workup, PET-CT findings, and the clinical phenotype described herein provides reasonable supportive evidence for a presumptive diagnosis, while acknowledging that confirmatory invasive testing was not feasible. The contribution of disitamab vedotin to pulmonary toxicity cannot be definitively excluded. Although overall ADC-related pneumonitis is significantly less common than ICI-related CIP (incidence <2% vs. 3–5% for pembrolizumab) (13), HER2-targeted ADCs have been associated with a slightly higher risk of pulmonary toxicity compared with other ADC classes.

5 Conclusion

Pembrolizumab-induced CIP should be suspected when pulmonary infiltrates persist despite effective anti-infective therapy in patients receiving PD-1 inhibitors. This case suggests that the dissociation between well-controlled systemic infection and stationary lung lesions may serve as a practical diagnostic clue, particularly when concurrent infection obscures the clinical picture. Recognition of this phenotype may facilitate earlier consideration of CIP and timely management; however, it should be interpreted as a supportive rather than definitive finding, and prospective validation is warranted.

Data availability statement

The datasets presented in this article are not readily available because the datasets used and analyzed during the current study available from the corresponding author on reasonable request. Requests to access the datasets should be directed to 15926239912@163.com.

Ethics statement

This study was approved by the Ethics Committee of Taikang Tongji (Wuhan) Hospital (Approve No.: TKTJ-IRB202603201). Informed consent was obtained from the patient. All methods were carried out in accordance with Declaration of Helsinki. The authors confirm that this case report adheres to the CARE (CAse REport) Guidelines. Furthermore, the patient has given written informed consent for the publication of their case details and any associated material. The studies were conducted in accordance with the local legislation and institutional requirements. The participants provided their written informed consent to participate in this study. Written informed consent was obtained from the individual(s) for the publication of any potentially identifiable images or data included in this article.

Author contributions

LZ: Formal analysis, Methodology, Writing – original draft, Writing – review & editing. YW: Data curation, Formal analysis, Writing – original draft, Writing – review & editing.

Funding

The author(s) declared that financial support was not received for this work and/or its publication.

Conflict of interest

The author(s) declared that this work was conducted in the absence of any commercial or financial relationships that could be construed as a potential conflict of interest.

Generative AI statement

The author(s) declared that generative AI was not used in the creation of this manuscript.

Any alternative text (alt text) provided alongside figures in this article has been generated by Frontiers with the support of artificial intelligence and reasonable efforts have been made to ensure accuracy, including review by the authors wherever possible. If you identify any issues, please contact us.

Publisher's note

All claims expressed in this article are solely those of the authors and do not necessarily represent those of their affiliated organizations, or those of the publisher, the editors and the reviewers. Any product that may be evaluated in this article, or claim that may be made by its manufacturer, is not guaranteed or endorsed by the publisher.

References

1. Sung H, Ferlay J, Siegel RL, Laversanne M, Soerjomataram I, Jemal A, et al. Global cancer statistics 2020: GLOBOCAN estimates of incidence and mortality worldwide for 36 cancers in 180 countries. *CA Cancer J Clin*. (2021) 71:209–49. doi: 10.3322/caac.21660

2. Witjes JA, Bruins HM, Carrión A, Cathomas R, Compérat E, Efstathiou JA, et al. European Association of Urology Guidelines on muscle-invasive and metastatic bladder cancer: summary of the 2023 guidelines. *Eur Urol*. (2024) 85:17–31. doi: 10.1016/j.eururo.2023.08.016

3. Sheng X, Yan X, Li Y, Lian B, Cui C, Chi Z. Disitamab vedotin in patients with HER2-overexpressing locally advanced or metastatic urothelial carcinoma (RC48-C005): a single-arm, multicentre, phase 2 trial. *Lancet Oncol*. (2021) 22:1729–39. doi: 10.1016/S1470-2045(21)00515-7

4. Postow MA, Sidlow R, Hellmann MD. Immune-related adverse events associated with immune checkpoint blockade. *N Engl J Med*. (2018) 378:158–68. doi: 10.1056/NEJMra1703481

5. Naidoo J, Wang X, Woo KM, Iyriboz T, Halpenny D, Cunningham J, et al. Pneumonitis in patients treated with anti-programmed death-1/programmed death ligand 1 therapy. *J Clin Oncol*. (2017) 35:709–17. doi: 10.1200/JCO.2016.68.2005

6. Evans L, Rhodes A, Alhazzani W, Antonelli M, Coopersmith CM, French C, et al. Surviving sepsis campaign: international guidelines for management of sepsis and septic shock 2021. *Intensive Care Med*. (2021) 47:1181–247. doi: 10.1007/s00134-021-06506-y

7. Nishino M, Hatabu H, Hodi FS. Imaging of Cancer Immunotherapy: Current Approaches and Future Directions. *Radiology*. (2019) 290:9–22. doi: 10.1148/radiol.2018181349

8. Su Q, Zhu EC, Wu JB, et al. Risk of pneumonitis and pneumonia associated with immune checkpoint inhibitors for solid tumors: a systematic review and meta-analysis. *Front Immunol*. (2019) 10:108. doi: 10.3389/fimmu.2019.00108

9. Nishino M, Ramaiya NH, Awad MM, Sholl LM, Maattala JA, Taibi M, et al. PD-1 inhibitor-related pneumonitis in advanced cancer patients: radiographic patterns and clinical course. *Clin Cancer Res*. (2016) 22:6051–60. doi: 10.1158/1078-0432.CCR-16-1320

10. Brahmer JR, Lacchetti C, Schneider BJ, Atkins MB, Brassil KJ, Caterino JM, et al. Management of immune-related adverse events in patients treated with immune checkpoint inhibitor therapy: ASCO clinical practice guideline update. *J Clin Oncol*. (2024) 42:1742–66. doi: 10.1200/JCO.23.02386

11. Zhou L, Yang KW, Zhang S, Yan XQ, Li SM, Xu HY, et al. Disitamab vedotin plus toripalimab in patients with locally advanced or metastatic urothelial carcinoma (RC48-C014): a phase Ib/II dose-escalation and dose-expansion study. *Ann Oncol*. (2025) 36:331–9. doi: 10.1016/j.annonc.2024.12.002

12. Shivakumar S, Parakh S, Vukelic N, Atashrazm F, Naranbhai V, Goh NSL, et al. Utility of bronchoalveolar lavage in checkpoint inhibitor pneumonitis evaluation: a narrative review. *Transl Lung Cancer Res*. (2025) 14:4628–37. doi: 10.21037/tlcr-2025-430

13. Hackshaw MD, Danysh HE, Singh J, Ritchey ME, Cumberland K, Breeze J, et al. A systematic review and meta-analysis of the incidence of pneumonitis in patients receiving antibody-drug conjugates. *Lung Cancer*. (2021) 158:143–50. doi: 10.1016/j.lungcan.2021.06.011