The Egyptian Heart Journal

CASE REPORT

Open Access

ECMO-assisted valve-in-valve transcatheter aortic valve replacement following surgical aortic valve replacement failure in triple-positive antiphospholipid syndrome and systemic lupus erythematosus-associated libman-sacks endocarditis: a case report

Nawras Ibrahim[1*], Abboud Batri[1], Stephanie Ammari[1] and Hiba Fala[1]

Abstract

Background Libman-Sacks endocarditis (LSE) is a non-infective valvular manifestation of systemic lupus erythematosus (SLE) and antiphospholipid syndrome (APS), affecting 15–30% of patients with APS. Characterized by sterile vegetations predisposing to thromboembolism and valvular dysfunction, optimal anticoagulation and intervention strategies remain challenging, particularly with rapid prosthetic failure.

Case presentation A 63-year-old African American man with a 20-year history of SLE and triple-positive APS presented with cardiogenic shock five months after surgical aortic valve replacement (SAVR) for LSE. Echocardiography revealed severe bioprosthetic obstruction (mean gradient 79.6 mmHg, valve area 0.30 cm^2). Given prohibitive redo surgical risk (STS-PROM 18.2%), he underwent ECMO-assisted valve-in-valve transcatheter aortic valve replacement (TAVR) with a 26 mm Edwards SAPIEN 3 valve. Left ventricular ejection fraction improved from 25-29% to 55-59% at 4.5 months, sustained at 50-54% at 8-month follow-up. He remained stable on warfarin (INR 2-3), hydroxychloroquine, and rituximab under multidisciplinary care.

Discussion This case demonstrates diagnostic challenges differentiating LSE from bioprosthetic valve thrombosis (BPVT); a competing diagnosis that could not be excluded without histopathologic confirmation, critical limitations of DOACs in triple-positive APS, and feasibility of ECMO-supported TAVR as an exceptional rescue strategy. Rituximab was administered for refractory APS, though its independent contribution to the favorable outcome cannot be determined.

*Correspondence:
Nawras Ibrahim
nawras.ibrahim@hcahealthcare.com

Full list of author information is available at the end of the article

© The Author(s) 2026. **Open Access** This article is licensed under a Creative Commons Attribution 4.0 International License, which permits use, sharing, adaptation, distribution and reproduction in any medium or format, as long as you give appropriate credit to the original author(s) and the source, provide a link to the Creative Commons licence, and indicate if changes were made. The images or other third party material in this article are included in the article's Creative Commons licence, unless indicated otherwise in a credit line to the material. If material is not included in the article's Creative Commons licence and your intended use is not permitted by statutory regulation or exceeds the permitted use, you will need to obtain permission directly from the copyright holder. To view a copy of this licence, visit http://creativecommons.org/licenses/by/4.0/.

Conclusion To our knowledge, this is the first reported ECMO-assisted valve-in-valve TAVR following SAVR failure in APS/SLE-associated LSE. It emphasizes multidisciplinary care, warfarin-based anticoagulation, immunosuppression escalation, and long-term surveillance for complex autoimmune valvular disease.

Keywords Libman-Sacks endocarditis, Antiphospholipid syndrome, Systemic lupus erythematosus, Transcatheter aortic valve replacement, Extracorporeal membrane oxygenation, Anticoagulation, Rituximab, Case report

Introduction

Libman-Sacks endocarditis (LSE) represents a hallmark valvular complication of systemic lupus erythematosus (SLE) and antiphospholipid syndrome (APS). Between 15% and 30% of patients with APS develop valvular heart disease, known as LSE or non-bacterial thrombotic endocarditis (NBTE). A retrospective cohort study found that 15% of APS patients undergoing echocardiography had NBTE, with prevalence significantly higher in triple-positive patients (27.0%) compared to single-positive disease (5.7%, $p < 0.001$) [1].

The international consensus statement defines antiphospholipid antibody (aPL)-associated cardiac valve disease as valve thickness > 3 mm, localized thickening of the proximal or middle portion of valve leaflets, irregular nodules on the atrial aspect of the mitral valve or vascular surface of the aortic valve, and/or moderate-to-severe valvular regurgitation or stenosis [2]. Histologically, LSE lesions are small (up to 3–4 mm), sterile, fibrinous vegetations with varying fibroblastic organization, neovascularization, and mononuclear inflammatory cell infiltration [3].

Anticoagulation poses significant challenges in triple-positive APS. The TRAPS trial was terminated early due to excess thromboembolic events with rivaroxaban versus warfarin in triple-positive APS (12% vs. 0%; HR 7.4, 95% CI 1.7–32.9; $p = 0.008$) [4]. A meta-analysis confirmed DOACs were associated with increased arterial thrombotic events versus warfarin (OR 5.43, 95% CI 1.87–15.75), primarily driven by excess stroke risk (OR 10.74, 95% CI 2.29–50.38). Current guidelines recommend against DOACs in triple-positive APS, with warfarin (INR 2–3) remaining first-line therapy [5].

Valve-in-valve TAVR demonstrates lower major bleeding (OR 0.36, 95% CI 0.16–0.83; $p = 0.02$), stroke (OR 0.65, 95% CI 0.52–0.81; $p = 0.0001$), and 30-day mortality (OR 0.58, 95% CI 0.45–0.74; $p < 0.0001$) versus redo-SAVR [6]. However, late mortality divergence occurs, with valve-in-valve TAVR showing increased mortality versus redo-SAVR beyond 6 months (HR 1.92, 95% CI 1.58–2.33; $p < 0.001$) [7].

We report a case of LSE in triple-positive APS/SLE managed with sequential SAVR and ECMO-assisted valve-in-valve TAVR, highlighting the challenges of rapid bioprosthetic failure and the role of combined interventional and immunosuppressive therapy.

Case presentation

A 63-year-old African American man with hypertension, hyperlipidemia, type 2 diabetes mellitus, and chronic kidney disease stage III (baseline creatinine 1.5–1.9 mg/dL) had a 20-year history of autoimmune disease. Family history was non-contributory for autoimmune or thrombotic disease. Psycho-social history was unremarkable.

APS was diagnosed in 2011 following persistently elevated anticardiolipin IgG and β2-glycoprotein I antibodies (> 3× upper limit of normal), confirmed after unprovoked deep vein thrombosis in 2006. SLE was supported by positive double-stranded DNA antibodies and hypocomplementemia (C4 14 mg/dL, reference range 16–47 mg/dL).

Serologic findings demonstrated triple-positive APS with persistently elevated antibodies over 13 years (Table 1). Anticoagulation evolved from warfarin to rivaroxaban in 2013 for dietary compliance concerns. Hydroxychloroquine 400 mg daily was maintained throughout.

Clinical findings and timeline

January 2025: Routine transthoracic echocardiography revealed LVEF 55–60%, mild aortic regurgitation, and valve thickening. Transesophageal echocardiography confirmed vegetations on all cusps (largest 0.9 × 0.5 cm on right coronary cusp) with moderate regurgitation Fig. 1.

Diagnostic challenge: differentiating LSE from infective endocarditis

Evidence against infective endocarditis: Blood cultures negative (×2); no fever or systemic symptoms; normal inflammatory markers (ESR 12 mm/hr, CRP 0.4 mg/dL); did not meet Duke criteria (0 major, 1 minor criterion).

Evidence for Libman-Sacks endocarditis: Triple-positive APS (anticardiolipin IgG 138 GPL, β2-GP1 IgG > 150 SGU, lupus anticoagulant positive); SLE with hypocomplementemia (C4 14 mg/dL); vegetations on vascular surface of aortic valve (characteristic location); subsequent histopathology: sterile vegetations with fibrin/immune deposits [3].

Diagnostic certainty: Definite LSE.

February 2025: Elective SAVR with 27 mm Edwards Inspiris Resilia bioprosthetic valve and left atrial appendage exclusion was performed. Histopathology confirmed sterile vegetations with fibrinous material, mononuclear

Table 1 Serologic Evolution of Triple-Positive APS (2011–2025)

Date	Anticardiolipin IgG (GPL)	β2-GP1 IgG (SGU)	β2-GP1 IgA (SGU)	Lupus Anticoagulant	dsDNA (IU/mL)	C3 (mg/dL)	C4 (mg/dL)
2011	112 (> 40 positive)	> 150 (> 20 positive)	78 (> 20 positive)	Positive	45	98	18
2013	125	> 150	82	Positive	38	102	16
2024	147	> 150	75	Positive	52	95	14
2025 (Jan)	138	> 150	80	Positive	48	97	14

Abbreviations: APS, antiphospholipid syndrome; GPL, IgG phospholipid units; SGU, standard IgG units; β2-GP1, β2-glycoprotein I; dsDNA, double-stranded DNA. Reference ranges: Anticardiolipin IgG < 15 GPL negative, 15–40 GPL low-moderate positive, > 40 GPL high positive; β2-GP1 IgG/IgA < 20 SGU negative, > 20 SGU positive; C3 90–180 mg/dL; C4 16–47 mg/dL. Interpretation: Triple-positive APS with persistently elevated antibodies over 13 years, conferring highest thrombotic risk [1]

inflammatory infiltrates, and absence of bacterial organisms, consistent with LSE [3]. Postoperative LVEF was 50–54%. Warfarin (target INR 2–3) and hydroxychloroquine 400 mg daily were restarted. Patient was discharged on postoperative day 7 in stable condition Fig. 2.

June 2025: Despite counseling regarding the increased thrombotic risk associated with DOACs in triple-positive APS, the patient elected to resume rivaroxaban (20 mg daily) in April 2025 due to lifestyle preference, citing difficulty maintaining dietary consistency for stable INR control. Two months later, bilateral lower extremity arterial thromboses emerged with claudication and rest pain. Imaging revealed right popliteal artery occlusion and left common femoral artery cutoff. Bilateral thrombectomy was performed, confirming DOAC failure in triple-positive APS consistent with existing evidence, and prompting immediate, permanent transition to warfarin (target INR 2–3) [3, 4].

July 2025: Five months post-SAVR, progressive dyspnea (NYHA class IV) developed over 2 weeks with acute kidney injury (creatinine 2.8 mg/dL, baseline 1.7 mg/dL) and BNP 2437 pg/mL (reference < 100 pg/mL). Echocardiography showed LVEF 35–39%, severe bioprosthetic stenosis (mean gradient 68 mmHg, valve area 0.36 cm^2), and moderate mitral regurgitation. Transesophageal echocardiography revealed thickened, immobile bioprosthetic leaflets consistent with either recurrent LSE or bioprosthetic valve thrombosis (BPVT); Fig. 3a strong competing diagnosis given the patient's recent rivaroxaban use (contraindicated in triple-positive APS) and the predominantly stenotic pattern. 4D CT, recommended (Class IIa, 2020 ACC/AHA) for distinguishing BPVT from other etiologies, was not performed due to hemodynamic instability [8]. A trial of intensified anticoagulation, which resolves BPVT in ~ 75% of cases, was precluded by cardiogenic shock [9]. Without histopathologic examination of the prosthetic valve (not explanted during valve-in-valve TAVR), the definitive etiology cannot be established.

Patient progressed to cardiogenic shock (blood pressure 88/53 mmHg, heart rate 118 bpm) requiring vasopressor support (norepinephrine 0.08 mcg/kg/min) and cardiorenal syndrome (GFR 24.6 mL/min/1.73 m^2). ICU transfer was required. Repeat echocardiography demonstrated LVEF 25–29%, severe bioprosthetic stenosis (peak velocity 5.4 m/s, mean gradient 79.6 mmHg, valve area 0.30 cm^2), and moderate-severe mitral regurgitation (Table 2). STS-PROM score for redo-SAVR was 18.2% (prohibitive surgical risk).

Therapeutic intervention

Given prohibitive redo surgical risk, ECMO-assisted transfemoral valve-in-valve TAVR was performed on July, 2025. Venoarterial ECMO was established prophylactically via left femoral vessels (arterial cannula 17Fr, venous cannula 21Fr) with flow rates of 3.5–4.0 L/min prior to valve deployment. A 26 mm Edwards SAPIEN 3 Resilia valve was deployed within the degenerated bioprosthesis under fluoroscopic and transesophageal echocardiographic guidance. Post-procedural echocardiography confirmed well-seated valve without paravalvular leak or coronary obstruction. ECMO was weaned and decannulated 4 h post-procedure. Patient was extubated on postoperative day 1 and transferred out of ICU on postoperative day 3.

Given rapid bioprosthetic failure (5 months), immunosuppression was escalated. Leflunomide 20 mg daily was initiated at hospital discharge. Mycophenolate mofetil 1000 mg twice daily was added six weeks post-TAVR. Rituximab 1000 mg was administered on two occasions (September 2025 and October 2025, separated by 2 weeks) for refractory APS with cardiac manifestations. The 1000 mg × 2 fixed-dose protocol was selected over the 375 mg/m^2 × 4 regimen based on institutional protocol, infusion scheduling feasibility, and the patient's renal function (CKD stage III), consistent with the rheumatoid arthritis-derived dosing commonly adapted for APS. While the multicenter Israeli experience reported higher complete response rates with the 375 mg/m^2 × 4 protocol (100% vs. 65%, $p = 0.01$), this comparison was limited by small sample size and retrospective design, and both regimens demonstrated clinical benefit [10].

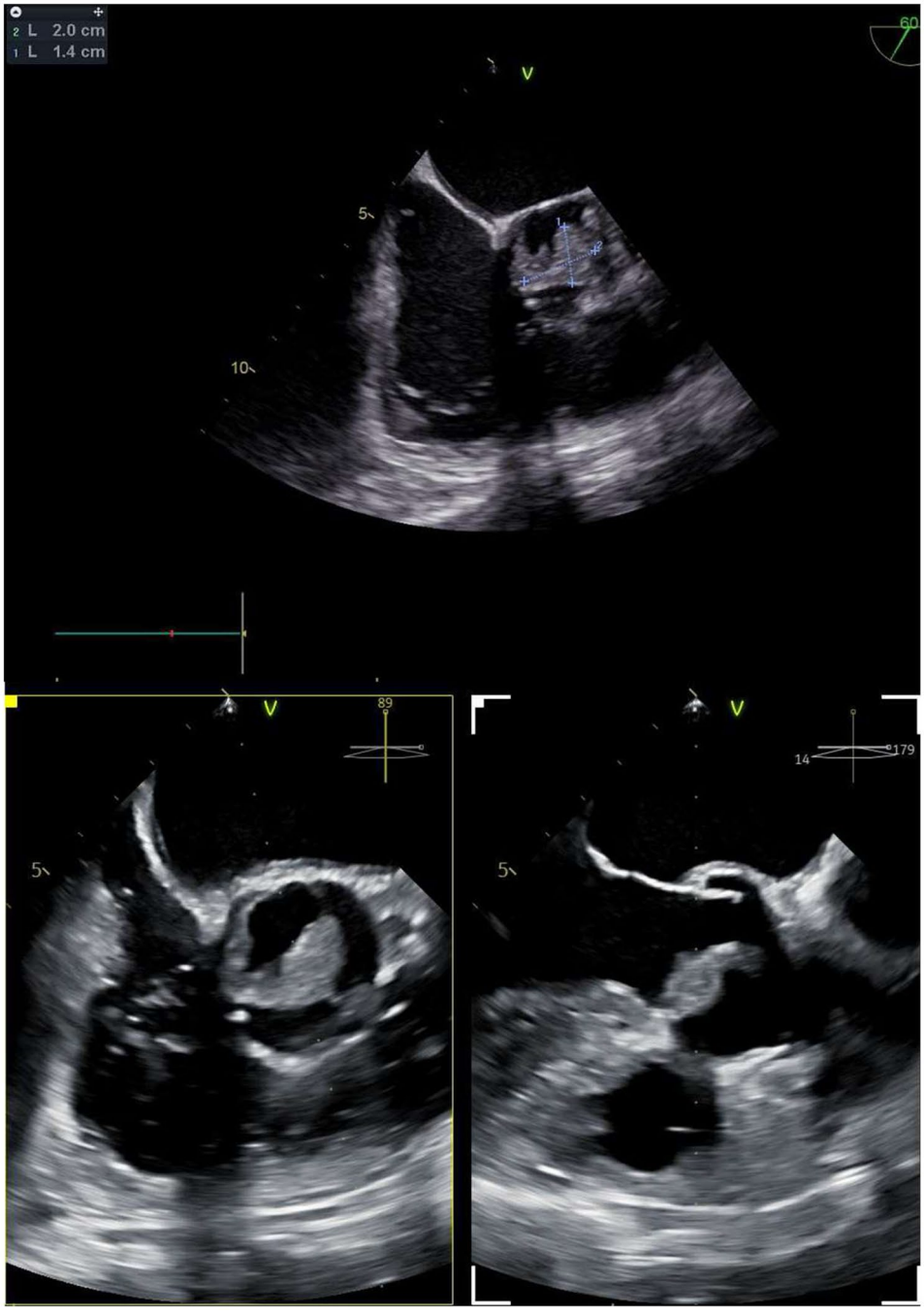

Fig. 1 Libman-Sacks Endocarditis Diagnosis. TEE biplane (short-axis + long-axis) + Intraoperative TEE with caliper measurements

Follow-up and outcomes

August 2025 (1-month follow-up): Echocardiography showed LVEF 40–44%, peak aortic velocity 2.5 m/s, mean gradient 15 mmHg, and valve area 1.27 cm^2. Creatinine improved to 2.1 mg/dL. BNP decreased to 485 pg/mL. Patient was ambulatory with NYHA class II symptoms. INR therapeutic at 2.4 Fig. 4.

March 2026 (8-month follow-up): Echocardiography demonstrated dramatic improvement: LVEF 50–54%, peak aortic velocity 2 m/s, mean gradient 12 mmHg, and valve area 1.51 cm^2 (Table 2), with improved right ventricular function (TAPSE 1.5 cm, reference > 1.6 cm), warranting ongoing surveillance. Creatinine stabilized at 1.8 mg/dL. BNP normalized to 92 pg/mL. Patient was asymptomatic (NYHA class I) and resumed activities of daily living. Antiphospholipid antibody titers remained elevated (anticardiolipin IgG 125 GPL, β2-GP1 IgG > 150 SGU) despite rituximab therapy. Patient remained stable

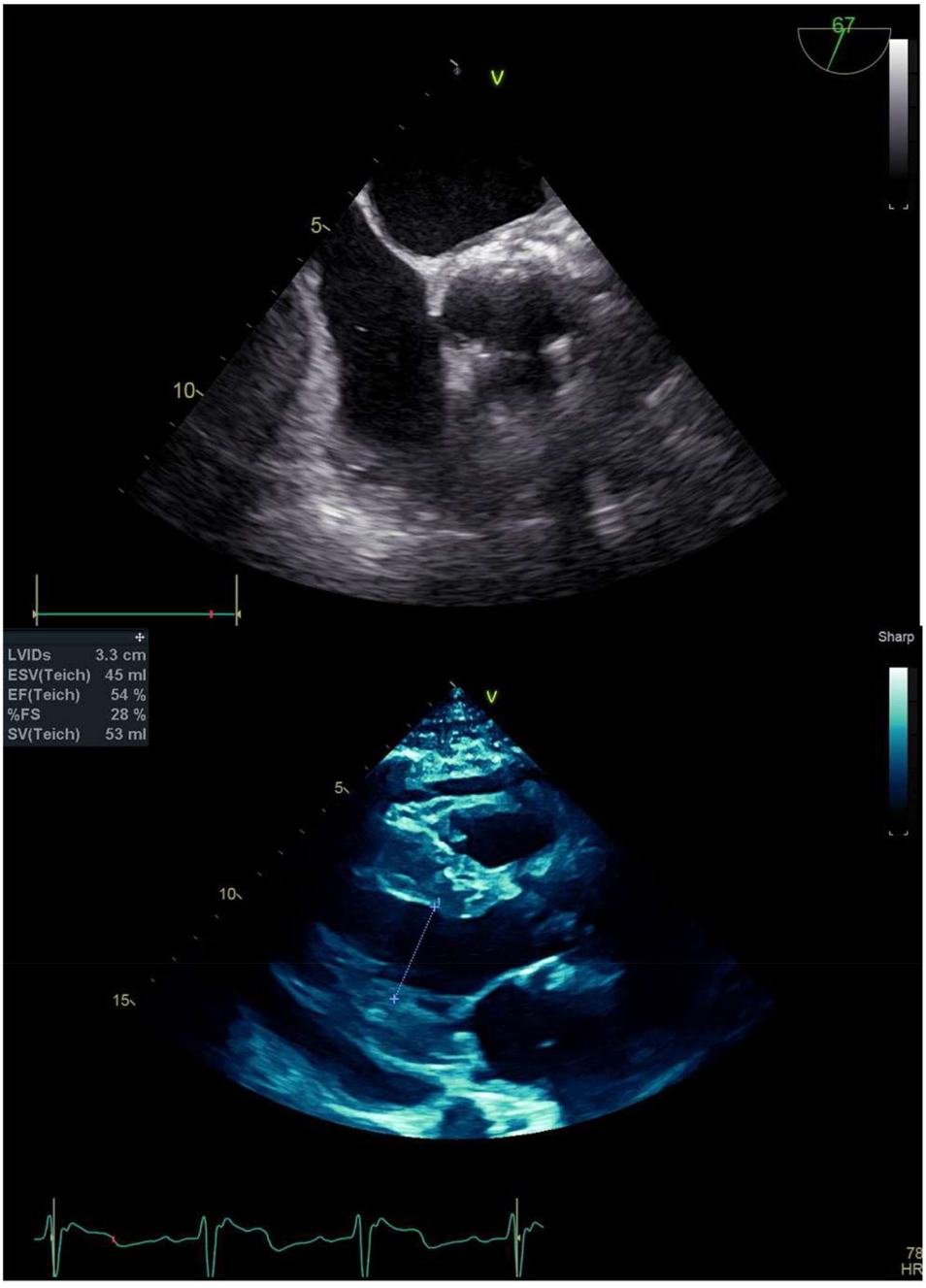

Fig. 2 Surgical aortic valve replacement and early recovery. Upper: Intraoperative TEE post-implantation of 27 mm Edwards Inspiris Resilia bioprosthesis. Lower: Post-operative TTE (day 4) with LVEF 54%, LVIDs 3.3 cm

on warfarin (INR 2.5), hydroxychloroquine 400 mg daily, leflunomide 20 mg daily, and mycophenolate mofetil 1000 mg twice daily under multidisciplinary care (rheumatology, cardiology, nephrology).

Discussion

Diagnostic challenges

LSE presents insidiously, with vegetations often detected on routine echocardiography. Differentiation from infective endocarditis relies on negative cultures, absent fever/systemic signs, positive autoimmune serologies, and characteristic echocardiographic features (vegetations on vascular surface of aortic valve or atrial aspect of mitral valve). Histologic confirmation of sterile vegetations solidifies the diagnosis. Patients with moderate-to-severe valve dysfunction have 3–4 times higher rates of progression to symptomatic disease, valve surgery, stroke, or death [3].

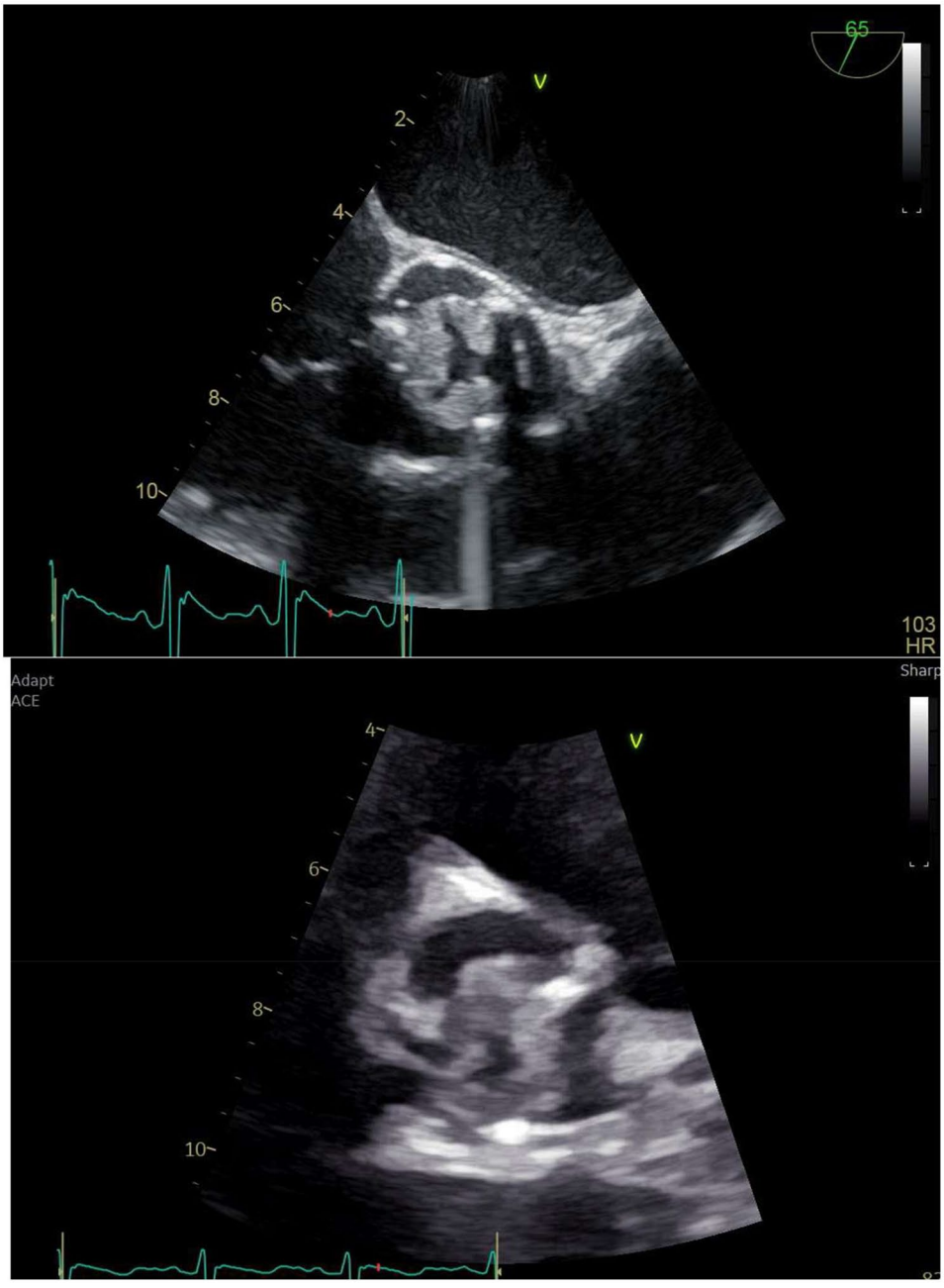

Fig. 3 Rapid bioprosthetic valve failure (5 Months Post-SAVR). Upper: TEE showing bioprosthetic valve dysfunction with thickened leaflets. Lower: TTE showing severe bioprosthetic stenosis

Notably, the etiology of rapid prosthetic valve obstruction at 5 months remains uncertain. BPVT is a major competing diagnosis: the patient was receiving rivaroxaban rather than warfarin, the stenotic pattern with immobile leaflets is more typical of thrombotic obstruction than classic LSE (which predominantly causes regurgitation), and in the largest BPVT cohort, antiphospholipid syndrome was specifically identified in patients with combined fresh and old thrombus, with prothrombotic state independently predicting valve re-replacement (HR 4.5; $p = 0.009$) [9]. A mixed pathology — thrombosis superimposed on autoimmune-inflammatory changes — is biologically plausible given the overlapping mechanisms in APS. We therefore present recurrent LSE as probable rather than definitive.

Anticoagulation management

This case exemplifies DOAC failure in triple-positive APS. The patient's arterial thromboses on rivaroxaban align with the TRAPS trial and meta-analytic data

Table 2 Serial echocardiographic and hemodynamic parameters

Parameter	Jan 2025 (Baseline)	Feb 2025 (Post-SAVR)	Jul 2025 (BVD)	Aug 2025 (Post-TAVR)	Dec 2025 (4.5 mo)	Mar 2026 (8 mo)
LVEF (%)	55–60	50–54	25–29	40–44	55–59	50–54
Peak AV velocity (m/s)	N/A	Normal	5.4	2.5	1.7	2.0
Mean AV gradient (mmHg)	N/A	Normal	79.6	15	7	12
AVA (cm^2)	N/A	Normal	0.30	1.27	1.07	1.51
TAPSE (cm)	N/A	N/A	N/A	N/A	1.1	1.5
MR	Mild	Mild	Mod-Severe	Mild	Mild	Mild
Clinical Status	LSE diagnosed	Post-SAVR	Cardiogenic shock	Recovering	Stable	Stable

Abbreviations: LVEF, left ventricular ejection fraction; AV, aortic valve; AVA, aortic valve area; TAPSE, tricuspid annular plane systolic excursion; MR, mitral regurgitation; LSE, Libman-Sacks endocarditis; SAVR, surgical aortic valve replacement; BVD, bioprosthetic valve dysfunction; TAVR, transcatheter aortic valve replacement

detailed above, confirming DOAC failure in triple-positive APS [4, 5].

Clinical implication: Warfarin (INR 2–3) is mandatory in triple-positive APS. DOACs should not be used. Hydroxychloroquine provides additional antithrombotic benefit through platelet activation inhibition and has been shown to reduce thrombosis incidence in a pilot randomized trial [11].

Valvular interventions

Rapid prosthetic obstruction within five months reflects aggressive autoimmune-thrombotic overlap. Valve-in-valve TAVR proved life-saving in cardiogenic shock, with short-term advantages over redo-SAVR in bleeding, stroke, and 30-day mortality as detailed above [6]. However, late mortality divergence occurs beyond 6 months (HR 1.92, 95% CI 1.58–2.33; $p < 0.001$), with higher heart failure hospitalization rates [7].

ECMO-assisted TAVR proved life-saving in this case. Prophylactic ECMO in very high-risk TAVR patients achieved 100% procedural success and 0% 30-day mortality versus 44% for both with emergency ECMO [12]. However, overall ECMO use increases complications including bleeding (OR 3.32) and renal failure (OR 2.38) [13].

Clinical implication: Valve-in-valve TAVR is appropriate for rescue in cardiogenic shock with prohibitive surgical risk, but long-term surveillance is essential given late mortality divergence [5, 6].

TAVR in the presence of valvular vegetations (even non-infective) is off-label and controversial

Active endocarditis is considered a contraindication in current guidelines, and surgery remains the standard treatment for patients with valvular vegetations. The decision to proceed was driven by prohibitive redo surgical risk (STS-PROM 18.2%) and hemodynamic instability, representing a rescue strategy that should not be extrapolated to elective management. No cerebral embolic protection device was used, and no systematic post-procedural neuroimaging was performed to assess for silent embolization. While the PROTECTED TAVR ($N = 3{,}000$) and PROTECT-TAVI ($N = 7{,}635$) trials showed no benefit of routine cerebral protection in standard TAVR, no data exist for patients with pre-existing vegetations, where embolic burden may be substantially higher. The patient had no clinically apparent embolic events, but subclinical embolization cannot be excluded.

Immunosuppression escalation

Rapid bioprosthetic failure prompted immunosuppression escalation. Rituximab has been used in refractory APS, though the evidence consists entirely of uncontrolled case series and a single small pilot trial — no RCTs exist. In a multicenter retrospective experience (40 patients), favorable response was documented in 80% (complete response 55%), with higher response rates for the 375 $mg/m^2 \times 4$ protocol versus 1000 mg × 2 (100% vs. 65%, $p = 0.01$) [10], limited by small sample size and retrospective design. One systematic review classified rituximab as having failed to demonstrate efficacy for APS overall [14].

In this case, rituximab 1000 mg × 2 was administered. While LVEF improved from 25 to 29% to 55–59% at 4.5 months (sustained at 50–54% at 8 months), **this recovery is expected after relief of severe aortic stenosis** — large TAVR registries show ~ 80% of patients with low baseline LVEF recover to > 40% by 1 year. The relative contributions of mechanical relief versus immunosuppression cannot be disentangled. The absence of recurrent obstruction at 8 months may reflect immunosuppressive benefit, but this remains speculative [10, 13].

Long-term surveillance

Right ventricular function showed an improving trajectory (TAPSE 1.1 → 1.5 cm) but remained below normal (> 1.6 cm), warranting continued surveillance. Long-term TAVR durability in autoimmune disease is unknown, warranting echocardiographic surveillance every 6–12 months.

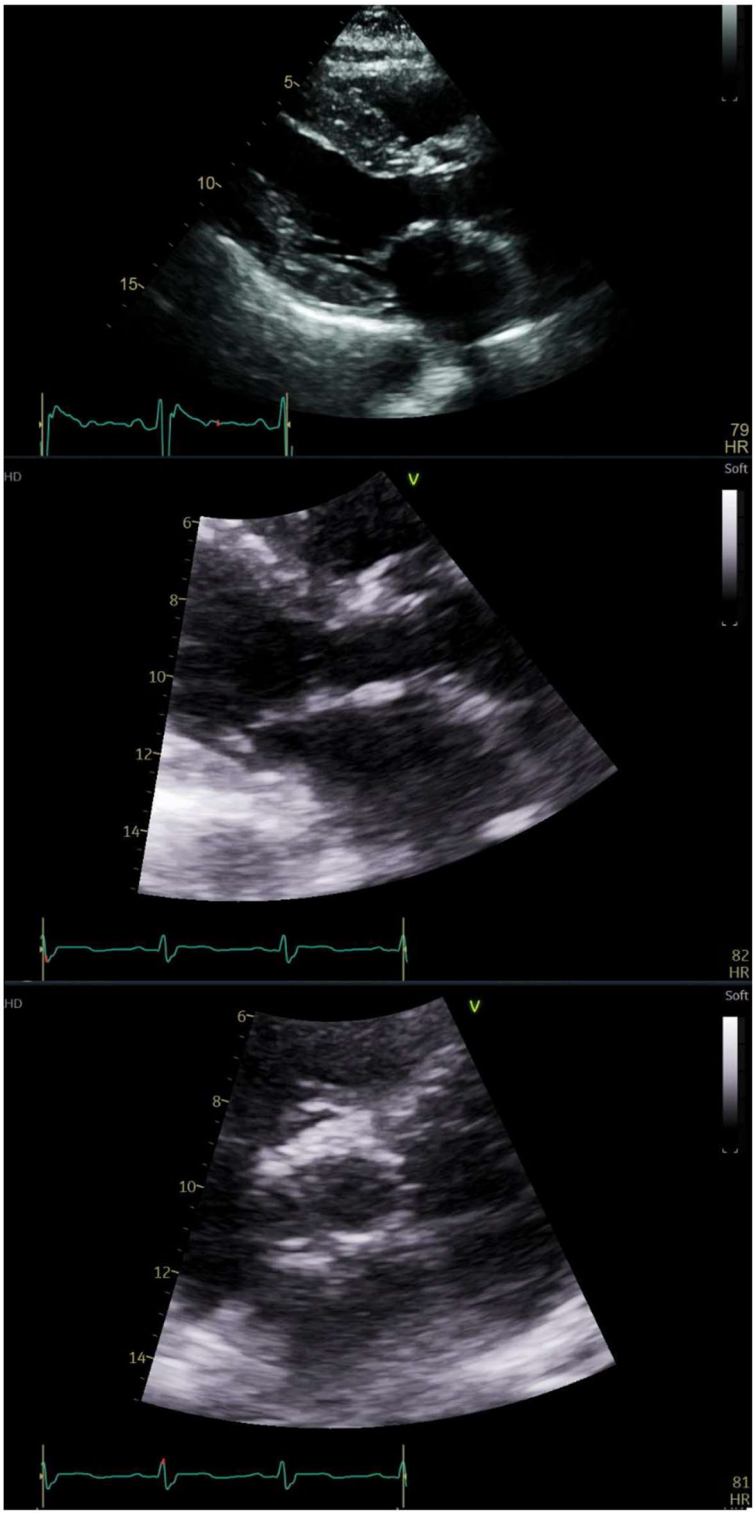

Fig. 4 ECMO-assisted valve-in-valve TAVR and recovery. Upper: TTE 3 weeks post-TAVR showing well-seated valve-in-valve. Middle: Lower: TTE 4.5 months post-TAVR showing stable configuration

Strengths and limitations

Strengths: 20-year longitudinal follow-up with complete serologic data; histopathologic confirmation of native valve LSE; first reported ECMO-assisted valve-in-valve TAVR in this clinical context.

Limitations: (1) Single case; cannot establish causality. (2) Prosthetic valve obstruction etiology uncertain; no 4D CT, no histopathology of prosthetic valve, no anticoagulation trial (precluded by cardiogenic shock); BPVT remains a competing diagnosis. (3) LVEF recovery is expected after relief of severe aortic stenosis and cannot be attributed to rituximab. (4) No cerebral embolic protection or post-procedural neuroimaging to assess silent embolization. (5) TAVR with valvular vegetations is off-label; this approach is exceptional, not generalizable. (6) 8-month follow-up insufficient to assess late outcomes given documented late mortality divergence. (7) Persistent RV dysfunction requires surveillance.

Patient perspective

I never expected to need two heart valve surgeries. The second time, when I was in shock, I thought I wouldn't make it. The team explained everything clearly; why the blood thinner pills didn't work for me, why they needed the heart-lung machine during the procedure. Now I understand why I need to take warfarin for life and get regular blood tests. I'm grateful to be alive and want other patients to know that even when things seem hopeless, there are options.

Conclusion

This case illustrates the aggressive nature of autoimmune valvular disease in triple-positive APS/SLE, the failure of DOACs, and the feasibility of ECMO-supported valve-in-valve TAVR as an exceptional rescue strategy in cardiogenic shock with prohibitive surgical risk. The etiology of rapid prosthetic valve obstruction — whether recurrent LSE, BPVT, or mixed pathology — could not be definitively established. Warfarin-based anticoagulation (INR 2–3) and hydroxychloroquine remain first-line therapy; immunosuppression escalation including rituximab may be considered for refractory disease, though its independent contribution requires further study. This approach should not be extrapolated to elective management, and long-term surveillance is essential.

Learning points

1. Recognize LSE in high-risk patients: Triple-positive APS confers 27% prevalence of NBTE versus 5.7% in single-positive disease. Systematic echocardiographic screening is warranted in triple-positive APS patients.
2. Avoid DOACs in triple-positive APS: The TRAPS trial demonstrated 12% vs. 0% thromboembolic events with rivaroxaban versus warfarin. Warfarin (INR 2–3) with hydroxychloroquine is mandatory.
3. Consider ECMO-supported TAVR for rescue only: This off-label approach is appropriate exclusively for cardiogenic shock with prohibitive surgical risk in experienced centers. Surgery remains the standard for valvular vegetations. Long-term surveillance is mandatory given late mortality divergence (HR 1.92, 95% CI 1.58–2.33 beyond 6 months).
4. Consider immunosuppression escalation cautiously: Rituximab may be considered for refractory APS, but evidence is limited to uncontrolled series. LVEF improvement after relief of severe aortic stenosis is an expected physiological response and should not be attributed to immunosuppression without controlled data.
5. Implement long-term surveillance: Persistent RV dysfunction and late mortality divergence require serial echocardiography every 6–12 months and multidisciplinary follow-up.

Abbreviations

APS	Antiphospholipid Syndrome
aPL	Antiphospholipid Antibody
AV	Aortic Valve
AVA	Aortic Valve Area
BNP	B-type Natriuretic Peptide
BPVT	Bioprosthetic Valve Thrombosis
BVD	Bioprosthetic Valve Dysfunction
CKD	Chronic Kidney Disease
CRP	C-Reactive Protein
DOACs	Direct Oral Anticoagulants
dsDNA	Double-Stranded DNA
ECMO	Extracorporeal Membrane Oxygenation
ESR	Erythrocyte Sedimentation Rate
GFR	Glomerular Filtration Rate
GPL	IgG Phospholipid Units
HR	Hazard Ratio
ICU	Intensive Care Unit
IgA	Immunoglobulin A
IgG	Immunoglobulin G
INR	International Normalized Ratio
LSE	Libman-Sacks Endocarditis
LVEF	Left Ventricular Ejection Fraction
MR	Mitral Regurgitation
NBTE	Non-Bacterial Thrombotic Endocarditis
NYHA	New York Heart Association
OR	Odds Ratio
RV	Right Ventricular
SAVR	Surgical Aortic Valve Replacement
SGU	Standard IgG Units
SLE	Systemic Lupus Erythematosus
STS-PROM	Society of Thoracic Surgeons Predicted Risk of Mortality
TAPSE	Tricuspid Annular Plane Systolic Excursion
TAVR	Transcatheter Aortic Valve Replacement
TEE	Transesophageal Echocardiography
TTE	Transthoracic Echocardiography
β2-GP1	β2-Glycoprotein I

Supplementary Information

The online version contains supplementary material available at https://doi.org/10.1186/s43044-026-00794-9.

Supplementary Material 1

Supplementary Material 2

Supplementary Material 3

Supplementary Material 4

Supplementary Material 5

Supplementary Material 6

Supplementary Material 7

Supplementary Material 8

Supplementary Material 9

Author contributions

SA, NI, and AB were involved in patient care. NI drafted the manuscript. SA, HF, and AB critically revised the manuscript. All authors read and approved the final manuscript.

Data availability

All data generated or analyzed during this study are included in this published article.

Declarations

Ethics approval and consent to participate

This case report was conducted in accordance with established ethical standards for human subject research. All clinical information was obtained through routine care, and no experimental interventions were performed outside accepted clinical practice. The patient provided informed consent for inclusion in this report and for publication of all clinical details and images.All procedures performed in the management of this patient were in accordance with the ethical standards of the institutional and national research committees, the principles outlined in the Declaration of Helsinki (2013 revision), and applicable U.S. regulations governing human subject protection. Formal ethics approval for this single-patient case report was reviewed and waived by the HCA Houston Healthcare Institutional Review Board, as per institutional policy for case reports that do not meet the definition of human subjects research.

Competing interests

The authors declare no competing interests.

Author details

[1]HCA Healthcare (United States), Nashville, USA

Received: 5 April 2026 / Accepted: 27 October 2026
Published online: 16 November 2026

References

1. Lenz CJ, Mankad R, Klarich K et al (2020) Antiphospholipid syndrome and the relationship between laboratory assay positivity and prevalence of non-bacterial thrombotic endocarditis: a retrospective cohort study. J Thromb Haemost 18(6):1408–1414. https://doi.org/10.1111/jth.14798
2. Miyakis S, Lockshin MD, Atsumi T et al (2006) International consensus statement on an update of the classification criteria for definite antiphospholipid syndrome (APS). J Thromb Haemost 4(2):295–306. https://doi.org/10.1111/j.1538-7836.2006.01753.x
3. Corban MT, Duarte-Garcia A, McBane RD et al (2017) Antiphospholipid syndrome: role of vascular endothelial cells and implications for risk stratification and targeted therapeutics. J Am Coll Cardiol 69(18):2317–2330. https://doi.org/10.1016/j.jacc.2017.02.058
4. Pengo V, Denas G, Zoppellaro G et al (2018) Rivaroxaban vs warfarin in high-risk patients with antiphospholipid syndrome. Blood 132(13):1365–1371. https://doi.org/10.1182/blood-2018-04-848333
5. Bejjani A, Khairani CD, Assi A et al (2024) When direct oral anticoagulants should not be standard treatment: JACC state-of-the-art review. J Am Coll Cardiol 83(3):444–465. https://doi.org/10.1016/j.jacc.2023.10.038
6. Van den Sá MPBO, Simonato M et al (2021) Valve-in-valve transcatheter aortic valve replacement versus redo surgical aortic valve replacement: an updated meta-analysis. JACC Cardiovasc Interv 14(2):211–220. https://doi.org/10.1016/j.jcin.2020.10.020
7. Tran JH, Itagaki S, Zeng Q et al (2024) Transcatheter or surgical replacement for failed bioprosthetic aortic valves. JAMA Cardiol 9(7):631–639. https://doi.org/10.1001/jamacardio.2024.1049
8. Otto CM, Nishimura RA, Bonow RO et al (2021) 2020 ACC/AHA guideline for the management of patients with valvular heart disease. J Am Coll Cardiol 77(4):e25–e197. https://doi.org/10.1016/j.jacc.2020.11.018
9. Petrescu I, Egbe AC, Ionescu F et al (2020) Long-term outcomes of anticoagulation for bioprosthetic valve thrombosis. J Am Coll Cardiol 75(8):857–866. https://doi.org/10.1016/j.jacc.2019.12.037
10. Agmon-Levin N, Berman M, Harel L et al (2021) Rituximab for refractory manifestations of the antiphospholipid syndrome: a multicentre Israeli experience. Clin Exp Rheumatol 39(5):1049–1055. https://doi.org/10.55563/clinexprheumatol/cc5taf
11. Kravvariti E, Koutsogianni A, Samoli E, Sfikakis PP, Tektonidou MG (2020) The effect of hydroxychloroquine on thrombosis prevention and antiphospholipid antibody levels in primary antiphospholipid syndrome: a pilot open label randomized prospective study. Autoimmun Rev 19(4):102491. https://doi.org/10.1016/j.autrev.2020.102491
12. Husser O, Holzamer A, Philipp A et al (2013) Emergency and prophylactic use of miniaturized veno-arterial extracorporeal membrane oxygenation in transcatheter aortic valve implantation. Catheter Cardiovasc Interv 82(4):E542–551. https://doi.org/10.1002/ccd.24806
13. Banga A, Bansal V, Pattnaik H et al (2024) Extracorporeal membrane oxygenation-supported patient outcome undergoing transcatheter aortic valve replacement. ASAIO J 70(11):920–928. https://doi.org/10.1097/MAT.0000000000002305
14. Erkan D, Vega J, Ramón G, Kozora E, Lockshin MD (2013) A pilot open-label phase II trial of rituximab for non-criteria manifestations of antiphospholipid syndrome. Arthritis Rheum 65(2):464–471. https://doi.org/10.1002/art.37759

Publisher's note

Springer Nature remains neutral with regard to jurisdictional claims in published maps and institutional affiliations.