SURGICAL CASE REPORTS Surg Case Rep 2026; 12: 26-0389

Case Report

Robotic Simultaneous Hepatectomy and Distal Pancreatectomy as Conversion Surgery for Metastatic Pancreatic Neuroendocrine Tumor

Masakazu Yamaguchi,[1] Yuta Ushida,[1] Yoriko Yamashita,[2] Takeru Itoi,[1] Masaya Inoue,[1] and Gen Sugawara[1]

ABSTRACT

INTRODUCTION: Systemic therapies have improved outcomes in patients with advanced pancreatic neuroendocrine tumors (PanNETs), and somatostatin analogs are recommended as first-line treatment options for selected patients with advanced disease. However, reports on conversion surgery for PanNETs with multiple liver metastases that are initially not amenable to upfront curative-intent resection remain limited, and robot-assisted simultaneous pancreatic and liver resections are rarely described.

CASE PRESENTATION: A 71-year-old woman was incidentally diagnosed with multiple liver nodules by abdominal ultrasonography. Contrast-enhanced CT revealed a calcified tumor in the pancreatic tail with enlarged regional lymph nodes, whereas the liver lesions were better delineated by contrast-enhanced MRI, including a lesion adjacent to the middle hepatic vein. Percutaneous US-guided biopsy of a superficial liver lesion confirmed a well-differentiated neuroendocrine tumor (NET) G2. The patient was diagnosed with a nonfunctioning PanNET with 4 liver metastases, including 1 adjacent to the middle hepatic vein; therefore, complete parenchyma-sparing resection was initially considered infeasible. Transcatheter arterial chemoembolization was performed as locoregional therapy to control the dominant liver lesion supplied by the hepatic artery A5. Systemic lanreotide therapy was administered for approximately 2 years, with mild cutaneous toxicity. Follow-up imaging demonstrated marked regression of the liver metastases: 1 lesion shrank, and the others disappeared, whereas the primary pancreatic tumor and regional lymph node metastases persisted. Therefore, curative-intent conversion surgery was planned, and robot-assisted simultaneous hepatectomy of the residual liver lesion (segment 5) and distal pancreatectomy with lymph node dissection were performed using 5 ports. The operative time was 8h 2 min, and the blood loss was 5 mL. Postoperatively, a minor pancreatic fistula developed and resolved with drainage. The patient was discharged on POD 35. Pathological examination revealed scarred liver metastasis, whereas the pancreatic tumor and 4 metastatic lymph nodes remained viable, corresponding to NET G1 (Ki-67 index, 1%). The patient remained recurrence-free at 15 months postoperatively.

CONCLUSIONS: Even in patients with PanNETs and liver metastases, who are initially considered unsuitable for upfront resection, a sustained response to medical therapy can enable

[1]Department of Surgery, Toyota Kosei Hospital, Toyota, Aichi, Japan
[2]Department of Pathology, Toyota Kosei Hospital, Toyota, Aichi, Japan

Corresponding author: Yuta Ushida. Department of Surgery, Toyota Kosei Hospital, 500-1 Josui-cho, Toyota, Aichi 470-0396, Japan
E-mail: yuta.ushida.miwa@gmail.com

Received: May 20, 2026; Accepted: October 18, 2026
DOI: 10.70352/scrj.cr.26-0389

© 2026 The Author(s). Published by Japan Surgical Society
This article is licensed under a Creative Commons Attribution 4.0 International License.

curative-intent conversion surgery. Timely surgical consideration is essential, and robot-assisted simultaneous pancreatectomy and hepatectomy may be a feasible strategy for selected patients.

KEYWORDS: pancreatic neuroendocrine tumor, liver metastases, lanreotide, transcatheter arterial chemoembolization, conversion surgery, robotic surgery, simultaneous resection

Abbreviations

ICG	indocyanine green
NELM	neuroendocrine liver metastases
NET	neuroendocrine tumor
PanNET	pancreatic neuroendocrine tumor
PRRT	peptide receptor radionuclide therapy
SSA	somatostatin analog
TACE	transcatheter arterial chemoembolization

INTRODUCTION

PanNETs frequently present with metastatic disease. Treatment strategies include systemic therapies, locoregional liver-directed treatments, and surgery in selected cases. SSAs, such as lanreotide, are generally recommended as first-line treatment for patients with advanced PanNETs, primarily to slow tumor progression.[1)]

Although conversion surgery has been discussed for locally advanced PanNET,[2)] reports describing conversion surgery in cases with initially unresectable multiple liver metastases remain scarce. Moreover, robot-assisted simultaneous resection of the primary pancreatic and liver metastases has been reported only sporadically and remains technically challenging.[3)] We report a case of a PanNET with multiple liver metastases that was initially not amenable to curative-intent resection but became resectable after TACE followed by long-term lanreotide administration, allowing robot-assisted simultaneous distal pancreatectomy with lymphadenectomy and hepatectomy. The educational value of this case lies in demonstrating that resectability in metastatic PanNETs is dynamic, the treatment response may differ across disease sites, and a phase-specific robotic strategy can facilitate simultaneous resection after successful downstaging.

CASE PRESENTATION

A 71-year-old woman underwent abdominal ultrasonography for urinary tract stones and was incidentally found to have multiple liver nodules predominantly in the right hepatic lobe (**Fig. 1A–1C**). She reported mild diarrhea and abdominal discomfort. Physical examination findings were unremarkable. Laboratory data, including liver function tests, endocrine tests, and tumor markers, were within normal ranges. MRI revealed 4 liver tumors ranging from 11 to 36 mm in diameter, including a lesion adjacent to the middle hepatic vein (**Fig. 1D–1F**). Contrast-enhanced CT revealed a calcified tumor in the pancreatic tail with enlarged regional lymph nodes (**Fig. 2A**, **2B**); the liver lesions were not clearly detected on CT. The pancreatic tumor showed faint contrast enhancement and diffusion restriction on MRI (**Fig. 2C**, **2D**). Percutaneous US-guided biopsy of the superficial liver tumor confirmed a well-differentiated NET G2, with immunohistochemical results of synaptophysin [+], CD56 [+], and a Ki-67 index of 10% (**Fig. 3**). The patient was diagnosed with a nonfunctioning PanNET with multiple liver metastases (T2N1M1, Stage IV, according to the 8th edition of the Union for International Cancer Control staging system). Contrast-enhanced MRI revealed 4 liver metastases, including a 28-mm lesion in segment 4/8 abutting the middle hepatic vein, whereas the remaining lesions were confined to the right hepatic lobe. Complete clearance of all hepatic disease at that time would have required at least an extended right hepatectomy, and limited parenchyma-sparing resection was not considered feasible. The multidisciplinary team considered the disease not amenable to upfront curative-intent resection. First, a single session of TACE was performed to control the dominant liver metastasis and abdominal symptoms. Angiography identified the tumor feeder from hepatic artery A5, and intra-arterial infusion of a Lipiodol-based emulsion containing epirubicin (15 mg) was administered, followed by embolization using Gelpart (Nippon Kayaku, Tokyo, Japan). Epirubicin was selected as part of our institution's conventional Lipiodol-based TACE protocol. The patient's abdominal symptoms improved after the TACE. Subsequently, lanreotide was administered as systemic therapy (120 mg every 4 weeks) for approximately 2 years. The treatment was well tolerated, with only mild cutaneous rash. Serial contrast-enhanced MRI revealed a marked and sustained hepatic response. The number of MRI-detectable liver lesions decreased from 4 at baseline to 1 before surgery. The size of the residual segment 5 lesion decreased from 36 to 19 mm, whereas the other lesions were no longer detectable. Retrospective assessment according to the Response Evaluation Criteria in Solid Tumors (RECIST) version 1.1 showed that the sum of target lesion diameters decreased from 87 to 19 mm representing a 78% reduction. The best overall response was a partial response. The primary pancreatic tumor and regional lymph node metastases remained stable, and no new intrahepatic or extrahepatic lesions developed during approximately 18 months of sustained disease control (**Fig. 4**).

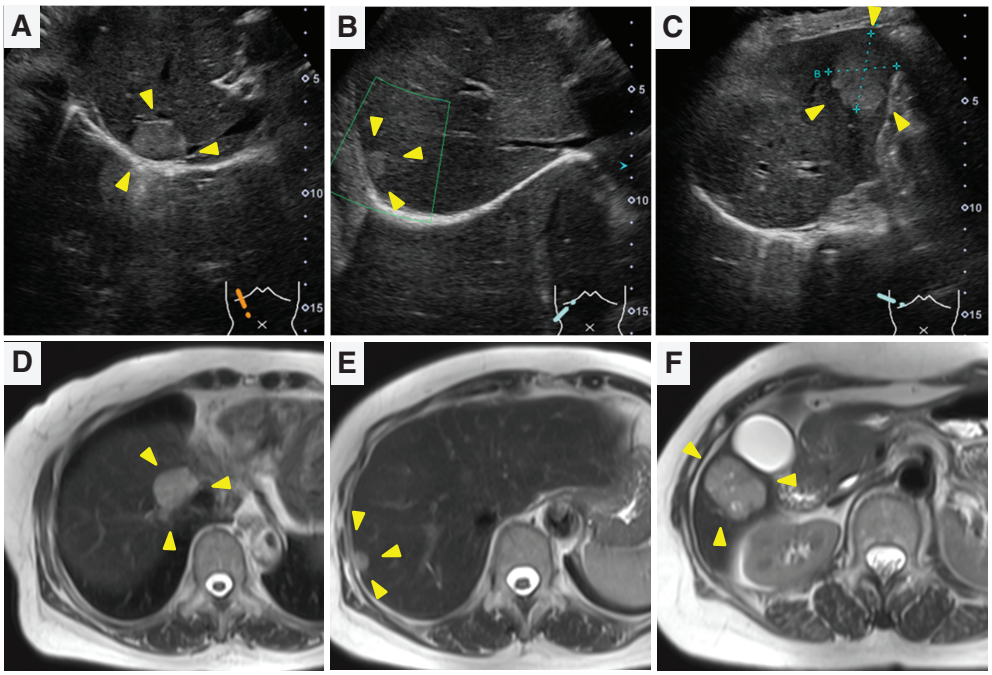

Fig. 1 Baseline imaging of the liver metastases. Four lesions were identified with a maximum diameter of 36 mm: 3 in the right hepatic lobe and 1 in segment 4/8 (**C**, **F**), abutting the middle hepatic vein. Yellow arrowheads indicate tumors. (**A**–**C**) Abdominal ultrasonography. (**D**–**F**) T2-weighted MRI images.

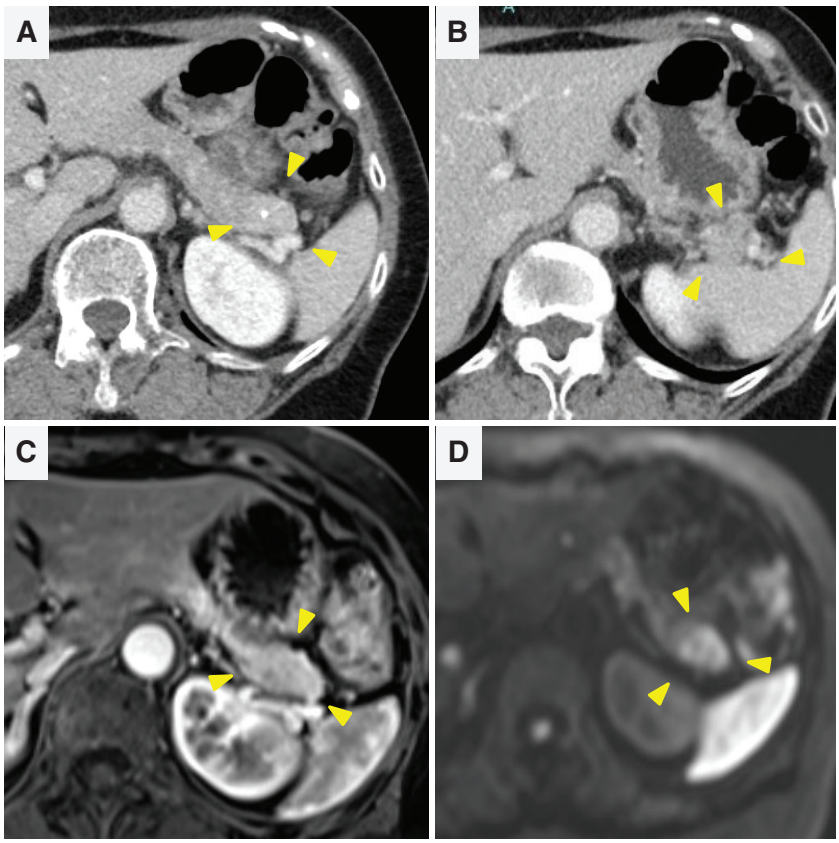

Fig. 2 Initial imaging of the primary pancreatic tumor (**A**, **C**, **D**), and enlarged regional lymph nodes (**B**). Yellow arrowheads indicate the tumor. (**A**, **B**) Contrast-enhanced CT. (**C**) T2-weighted contrast-enhanced MRI. (**D**) Diffusion-weighted MRI.

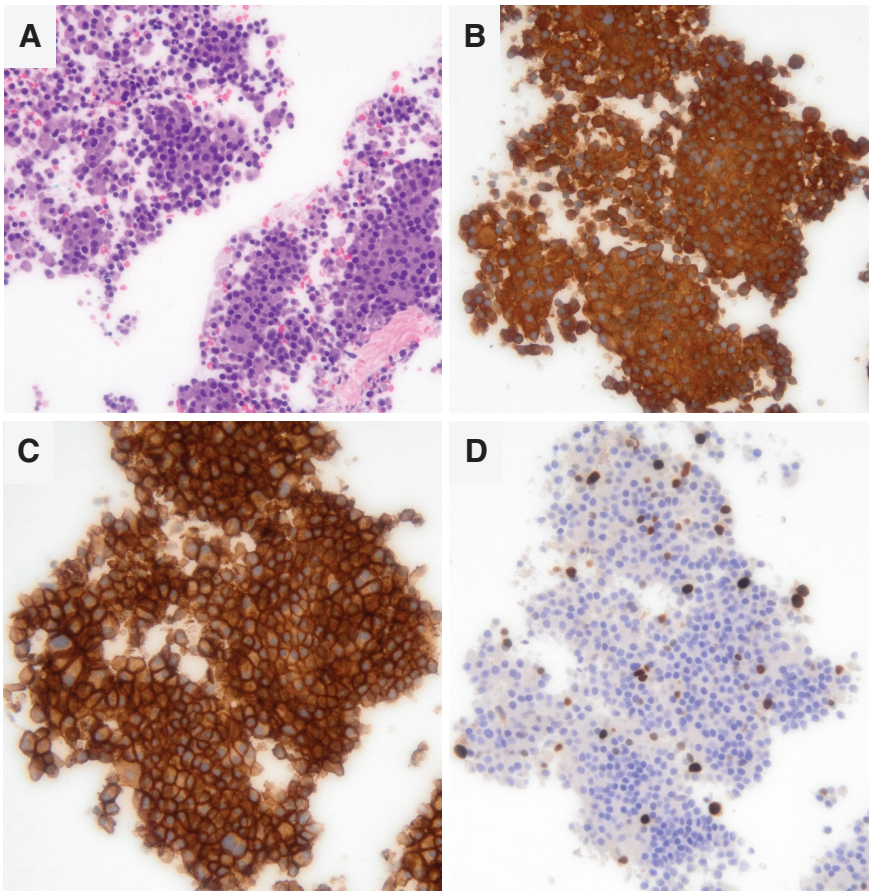

Fig. 3 Pathology of percutaneous liver biopsy: microscopic view at 40× magnification. (**A**) Tumor cells proliferating in trabecular and solid patterns were confirmed on the H&E-stained specimen. (**B**) Synaptophysin staining was positive. (**C**) CD56 staining was positive. (**D**) Ki-67 index 10%.

H&E, hematoxylin and eosin

Given the sustained therapeutic response, which was maintained for approximately 18 months, the patient's case was reassessed at a multidisciplinary conference. Residual hepatic disease was limited to a solitary lesion in segment 5 that was amenable to complete resection by minor parenchyma-sparing hepatectomy. There was no evidence of new metastatic disease. The primary pancreatic tumor and regional lymph node metastases remained technically resectable by distal pancreatectomy with lymphadenectomy. Based on these anatomical and oncological findings, curative-intent conversion surgery was considered a reasonable treatment option. After shared decision-making with the patient, robot-assisted simultaneous resection was performed, including hepatectomy of the residual solitary lesion in segment 5 and distal pancreatectomy with regional lymphadenectomy. The operation was completed using 5 ports, and the docking position of the ports was changed between the pancreatic and hepatic phases of the procedure (**Fig. 5**). After precise delineation of the tumor contours using ICG fluorescence imaging, H5′ hepatectomy was performed. The operative time was 8h 2 min, and blood loss was 5 mL. No intra-operative transfusions were required. The postoperative course was complicated by a Grade B postoperative pancreatic fistula, as defined by the International Study Group of Pancreatic Fistula; however, there was no bile leakage or other major complications. The patient was discharged on POD 35. Final pathological examination showed that the resected liver lesion was largely replaced by scar tissue without viable tumor cells (**Fig. 6A**). In contrast, the pancreatic tumor and metastatic lymph nodes were viable (**Fig. 6B**, **6C**). The pancreatic tumor corresponded to NET G1 with a Ki-67 index of 1% (**Fig. 6D**). The surgical margins were negative. Of the 7 lymph nodes examined, 4 were positive. The patient has been followed up without adjuvant therapy and remains alive without recurrence at postoperative month 15.

DISCUSSION

This case report highlights 3 clinically relevant points. First, even in patients with PanNETs with multiple liver metastases that are not initially amenable to curative-intent resection, a sustained response to multimodal therapy may

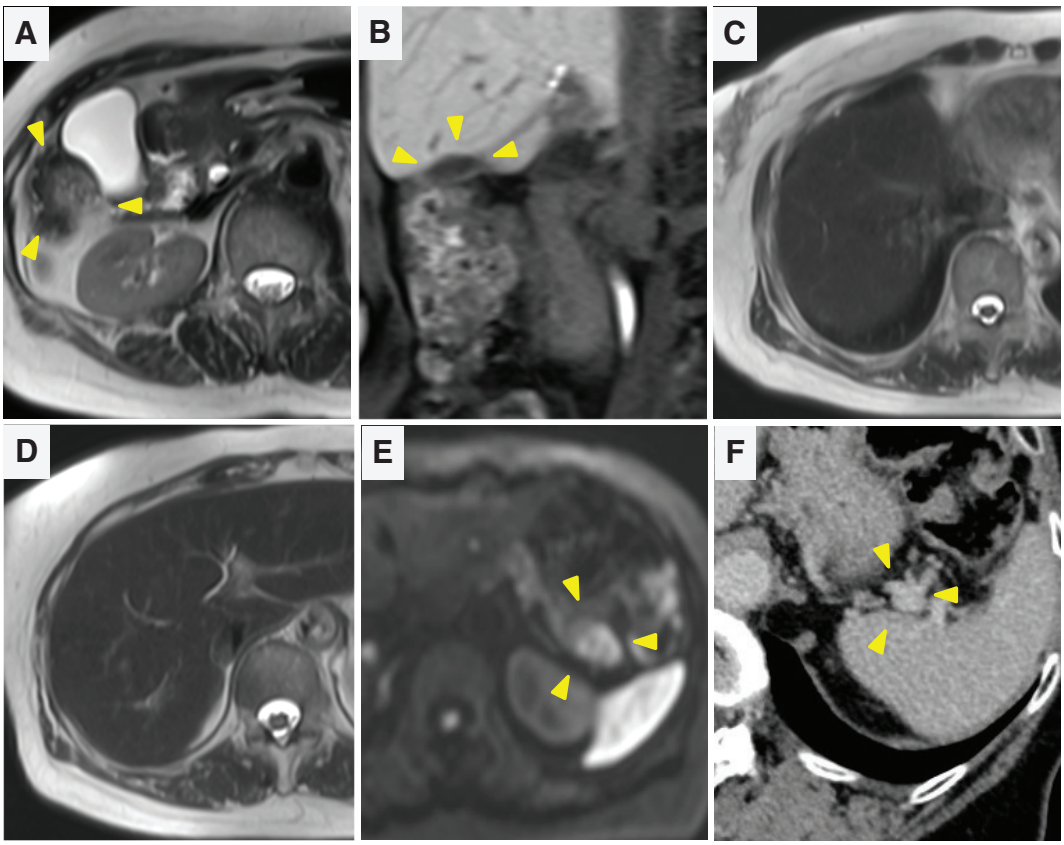

Fig. 4 Imaging of the liver tumors (**A**–**D**), the primary pancreatic tumor (**E**), and regional lymph nodes (**F**) on T2-weighted MRI (**A**, **C**, **D**), T2-weighted enhanced MRI (**B**), diffusion-weighted MRI (**E**), and enhanced CT (**F**) after TACE and SSAs. One NELM shrank (**A**, **B**) and the others disappeared (**C**, **D**), whereas the primary pancreatic tumor and regional lymph node metastases remained stable (**E**, **F**).

NELM, neuroendocrine liver metastases; SSAs, somatostatin analogs; TACE, transcatheter arterial chemoembolization

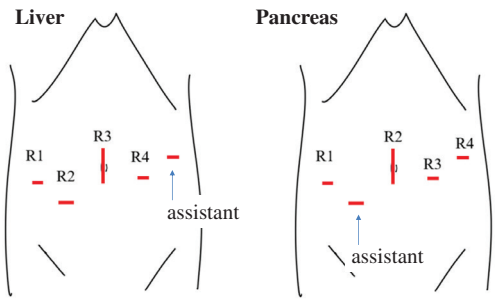

Fig. 5 Phase-specific port-shift strategy for simultaneous robotic hepatectomy and distal pancreatectomy. The center of the port configuration was shifted according to the operative phase to optimize the visual axis and instrument alignment for hepatectomy (left) and distal pancreatectomy (right).

create an opportunity for curative-intent conversion surgery. Second, robot-assisted simultaneous distal pancreatectomy with lymphadenectomy and hepatectomy was technically feasible in this downstaged setting, with minimal blood loss and acceptable postoperative morbidity. The use of a phase-specific port-shift strategy may have contributed to improved visualization and operability during both the pancreatic and hepatic phases. Third, the discordant pathological response — scar formation in liver lesions despite viable pancreatic and nodal disease — suggests that treatment effects may differ across disease sites. Thus, the value of this case lies not only in its rarity but also in showing that resectability in metastatic PanNETs is dynamic and should be reassessed repeatedly, while surgical timing and strategy should be individualized.

Generally, liver resection for NELM of G1–2 NET contributes to improved overall survival, and hepatectomy for resectable lesions has been considered the first choice.[4,5] However, conversion surgery for initially unresectable NELM of a PanNET has rarely been reported. Several recent case reports have suggested that some patients may become surgical candidates after effective systemic and/or locoregional therapies (**Table 1**[6–11]). In particular, cases have been described in which multiple initially unresectable liver metastases became amenable to resection after PRRT combined with SSAs. Another report described a patient with a G3 PanNET in whom the primary tumor, liver metastases, and lymph node metastases were resected

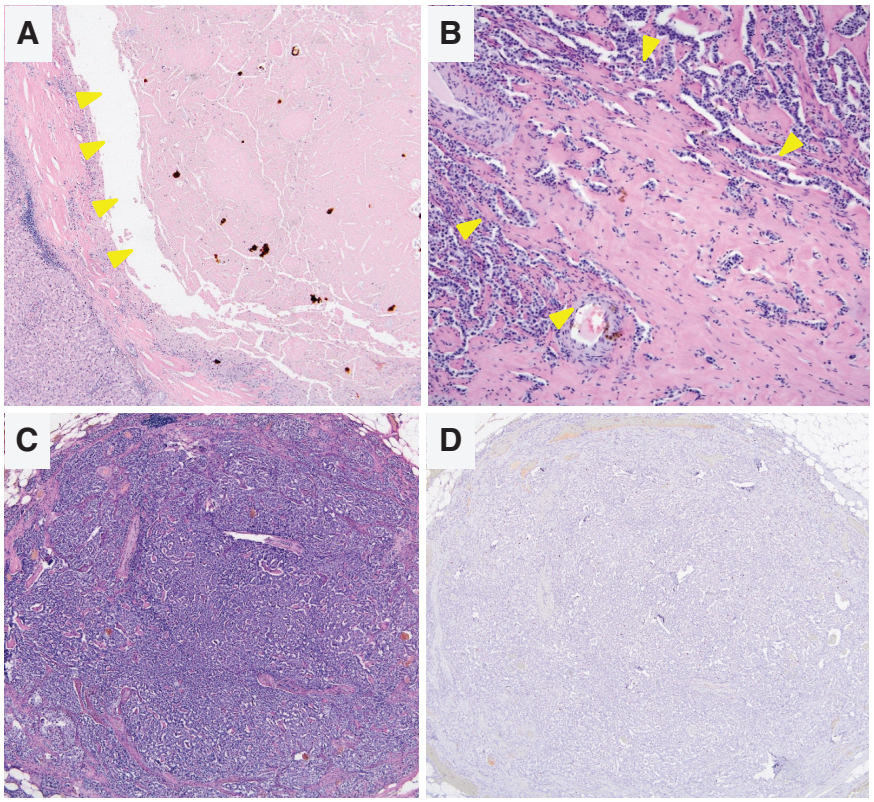

Fig. 6 Pathology of the resected specimen: microscopic view at 4× (**A**, **C**, **D**), and 10× (**B**). Yellow arrowheads indicate tumor scarring. Despite the complete disappearance of the liver tumor (**A**), the pancreatic primary exhibited only minimal regression (**B**), and the lymph nodes remained predominantly viable (**C**). The Ki-67 index was 1% (**D**).

after PRRT. These reports indicate that resectability in metastatic PanNETs should not be regarded as a static concept defined only at the initial diagnosis, but rather as a dynamic condition that should be reassessed according to treatment response. For NELM, surgical resection remains the treatment most strongly associated with prolonged survival in resectable cases.[5,12,13] Multimodal treatment strategies incorporating TACE, SSAs, and PRRT may serve not only for tumor control but also as a bridge to surgery. Although no chemotherapeutic agent has been established as superior for use in TACE for patients with NELM, epirubicin-containing Lipiodol-based hepatic arterial therapy has been used in clinical reports of liver metastases from PanNETs.[14,15] In this case, epirubicin was selected according to the conventional TACE protocol. Because the treatment strategy combined TACE, which produces embolic ischemia and locoregional drug delivery, with subsequent long-term lanreotide treatment, the marked hepatic response cannot be attributed to epirubicin alone. In the present case, TACE followed by long-term lanreotide therapy resulted in a marked reduction in the liver tumor burden, ultimately enabling parenchyma-sparing hepatectomy. Therefore, this case highlights the importance of repeated reassessments of resectability in patients with initially unresectable PanNETs and multiple liver metastases. Since standardized criteria for conversion surgery in metastatic PanNETs have not been established, RECIST response should not be used as the sole determinant of resectability. Reassessment should also consider the durability of disease control, absence of new lesions, possibility of complete tumor clearance while preserving adequate liver parenchyma, the relationship of residual lesions to major vascular and biliary structures, and the overall operative burden. The extent and distribution of residual liver disease should be considered when determining whether simultaneous or staged pancreatic and hepatic resections are appropriate after successful downstaging. Gudmundsdottir et al. reported that combined pancreatic and hepatic resection for metastatic PanNETs can be performed with acceptable morbidity and mortality in selected patients, particularly when major pancreatic resection and hepatectomy are not required simultaneously.[16] In the present case, multimodal treatment reduced the hepatic disease burden from 4 lesions to a solitary segment 5 lesion. The residual tumor showed no radiological evidence of major vascular or biliary invasion and was amenable to complete resection with minor parenchyma-sparing hepatectomy. The primary pancreatic tumor remained resectable by distal pancreatectomy, and no new metastatic lesions developed during prolonged

Table 1 Reported cases of radical surgery after preoperative therapy for unresectable NELM from nonfunctioning PanNET (2016–2026)

Year/Author	Age*/ sex	Metastasis timing	WHO grade	Preoperative treatment	Procedure	Surgical approach	Response	Adjuvant	Prognosis
2016/Calin[6]	52/F	Sync	G2	Sandostatin TAE	DP, H234	Robot	n.d	None	116 months DFS
2020/Chiapponi[7]	49/M	Sync	G2	Sandostatin + PRRT Radiotherapy	DP, H3′, 4a′, 5′, 6′, 7′, 8′	Open	PR	None	17 months recurrent 6 years alive
2022/Yumoto[8]	38/M	Meta	G2	DP + 5 partial hepatectomies Everolimus + Octreotide	H7′ H6 cCR, observe	Open	n.d	Everolimus Octreotide	About 6 years recurrent About 9 years alive
2023/Saadoun[9]	46/F	Sync	n.d	Somatostatin analog	DP, H678′ (2 steps)	Robot	SD	n.d	n.d
2024/Umino[10]	52/M	Meta	G2	PD, 2 times hepatectomy PRRT, lanreotide	H2′, H8′	Open	CR	None	17 months DFS
2025/Sakaki[11]	59/F	Sync	G3	Streptozosin + Lanreotide TACE for largest NELM PRRT	PD with PVR H23, H4′, H5′	Open	PR	Lanreotide	6 months DFS
Our case	71/F	Sync	G2 (biopsy)	TACE Lanreotide	DP, H5′	Robot	NELM: PR** Primary/LN: SD	None	15 months DFS

*Numbers indicate years.

**Three liver lesions disappeared radiologically and the resected residual liver lesion contained no viable tumor cells.

cCR, clinical complete response; CR, complete response; DFS, disease-free survival; DP, distal pancreatectomy; F, female; LN, lymph node; M, male; Meta, metachronous; n.d., not described; NELM, neuroendocrine liver metastases; PanNET, pancreatic neuroendocrine tumor; PD, pancreaticoduodenectomy; PR, partial response; PRRT, peptide receptor radionuclide therapy; PVR, portal vein resection; SD, stable disease; Sync, synchronous; TACE, transcatheter arterial chemoembolization; TAE, transcatheter arterial embolization; WHO, World Health Organization

disease control. Neither major hepatectomy nor major pancreatectomy was required; therefore, simultaneous resection was favored over a staged approach. These findings suggest that the number and anatomical distribution of residual liver lesions, their relationship to major vascular and biliary structures, and the anticipated magnitude of hepatectomy are important factors when considering conversion surgery for metastatic PanNETs.

Simultaneous resection of the pancreatic primary lesion and liver metastasis is technically demanding because it requires the completion of 2 major upper abdominal procedures within a single operation. Nevertheless, with the recent advances in minimally invasive surgery, particularly robotic surgery, the feasibility and safety of such combined procedures have increasingly been reported.[6,17] In 2 previously reported cases, the procedures were completed safely without the need for conversion to open surgery, including cases that required combined resection of the adjacent organs.[17]

Robotic surgery offers several technical advantages, including stable, magnified 3D visualization, articulated instruments, and enhanced precision in dissection and suturing — all of which are beneficial for delicate pancreatic dissection and controlled liver parenchymal transection. At our institution, ICG fluorescence imaging is used for tumor localization, facilitating accurate tumor identification and appropriate resection margin setting. We used a total liver volume (TLV)-normalized positive-staining protocol in which the ICG dose was scaled to the preoperatively measured TLV to standardize hepatic ICG exposure across patients. Based on our previous image-based analysis, ICG was administered intravenously at noon on the day before surgery at a dose of 6.8 mg/L of TLV, according to the following formula: dose (mg) = 6.8 × TLV (L).[18] In this case, the tumor lesion showed positive fluorescence and was readily localized in combination with intraoperative ultrasonography.

A notable technical feature of the present case was the use of a port-shift strategy, illustrated in **Fig. 5**, in which the center of the port configuration was adjusted according to the operative phase. During hepatectomy, the camera was shifted to the right, allowing a frontal view of the liver transection plane and appropriate alignment of the instruments for parenchymal transection. In contrast, during the pancreatic phase, the camera was shifted to the left, providing a frontal view of the key steps of distal pancreatectomy, including retroperitoneal dissection, handling of the splenic vessels, and splenic mobilization. Thus, while sharing the same ports, this strategy optimized both the visual and instrument axes according to each procedure and may have contributed to maintaining both visibility and operability during simultaneous hepatopancreatic resection. Therefore, this case not only demonstrates the feasibility of robot-assisted simultaneous hepatectomy and distal pancreatectomy but also suggests that a strategic setup incorporating ICG fluorescence imaging and port shifting may enhance the practical utility of this approach.

Pathologically, a notable observation was the discordant treatment response between sites; liver metastases became scarred, whereas pancreatic primary and lymph node metastases remained viable. A previous study also reported a tendency for Ki-67 indices to be higher in metastatic or recurrent liver lesions than in primary pancreatic tumors.[19] This finding underscores the fact that radiological/biological responses may differ between NELM and primary tumors, potentially reflecting tumor heterogeneity or microenvironmental differences. This discrepancy also indicates that the radiological disappearance of liver lesions does not necessarily imply a uniform treatment effect across all disease sites. Therefore, even when liver lesions respond dramatically, persistent primary and nodal diseases should be carefully reassessed, and surgical intervention should not be delayed once resectability is achieved.

CONCLUSIONS

In patients with PanNET presenting with multiple liver metastases that are initially not amenable to curative-intent resection, a sustained response to combined locoregional therapy and systemic treatment may downstage the disease and permit curative-intent conversion surgery. Early recognition of resectability and timely surgical decision-making are crucial. Robot-assisted simultaneous distal pancreatectomy with lymphadenectomy and hepatectomy is feasible and may offer a minimally invasive option for carefully selected patients.

ACKNOWLEDGMENTS

We would like to thank Editage (www.editage.jp) for English language editing.

DECLARATIONS

Funding

No funding was received for this work.

Authors' contributions

MY, YU, TI, MI, and GS conceived and designed the study.
YY contributed to the pathological diagnosis and analysis.
GS contributed to the conception and design from the surgeons' perspective.
YY also contributed to the conception and design as a pathologist. MY drafted the manuscript.
All authors critically reviewed and revised the manuscript for important intellectual content and approved the final version.
All authors agree to be held accountable for all aspects of the work.

Availability of data and materials

The authors declare that all data related to this study are available in the manuscript.

Ethics approval and consent to participate

The ethics committee of Toyota Kosei Hospital waived the requirement for ethics approval for this single-patient case report. All procedures were performed in accordance with the principles of the Declaration of Helsinki. Written informed consent was obtained from the patient.

Consent for publication

Informed consent for publication of this case report was obtained from the patient.

Competing interests

The authors declare that they have no competing interests.

REFERENCES

1) Del Rivero J, Perez K, Kennedy EB, et al. Systemic therapy for tumor control in metastatic well-differentiated gastroenteropancreatic neuroendocrine tumors: ASCO guideline. J Clin Oncol 2023; 41: 5049–67.
2) Kos-Kudła B, Castaño JP, Denecke T, et al. European Neuroendocrine Tumour Society (ENETS) 2023 guidance paper for nonfunctioning pancreatic neuroendocrine tumours. J Neuroendocrinol 2023; 35: e13343.
3) Sullivan KM, Fong Y. Multivisceral resection in robotic liver surgery. Cancers (Basel) 2022; 14: 355.
4) Frilling A, Modlin IM, Kidd M, et al. Recommendations for management of patients with neuroendocrine liver metastases. Lancet Oncol 2014; 15: e8–21.
5) Fairweather M, Swanson R, Wang J, et al. Management of neuroendocrine tumor liver metastases: long-term outcomes and prognostic factors from a large prospective database. Ann Surg Oncol 2017; 24: 2319–25.
6) Calin ML, Sadiq A, Arevalo G, et al. The first case report of robotic multivisceral resection for synchronous liver metastasis from pancreatic neuroendocrine tumor: a case report and literature review. J Laparoendosc Adv Surg Tech A 2016; 26: 816–24.
7) Chiapponi C, Lürssen N, Cremer B, et al. Peptide receptor radionuclide therapy as a two-step strategy for initially unresectable liver disease from neuroendocrine tumors: a single-center experience. Endocrine 2020; 70: 187–93.
8) Yumoto S, Nakagawa S, Hayashi H, et al. Multimodal therapy with aggressive hepatectomy, everolimus, and octreotide for metastatic pancreatic neuroendocrine neoplasm enables 10-year survival. Clin J Gastroenterol 2022; 15: 1136–44.
9) Saadoun J-E, Vanbrugghe C, Fara R, et al. Robotic right posterior sectionectomy by intrafascial approach for pancreas neuroendocrine liver metastasis. Ann Surg Oncol 2023; 30: 4276.
10) Umino R, Nara S, Kobayashi N, et al. Pathological complete response of initially unresectable multiple liver metastases achieved using combined peptide receptor radionuclide therapy and somatostatin analogs following pancreatic neuroendocrine tumor resection: a case report. Surg Case Rep 2024; 10: 40.
11) Sakaki K, Chiba M, Iijima K, et al. Grade 3 pancreatic neuroendocrine tumor refractory to chemotherapy successfully treated with peptide receptor radionuclide therapy leading to conversion surgery. Intern Med 2025; 64: 679–85.
12) Aoki T, Kubota K, Kiritani S, et al. Survey of surgical resections for neuroendocrine liver metastases: a project study of the Japan Neuroendocrine Tumor Society (JNETS). J Hepatobiliary Pancreat Sci 2021; 28: 489–97.
13) Spolverato G, Bagante F, Aldrighetti L, et al. Management and outcomes of patients with recurrent neuroendocrine liver metastasis after curative surgery: an international multi-institutional analysis. J Surg Oncol 2017; 116: 298–306.
14) Grote R, Schmoll E, Döhring W, et al. Chemo-embolisation of carcinoid metastases in the liver. Rofo 1990; 153: 595–600. (in German)
15) Nanno Y, Toyama H, Ueshima E, et al. Transarterial chemoembolization for liver metastases of a pancreatic neuroendocrine neoplasm: a single-center experience. Surg Today 2023; 53: 1396–400.
16) Gudmundsdottir H, Pery R, Graham RP, et al. Safety and outcomes of combined pancreatic and hepatic resections for metastatic pancreatic neuroendocrine tumors. Ann Surg Oncol 2022; 29: 6949–57.
17) Bhat AS, Farrugia A, Marangoni G, et al. Multivisceral robotic resection: a glimpse into the future of minimally invasive abdominal surgery. BMJ Case Rep 2020; 13: e234887.
18) Ushida Y, Sugawara G, Yamashita Y, et al. Optimizing indocyanine green positive staining with total liver volume-normalized dosing in robotic hepatectomy: an image-based analysis. J Robot Surg 2025; 20: 19.
19) Murakami M, Fujimori N, Matsumoto K, et al. Clinical implications of Ki-67 index, grade and hormonal changes in pancreatic neuroendocrine tumors: insights into tumor heterogeneity based on primary and secondary lesions. J Hepatobiliary Pancreat Sci 2026; 33: 141–50.