Clinical Case Reports

WILEY

Clinical Case Reports Open Access

CASE REPORT OPEN ACCESS

Serous Ovarian Carcinoma Presenting With Synchronous Breast Metastasis: A Case Report and Literature Review

Ramesh Omranipour[1,2] | Aysan Nozheh[3] | Saeid Esmaeilian[4] | Neda Karkeabadi[1,2] | Sanaz Zand[5] | Niloofar Tavasooliniyasari[1,2]

[1]Breast Diseases Research Center (BDRC), Cancer Institute, Tehran University of Medical Sciences, Tehran, Iran | [2]Department of Surgical Oncology, Cancer Institute, Tehran University of Medical Sciences, Tehran, Iran | [3]Department of Pathology, Cancer Institute, Imam Khomeini Hospital Complex, Tehran University of Medical Sciences, Tehran, Iran | [4]Medical Imaging Research Center, Shiraz University of Medical Sciences, Namazi Hospital, Namazi Square, Shiraz, Iran | [5]Department of General Surgery, Tehran University of Medical Sciences, Tehran, Iran

Correspondence: Niloofar Tavasooliniyasari (niloofar.tvs1988@gmail.com)

Received: 6 July 2026 | **Revised:** 23 October 2026 | **Accepted:** 5 November 2026

Keywords: breast metastasis | immunohistochemistry | ovarian malignancy | serous ovarian carcinoma

ABSTRACT

Synchronous breast metastasis from ovarian cancer is exceptionally rare. A 53-year-old woman with FIGO IIIC high-grade serous ovarian carcinoma underwent cytoreductive surgery, chemotherapy, and breast radiotherapy. Immunohistochemistry confirmed metastatic disease. Complete response persisted for over 7 years before platinum-resistant recurrence, emphasizing accurate diagnosis and multimodal treatment in selected patients.

1 | Introduction

Ovarian cancer is the fifth leading cause of cancer-related mortality among women, largely due to frequent diagnosis at advanced stages when curative options are limited [1]. The most common site of metastasis is the peritoneal cavity via transcoelomic spread. Distant metastases, though less common, typically involve the pleura, liver, lungs, and lymphatic system. Secondary involvement of the breast from ovarian carcinoma is exceptionally rare, accounting for only 0.03% to 0.6% of all breast tumors [2]. Breast metastases usually appear in patients with a known history of ovarian cancer, often several years after the initial diagnosis [3, 4]. These cases often present as an aggressive, chemo-resistant disease, with a median overall survival of approximately 16 months [5, 6]. The lack of standard treatment guidelines makes therapeutic decision-making complex. We present a rare case of high-grade serous ovarian carcinoma (HGSOC) with a synchronously diagnosed breast metastasis, an incidental finding without prior clinical suspicion. We also review the literature to discuss the diagnostic and therapeutic challenges.

2 | Case History/ Examination

A 53-year-old perimenopausal woman (G3P3) presented to the gynecology clinic in 2015 with a history of progressive abdominal distension, pelvic pressure, and diffuse abdominal pain. Her past medical and family histories were non-contributory for breast or ovarian cancer.

On physical examination, the patient exhibited mild tenderness on deep abdominal palpation, with no evidence of abdominal distension or ascites. Pelvic exam identified bilateral adnexal masses. Serum CA-125 was markedly elevated at 3142.5 U/mL (reference: < 35 U/mL).

3 | Differential Diagnosis, Investigations, and Treatment

Abdominopelvic magnetic resonance imaging (MRI) confirmed large, complex bilateral adnexal masses (right: 115 × 70 mm; left: 90 × 50 mm), moderate ascites, and no evidence of parenchymal

This is an open access article under the terms of the Creative Commons Attribution License, which permits use, distribution and reproduction in any medium, provided the original work is properly cited.

© 2026 The Author(s). *Clinical Case Reports* published by John Wiley & Sons Ltd.

Key Clinical Message

This case highlights that ovarian cancer can metastasize synchronously to the breast, mimicking a primary breast malignancy. Utilizing immunohistochemistry (WT1+/PAX8+) is critical for accurate differentiation to prevent mis-staging and guide appropriate systemic therapy. Furthermore, it demonstrates that an aggressive multimodal approach, including local treatment of the metastasis, can yield an unexpectedly prolonged survival of over 7 years.

liver or lung metastases. A preoperative breast ultrasound identified a well-circumscribed, oval, hypoechoic 15 mm mass in the upper outer quadrant of the left breast, categorized as BI-RADS 4a (suspicious).

The patient underwent comprehensive surgical staging and cytoreduction, including total abdominal hysterectomy, bilateral salpingo-oophorectomy, infra-colic omentectomy, appendectomy, and pelvic and para-aortic lymphadenectomy. Intraoperative frozen section exam of the left ovarian mass was consistent with high-grade carcinoma. An excisional biopsy of the left breast mass was performed concurrently.

Final histopathology confirmed high-grade serous cystadenocarcinoma of the ovaries, with involvement of the omental and appendiceal serosa. All resected lymph nodes (0/28) and ascitic fluid cytology were negative for malignancy, leading to a final surgical staging of FIGO Stage IIIC (Figure 1). Critically, histopathological examination of the breast mass revealed a metastatic deposit of high-grade serous carcinoma, morphologically identical to the primary ovarian tumor (Figure 2). Immunohistochemical (IHC) staining of both lesions demonstrated an identical profile: positive for WT1, PAX8, CK7, and CA-125, and negative for CK20, GATA3, and ER. This profile unequivocally confirmed a Müllerian (ovarian) origin, ruling out a primary breast cancer (Figures 3 and 4).

Postoperatively, the patient received 6 cycles of adjuvant chemotherapy with carboplatin (AUC 5) and docetaxel (75 mg/m^2). Following a multidisciplinary tumor board recommendation, she also received adjuvant radiotherapy (40 Gy in 15 fractions) to the left breast surgical bed to consolidate local control. She tolerated treatment well and achieved a complete clinical and radiological response, entering a prolonged surveillance period. No significant adverse events were recorded from the adjuvant chemotherapy or radiotherapy regimens.

The patient remained in remission for approximately 7 years. In May 2022, she re-presented with jaundice, nausea, and vomiting. CT imaging revealed a new mass in the head of the pancreas, recurrent ascites, and extensive peritoneal carcinomatosis with lymphadenopathy. A percutaneous biopsy confirmed recurrent HGSOC. Given a platinum-free interval exceeding 6 years, she was

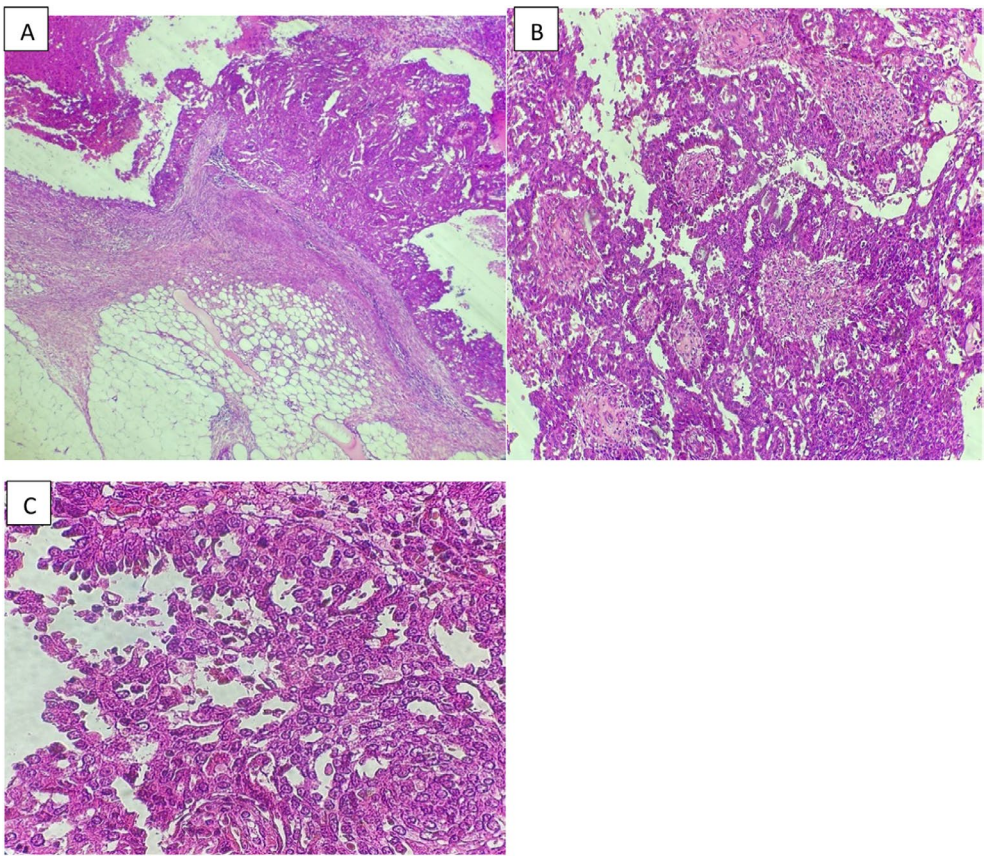

FIGURE 1 | (A–C) Display histological sections stained with hematoxylin and eosin (H&E) at magnification ×40, ×100 and ×400 respectively; sections show breast tissue involved by high grade metastatic ovarian serous carcinoma.

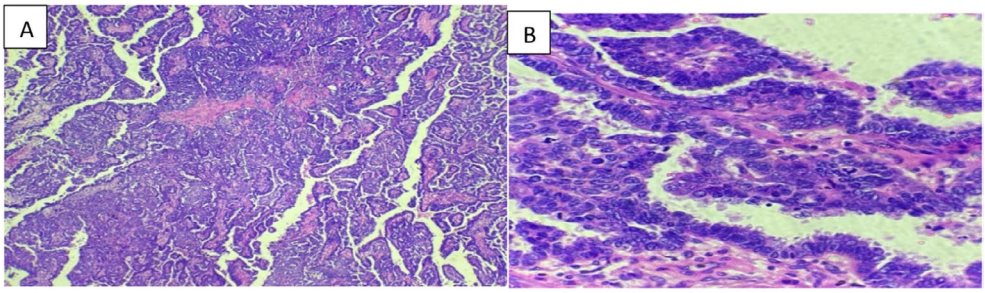

FIGURE 2 | (A, B) Display histological sections stained with hematoxylin and eosin (H&E) at magnification ×40 and ×400 respectively; sections show ovarian tissue involved by high-grade serous carcinoma.

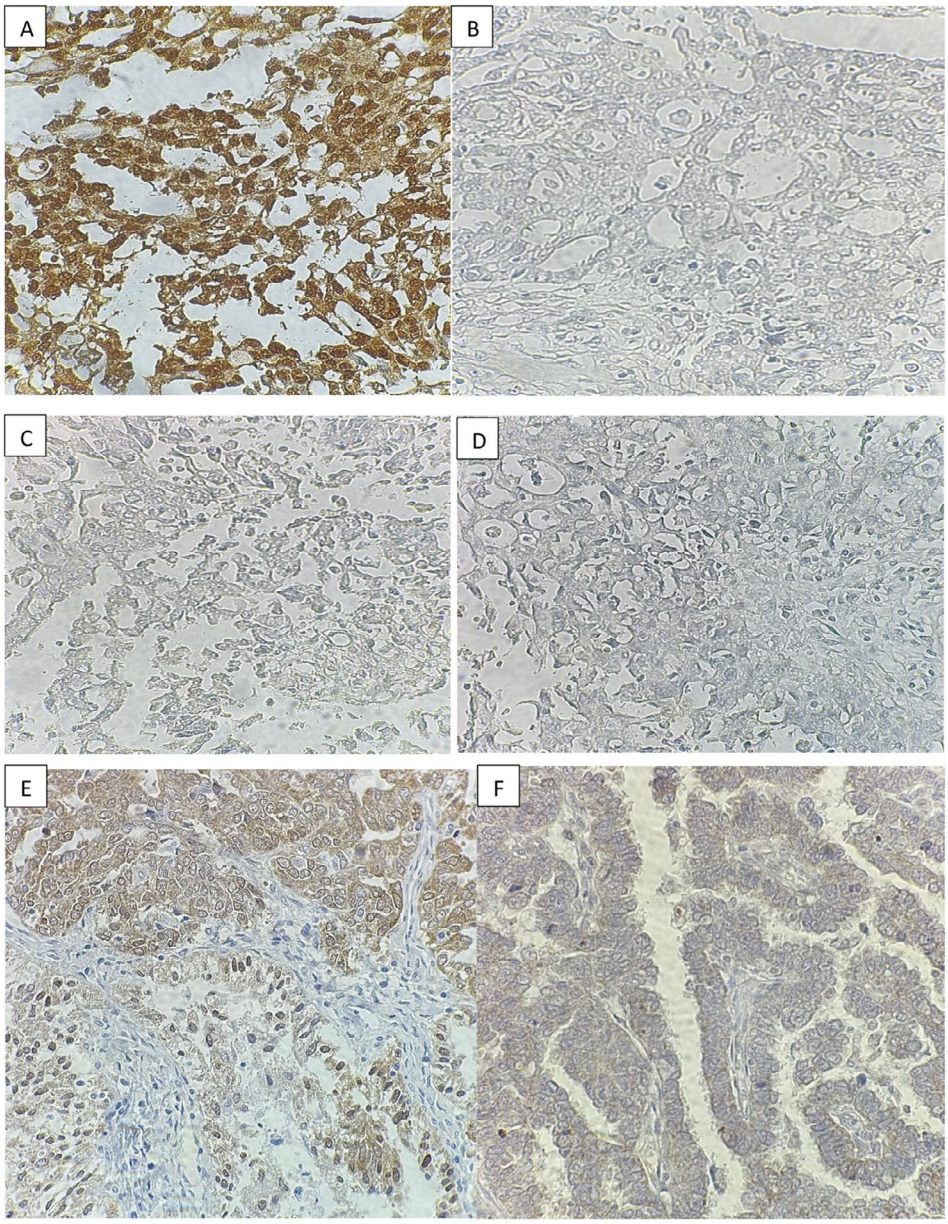

FIGURE 3 | Immunohistochemistry staining at magnification x400 in metastatic ovarian serous carcinoma in the breast mass: (A) Ki67, about 90% in hotspot, (B) HER2, Negative (score 0), (C) ER, Negative, (D) PR, Negative, (E) PAX8, Positive in tumor cells, (F) GATA3, Negative in tumor cell.

initially treated with carboplatin and gemcitabine. However, she demonstrated rapid disease progression after 2 cycles, indicating acquired platinum resistance. She was switched to topotecan but continued to progress clinically. The focus of care was transitioned to best supportive care, and the patient passed away in July 2025 from complications of widespread metastatic disease (Figure 5).

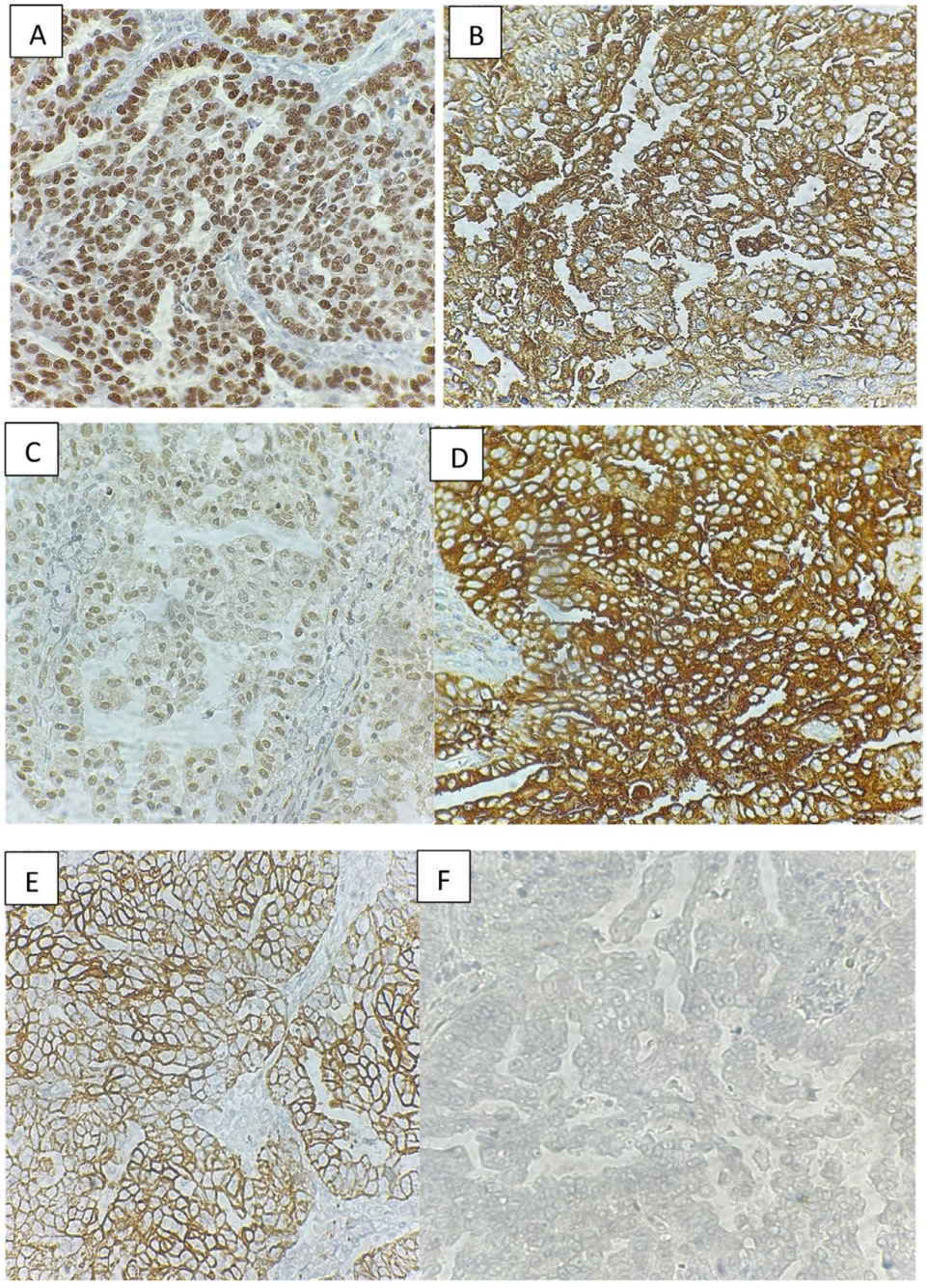

FIGURE 4 | Immunohistochemistry staining at magnification x400 in serous carcinoma of the ovary, (A) P53, Strong and diffuse positive (mutant), (B) CA125, Positive, (C) WT1, Positive, (D) EMA, Positive, (E) CK7, Positive, (F) CK20, Negative.

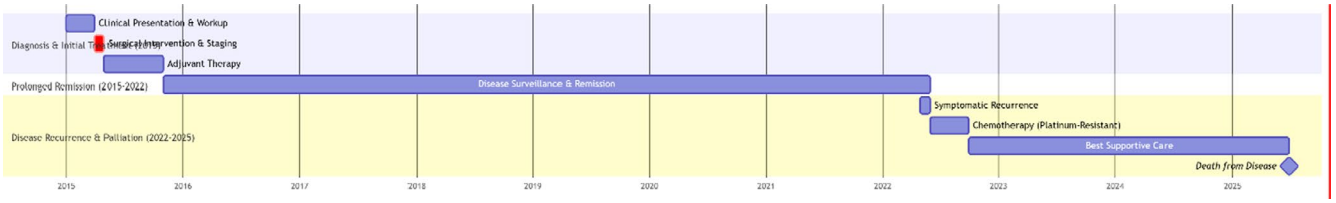

FIGURE 5 | Clinical course timeline.

4 | Discussion

HGSOC is an aggressive malignancy characterized predominantly by transcoelomic dissemination within the peritoneal cavity, although hematogenous and lymphatic spread to distant organs may also occur [1, 5]. Breast metastasis from ovarian cancer is an exceptionally rare clinical entity, with an estimated incidence of only 0.07% among patients with ovarian malignancy [6]. It typically presents as a metachronous lesion, often occurring years after the initial diagnosis, with a reported latency period ranging from 0 to 16 years and a mean of approximately 2 years [3, 7, 8]. In contrast, our case is notable for its synchronous presentation, discovered incidentally during preoperative staging, which adds to the limited pool of such reports in the literature.

The diagnostic process relied heavily on immunohistochemistry (IHC), which played a pivotal role in distinguishing metastatic ovarian carcinoma from primary breast malignancy. The co-expression of WT1 and PAX8 is highly characteristic of Müllerian origin, while the absence of GATA3 and ER expression helped exclude primary breast carcinoma, particularly triple-negative breast cancer. This distinction is clinically significant, as it directly influences staging—from FIGO Stage IIIC to Stage IV—and alters the therapeutic approach accordingly [9].

Due to the rarity of this presentation, there are no standardized treatment guidelines. Management is typically individualized and may involve a combination of surgery, radiotherapy, and systemic chemotherapy [10]. In our case, a multimodal strategy was employed, including lumpectomy of the breast lesion, platinum/taxane-based systemic chemotherapy, and adjuvant external beam radiation of the breast. This aggressive approach may have contributed to the patient's remarkably long disease-free survival of 7 years and overall survival of approximately 10 years. It shows significant differences with the median 2-year survival rate (< 52.2%). Also, typical ranging is between 17% and 30%, depending on individual factors and treatment response [11].

To contextualize our findings, we conducted a systematic review of similar cases and assessed their quality using the JBI critical appraisal tool. The reviewed literature (see Tables 1 and 2) supports our conclusions, showing that survival after breast metastasis is highly variable. Notably, our patient's prolonged survival occurred in the setting of platinum-sensitive disease, whereas many reported cases involved platinum-resistant tumors at the time of breast metastasis. This underscores platinum sensitivity as a key prognostic factor and a potential determinant of long-term outcomes.

From a contemporary therapeutic perspective, molecular characterization of HGSOC, including germline and/or somatic BRCA1/2 testing and assessment of homologous recombination deficiency (HRD), has become increasingly important because these biomarkers may identify patients who are candidates for PARP inhibitor therapy. PARP inhibitors have demonstrated clinically meaningful benefits, particularly in patients with BRCA1/2-mutated or HRD-positive ovarian cancer. However, BRCA/HRD testing was not performed in our patient because of significant socioeconomic and financial limitations and limited access to molecular diagnostic testing and targeted therapies. Consequently, her potential eligibility for BRCA-directed treatment or PARP inhibition could not be assessed. The patient subsequently developed platinum-resistant recurrence and ultimately died of her disease. Importantly, the prolonged platinum-free interval of more than 7 years observed in our patient demonstrates the biological heterogeneity of advanced HGSOC despite the presence of an unusual metastatic site [20].

From a clinical perspective, this case highlights several important points. First, breast metastasis should be considered in patients with a history of ovarian cancer, even in the absence of symptoms. Second, IHC remains essential for accurate diagnosis and staging. Third, consolidative local therapy of oligometastases, including surgery and radiotherapy, may offer survival benefits in selected patients, even in the context of advanced disease. Based on this experience, we would advocate for a more proactive diagnostic and therapeutic approach in future similar cases.

The strengths of this report include its detailed diagnostic workup, long-term follow-up, and multidisciplinary management involving oncology, pathology, and surgical teams. However, limitations include the rarity of the condition, lack of standardized treatment protocols, and limited comparative data. Despite these challenges, our case suggests that aggressive local treatment may be justified in select patients.

5 | Conclusion and Results

This case illustrates the diagnostic challenge of a synchronous breast mass in a patient with ovarian cancer. A high index of suspicion and the judicious use of IHC are paramount for accurate diagnosis and staging. While the prognosis for ovarian cancer with distant metastasis is generally poor, an aggressive, multimodal treatment strategy, including local control of the metastatic deposit, may be associated with prolonged survival in patients with platinum-sensitive disease. This report adds to the limited literature on this rare event and highlights the need for further research to establish optimal management protocols.

TABLE 1 | Clinical characteristics, management, and outcomes of reported cases of ovarian carcinoma with breast metastasis.

Author (Year)	Age	Clinical presentation	Ovarian histology	EOC stage at Dx	Time to breast mets	Presentation of breast mets	Treatment of breast mets	Adverse events	Platinum status at breast mets	Other metastatic sites	Survival after breast mets
Current Case (2025)	53	Progressive abdominal distension, pelvic pressure, and diffuse abdominal pain	High-Grade Serous	IIIC (de facto Stage IV)	Synchronous	Solitary, well-defined mass (BIRADS 4a)	Excisional Biopsy, Systemic CT (Carbo/Docetaxel), Adjuvant Breast RT	No significant adverse event	Sensitive (PFI > 6 months)	Appendix, Omentum	~10 years
Maeshima et al. (2021) [12]	69	Breast mass with microcalcifications on surveillance CT	Mixed Serous & Endocervical-type Mucinous (Seromucinous)	IIIC	9 years	Mass with microcalcifications, in situ-mimicking architecture on histology	Systemic CT (Carboplatin + Gemcitabine → Carboplatin + Doxorubicin)	Not Reported	Resistant (Recurrent disease)	Pleural nodules, Axillary LN (historical)	> 30 months (Alive, receiving best supportive care)
Tempfer et al. (2016)—Case 1 [13]	52	Palpable, painful breast mass	Serous	IIIC	38 months	Solitary, round mass with enlarged axillary LN	Lumpectomy, Systemic CT (Topotecan)	Not Reported	Resistant	Not Specified	2 months (Death)
Tempfer et al. (2016)—Case 2 [13]	51	Palpable, painful breast mass	Serous	IIIC	3 months	Solitary, lobulated mass	Mastectomy + Sentinel Node Biopsy, Systemic CT (Liposomal Doxorubicin)	Not Reported	Resistant	Not Specified	> 3 months (Alive, lost to follow-up)
Wang et al. (2020) [14]	40	Painless breast mass	Serous Cystadenocarcinoma	Not Specified	7 years	Large cystic mass (8 × 6 × 7 cm)	Lumpectomy, Systemic CT (Carboplatin + Paclitaxel)	Not Reported	Not Explicitly Stated	Not Specified	Lost to follow-up after 4 cycles of CT
Caruso et al. (2020) [10]	53	Recurrent disease with breast mass & LNs	High-Grade Serous	IIIC	24 months	Mass & Axillary LNs	Axillary RT, Multiple CT lines (Gem/Cis, Dox, Topotecan, Olaparib/Cediranib, Paclitaxel, Cisplatin)	Not Reported	Resistant (PFI 18 mos)	Peritoneal, Axillary, Supraclavicular LN	36 months (Death)
Dueño et al. (2024) [6]	59	Painful breast mass with specific characteristics	High-Grade Serous	IIIC	24 months	Symptomatic unilateral mass	Local RT only (23 Gy/4 fx)	No significant adverse event	Resistant	Abdomen, Chest, Cervical LN	> 24 months (Alive)
Abu-Tineh et al. (2020) [15]	54	Breast lump progressing to inflammatory cancer	Clear Cell	IIIA	14 months	Inflammatory breast cancer	Systemic CT, Local RT (30 Gy/10 fx)	Pneumonia, parapneumonic effusion	Not Explicitly Stated	Sternal, Mediastinal LN	24 months (Alive)
Antuono et al. (2018) [16]	54	Palpable, painful breast mass	High-Grade Serous	IIIC	24 months	Solitary, round mass	Systemic CT only	Not Reported	Not Explicitly Stated	None specified	5 months (Alive)

(Continues)

TABLE 1 | (Continued)

Author (Year)	Age	Clinical presentation	Ovarian histology	EOC stage at Dx	Time to breast mets	Presentation of breast mets	Treatment of breast mets	Adverse events	Platinum status at breast mets	Other metastatic sites	Survival after breast mets
Musa et al. (2022) [17]	Not Specified	Detailed breast symptoms and appearance	High-Grade Serous	IIIC	5 years	Bilateral inflammatory	Bilateral Breast RT (52 Gy/20 fx)	Significant radiation dermatitis and pain	Resistant	Bilateral Axillary LN	> 24 months (Alive with recurrence)
Laokulrath et al. (2024) [18]	48	Breast masses and unique areolar rash	Mucinous Carcinoma	Advanced (2022)	~1.5 years	Multiple right breast masses, areolar rash (mimicking Paget's)	Systemic CT (TCH regimen after HER2+ result)	Not Reported	Resistant (Short response to 2nd line)	Peritoneum, Omentum, Diaphragm, Liver capsule, Colon serosa	Not specified (Alive at time of report)
Chiva et al. (2022) [19]	79	Massive breast infiltration with skin ulceration	High-Grade Serous	IIIC	> 7 years	Massive left breast infiltration, skin necrosis/ulceration	Palliative Radical Mastectomy	Not Reported	Resistant (Multiple recurrences)	Inguinal, Retroperitoneal, Supraclavicular, Axillary LN	2 months (Death)

Abbreviations: Carbo, Carboplatin; CT, Chemotherapy; Dx, Diagnosis; EOC, Epithelial Ovarian Cancer; fx, fractions; LN, Lymph Nodes; Mets, Metastasis; PFI, Platinum-Free Interval; RT, Radiotherapy.

TABLE 2 | Quality assessment of included case reports using the JBI Critical Appraisal Checklist.

Case report	Q1. Demographics	Q2. History & timeline	Q3. Clinical presentation	Q4. Diagnostics & results	Q5. Intervention/ treatment	Q6. Post-intervention condition	Q7. Adverse events	Q8. Takeaway lessons
Maeshima et al. (2021) [12]	Yes	Yes	Yes	Yes	Yes	Yes	No	Yes
Tempfer et al. (2016) [13]	Yes	Yes	Yes	Yes	Yes	Partially (Case 2 lost to follow-up)	No	Yes
Wang et al. (2020) [14]	Yes	Partially	Yes	Yes	Yes	Unclear (Lost to follow-up)	No	Yes
Caruso et al. (2020) [10]	Yes	Yes	Yes	Yes	Yes	Yes	Unclear	Yes
Dueño et al. (2024) [6]	Yes	Yes	Yes	Yes	Yes	Yes	Yes	Yes
Abu-Tineh et al. (2020) [15]	Yes	Yes	Yes	Yes	Yes	Yes	Yes	Yes
Antuono et al. (2018) [16]	Yes	Partially	Yes	Yes	Yes	Unclear	No	Yes
Musa et al. (2022) [17]	No	Partially	Yes	Yes	Yes	Yes	Yes	Yes
Laokulrath et al. (2024) [18]	Yes	Yes	Yes	Yes	Yes	Yes	No	Yes
Chiva et al. (2022) [19]	Yes	Yes	Yes	Yes	Yes	Yes	No	Yes

Author Contributions

Ramesh Omranipour: conceptualization, supervision, writing – review and editing. **Aysan Nozheh:** data curation. **Saeid Esmaeilian:** writing – original draft, writing – review and editing. **Neda Karkeabadi:** writing – original draft, writing – review and editing, data curation. **Sanaz Zand:** writing – review and editing. **Niloofar Tavasooliniyasari:** data curation, writing – original draft, writing – review and editing.

Funding

The authors have nothing to report.

Ethics Statement

The case report does not need to ethically confirm in our institute.

Consent

A written consent was obtained from the patient in Persian (native language).

Conflicts of Interest

The authors declare no conflicts of interest.

Data Availability Statement

The data that support the findings of this study are available from the corresponding author upon reasonable request.

References

1. M. Yousefi, S. Dehghani, R. Nosrati, et al., "Current Insights Into the Metastasis of Epithelial Ovarian Cancer—Hopes and Hurdles," *Cellular Oncology (Dordrecht)* 43, no. 4 (2020): 515–538, https://doi.org/10.1007/s13402-020-00513-9.

2. M. A. Recine, M. T. Deavers, L. P. Middleton, E. G. Silva, and A. Malpica, "Serous Carcinoma of the Ovary and Peritoneum With Metastases to the Breast and Axillary Lymph Nodes: A Potential Pitfall," *American Journal of Surgical Pathology* 28, no. 12 (2004): 1646–1651, https://doi.org/10.1097/00000478-200412000-00015.

3. R. L. Klein, A. R. Brown, C. M. Gomez-Castro, et al., "Ovarian Cancer Metastatic to the Breast Presenting as Inflammatory Breast Cancer: A Case Report and Literature Review," *Journal of Cancer* 1 (2010): 27–31, https://doi.org/10.7150/jca.1.27.

4. Z. O. Ferguson-Steele, M. R. Kilgore, and D. L. Lam, "Ovarian Cancer Metastasis to the Breast: Radiologic-Pathologic Correlation," *Journal of Breast Imaging* 7, no. 4 (2025): 463–473, https://doi.org/10.1093/jbi/wbaf029.

5. N. Thomakos, M. Diakosavvas, N. Machairiotis, Z. Fasoulakis, P. Zarogoulidis, and A. Rodolakis, "Rare Distant Metastatic Disease of Ovarian and Peritoneal Carcinomatosis: A Review of the Literature," *Cancers (Basel)* 11, no. 8 (2019): 1044, https://doi.org/10.3390/cancers11081044.

6. S. Dueño, R. Stein, M. Jamal, G. Lewis, and K. Hew, "Metastasis of Serous Ovarian Carcinoma to the Breast: A Case Report and Review of the Literature," *Journal of Medical Case Reports* 18 (2024): 127, https://doi.org/10.1186/s13256-024-04445-y.

7. S. A. Williams, R. A. Ehlers, II, K. K. Hunt, et al., "Metastases to the Breast From Nonbreast Solid Neoplasms: Presentation and Determinants of Survival," *Cancer* 110, no. 4 (2007): 731–737, https://doi.org/10.1002/cncr.22835.

8. D. H. Moore, D. K. Wilson, J. A. Hurteau, K. Y. Look, F. B. Stehman, and G. P. Sutton, "Gynecologic Cancers Metastatic to the Breast," *Journal of the American College of Surgeons* 187, no. 2 (1998): 178–181, https://doi.org/10.1016/S1072-7515(98)00119-7.

9. P. Dursun, F. B. Yanik, E. Kuscu, M. Gultekin, and A. Ayhan, "Bilateral Breast Metastasis of Ovarian Carcinoma," *European Journal of Gynaecological Oncology* 30 (2009): 9–12.

10. G. Caruso, L. Musacchio, G. Santangelo, et al., "Ovarian Cancer Metastasis to the Breast: A Case Report and Review of the Literature," *Case Reports in Oncology* 13, no. 3 (2020): 1317–1324, https://doi.org/10.1159/000509770.

11. Y. Wang, X. Shan, H. Dong, M. Li, and Y. Yue, "Prediction for 2-Year Mortality of Metastatic Ovarian Cancer Patients Based on Surveillance, Epidemiology, and End Results Database," *Frontiers in Surgery* 9 (2022): 1001234, https://doi.org/10.3389/fsurg.2022.974536.

12. Y. Maeshima, T. Osako, H. Morizono, et al., "Metastatic Ovarian Cancer Spreading Into Mammary Ducts Mimicking an In Situ Component of Primary Breast Cancer: A Case Report," *Journal of Medical Case Reports* 15, no. 1 (2021): 79.

13. C. B. Tempfer, N. El Fizazi, H. Ergonenc, and W. Solass, "Metastasis of Ovarian Cancer to the Breast: A Report of Two Cases and a Review of the Literature," *Oncology Letters* 11, no. 6 (2016): 4008–4012, https://doi.org/10.3892/ol.2016.4514.

14. X. Wang and Y. Wang, "Metastasis of Ovarian Cancer to Breast: A Case Report and Review of Imaging Manifestations," *Cancer Management and Research* 12 (2020): 13095–13104, https://doi.org/10.2147/CMAR.S280795.

15. M. Abu-Tineh, H. Elmalik, and M. A. Yassin, "Metastatic Ovarian Cancer Presenting as Inflammatory Breast Cancer: A Case Report," *Case Reports in Oncology* 13, no. 2 (2020): 867–872, https://doi.org/10.1159/000508447.

16. L. Antuono, F. Angela, N. Luca, M. Giovanni, and C. Enrico, "Breast Metastasis From Ovarian Cancer: A Case Report," *Radiology Case Reports* 13, no. 6 (2018): 1166–1169, https://doi.org/10.1016/j.radcr.2018.08.008.

17. A. Musa, M. C. Joiner, S. Dzul, and S. R. Miller, "Metastatic Spread of Serous Ovarian Carcinoma to the Bilateral Breasts," *BMJ Case Reports* 15, no. 11 (2022): e251721, https://doi.org/10.1136/bcr-2022-251721.

18. N. Laokulrath, S. K. Lim, H. Y. Lim, M. Gudi, and P. H. Tan, "Metastatic Ovarian Mucinous Carcinoma to the Breast: Diagnostic Challenges and Pitfalls," *Frontiers in Oncology* 14 (2024): 1364011, https://doi.org/10.3389/fonc.2024.1364011.

19. L. Chiva, R. Marquez, and T. Castellanos, "Breast Metastases From a Serous Ovarian Carcinoma," *International Journal of Gynecological Cancer* 32, no. 8 (2022): 1086, https://doi.org/10.1136/ijgc-2022-003498.

20. R. Buonaiuto, G. Neola, A. Caltavituro, et al., "Efficacy of PARP Inhibitors in Advanced High-Grade Serous Ovarian Cancer According to BRCA Domain Mutations and Mutation Type," *Frontiers in Oncology* 14 (2024): 1412807, https://doi.org/10.3389/fonc.2024.1412807.