frontiers in Medicine

TYPE Hypothesis and Theory
PUBLISHED 05 October 2026
DOI 10.3389/fmed.2026.1929771

Check for updates

OPEN ACCESS

EDITED BY
Akingbolabo Daniel Ogunlakin,
Bowen University, Nigeria

REVIEWED BY
Ayobami Tosin Adegbenro,
University of Arizona, United States
Fisayo Owoeye,
Bowen University, Nigeria

*CORRESPONDENCE
Zhaoxing Tian
tjtzx@126.com

RECEIVED 06 July 2026
REVISED 14 September 2026
ACCEPTED 20 September 2026
PUBLISHED 05 October 2026

CITATION
You M, Liao X, Li X, Guan L and Tian Z (2026) Abdominal allergic reaction syndrome: a tentative definition. Front. Med. 13:1929771. doi: 10.3389/fmed.2026.1929771

COPYRIGHT
© 2026 You, Liao, Li, Guan and Tian. This is an open-access article distributed under the terms of the Creative Commons Attribution License (CC BY). The use, distribution or reproduction in other forums is permitted, provided the original author(s) and the copyright owner(s) are credited and that the original publication in this journal is cited, in accordance with accepted academic practice. No use, distribution or reproduction is permitted which does not comply with these terms.

Abdominal allergic reaction syndrome: a tentative definition

Meiyi You, Xinglan Liao, Xueqi Li, Lan Guan and Zhaoxing Tian*

Department of Emergency Medicine, Beijing Jishuitan Hospital, Capital Medical University, Beijing, China

Background: Some patients with acute abdominal pain present with imaging findings suggestive of severe intestinal pathology, yet they remain hemodynamically stable and respond to corticosteroids rather than surgery. Recognizing this pattern early can prevent unnecessary laparotomy.
Cases: Three female patients (aged 91, 78, and 57 years) admitted to the emergency department presented with acute abdominal pain and diffuse bowel wall edema on a CT scan. Despite alarming imaging results, all three patients remained hemodynamically stable. The symptoms improved rapidly with intravenous methylprednisolone, and all patients were discharged without surgery.
Conclusions: We propose Abdominal Allergic Reaction Syndrome (AARS) as a preliminary recognition framework for this clinico-radiological pattern. AARS is not intended to replace specific diagnoses such as immunoglobulin A (IgA) vasculitis or lupus enteritis. Rather, it serves as an early identifier at a stage when the underlying etiology remains unclear. The core features (hemodynamic stability and clinico-radiological mismatch, supported by normal lactate levels) may help emergency physicians avoid unnecessary surgery while proceeding with the diagnostic workup. The term "allergic" is used here in its broader immunological sense (encompassing all type I–IV hypersensitivity reactions) and is not restricted to IgE-mediated reactions.

KEYWORDS
abdominal pain, acute abdomen, corticosteroid, diagnostic framework, hypersensitivity

Introduction

Acute abdominal pain accounts for approximately 10% of emergency department visits globally (1). Current guidelines emphasize early cross-sectional imaging to identify structural anomalies requiring urgent surgery (2, 3), and emergency laparotomy itself carries risks for substantial morbidity and mortality, including a non-negligible rate of non-therapeutic procedures (4–6); in one series of 27 negative laparotomies performed for acute abdomen, three patients were ultimately found to have an autoimmune disease (5). A subset of patients presents a particular dilemma: the imaging results show severe diffuse bowel wall edema, ascites, and even portal venous gas, yet vital signs and lactate levels remain reassuringly normal.

Several immune-mediated conditions can produce this pattern. Eosinophilic gastroenteritis (EGE) (7), immunoglobulin A (IgA) vasculitis (8), and lupus enteritis (9) cause immune-driven intestinal inflammation that mimics a surgical abdomen on imaging but responds to corticosteroids. These are distinct diseases with different pathomechanisms, and each already has its own diagnostic criteria. However, the practical challenge emerges earlier: when a patient arrives with acute abdominal pain

and the specific etiology is not yet established, how should the emergency physician decide between surgical exploration and a trial of conservative management?

We propose the concept of Abdominal Allergic Reaction Syndrome (AARS) to address this clinical gap. It is not a new disease entity but a transitional recognition framework for the early, etiology-undefined stage of presentation. Its value lies in the interval between initial presentation and definitive diagnosis: identifying the pattern of hemodynamic stability and clinico-radiological mismatch, supported by normal lactate levels, may help clinicians identify patients who do not require surgery and spare them from unnecessary surgical procedures. Recognition of this pattern is not, by itself, an indication for corticosteroid therapy; when an immune-mediated etiology is reasonably suspected and competing infectious and surgical causes have been appropriately evaluated, corticosteroids may be considered on an individual basis while the targeted diagnostic workup proceeds.

Case presentations

Case 1

A 91-year-old woman with well-controlled type 2 diabetes mellitus and essential hypertension presented 12 h after the onset of periumbilical pain, nausea, and dizziness. She was afebrile (36.1 °C), hemodynamically stable (heart rate, 89 beats/min; blood pressure, 132/65 mmHg), and alert. The white blood cell (WBC) count was 5.93×10^9 cells/L (64% neutrophils) with a normal eosinophil count, and blood biomarker levels are given as follows: lactate, 1.1 mmol/L; C-reactive protein (CRP), 10.9 mg/L; and D-dimer, 1.18 mg/L fibrinogen equivalent units (FEU). Contrast-enhanced CT showed diffuse small bowel wall edema, mild bowel dilation, small-volume pelvic free fluid (Figure 1A), and a significant amount of intrahepatic portal venous gas (Figure 1B). The patient was intensively monitored in the emergency room, with abdominal signs assessed every hour, and was prepared for immediate surgery in the event of any deterioration occurring. No mesenteric vessel occlusion or perforation was identified. The patient received bowel rest, intravenous fluids, methylprednisolone 80 mg on day 1 and then 40 mg daily for days 2 and 3 (totally 3 days), and empirical imipenem. Autoimmune serology tests, immunoglobulin and complement measurements, and endoscopy with biopsy were not performed. Repeat CT at 48 h showed complete resolution of portal venous gas and marked reduction in bowel wall thickening (Figure 1C). Although antibiotics were used concurrently, the rapid improvement in radiological imaging results and symptom relief are more consistent with the effects of corticosteroids. The patient tolerated oral intake by day 5 and was discharged on day 6. At the 2-month follow-up, she remained asymptomatic.

Case 2

A 78-year-old woman with type 2 diabetes mellitus presented with 24 h of abdominal pain and one episode of melena. An examination showed only mild tenderness without peritoneal signs. The patient was afebrile and hemodynamically stable (heart rate, 97 beats/minute; blood pressure, 113/60 mmHg). The WBC count was 19.5×10^9 cells/L (88% neutrophils) with a normal eosinophil count, the lactate level was 1.3 mmol/L, and the CRP level was 21.95 mg/L. CT revealed small bowel wall edema in the lower abdomen and pelvis, mesenteric fat stranding, and free fluid (Figures 2A, B). No active bleeding, thrombosis, or perforation was seen. Autoimmune serology tests, immunoglobulin and complement measurements, and endoscopy with biopsy were not performed. The patient received bowel rest, methylprednisolone 80 mg daily for 3 days and then 40 mg daily for 4 days, and empirical antibiotics. Pain resolved within 48 h. Follow-up CT at 2 weeks confirmed resolution of bowel wall edema (Figure 2C). She was discharged on day 8. At the 3-month follow-up, she remained asymptomatic.

Case 3

A 57-year-old woman with psoriasis and hearing–speech impairment developed periumbilical colicky pain 3 days after seafood consumption, along with bilateral limb edema, dizziness, and melena. She had been diagnosed with "acute gastroenteritis" elsewhere and received cefotaxime and metronidazole without improvement. On admission, she was afebrile and tachycardic (121 beats/min) and had a blood pressure of 143/94 mmHg, with

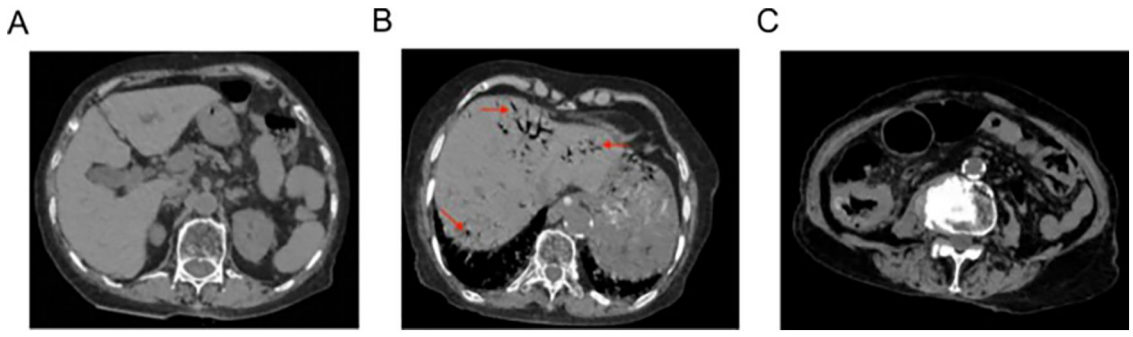

FIGURE 1
(A) Diffuse small bowel wall edema and pelvic free fluid. **(B)** Intrahepatic portal venous gas. **(C)** Resolution at 48 hours.

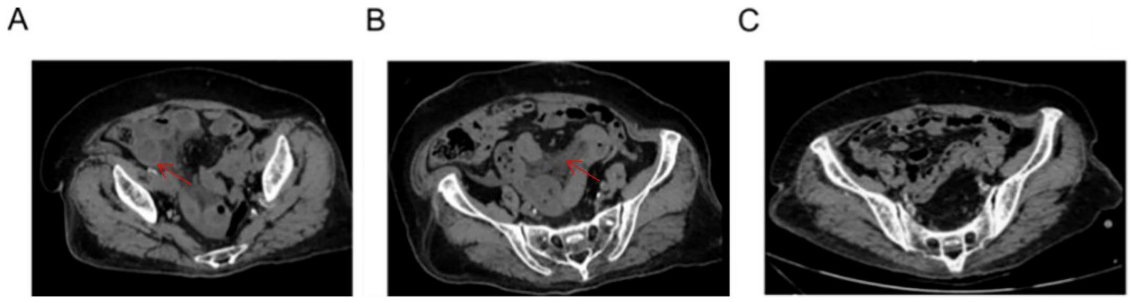

FIGURE 2
(A,B) Small bowel wall edema, mesenteric stranding, and free fluid. **(C)** Resolution at 2 weeks.

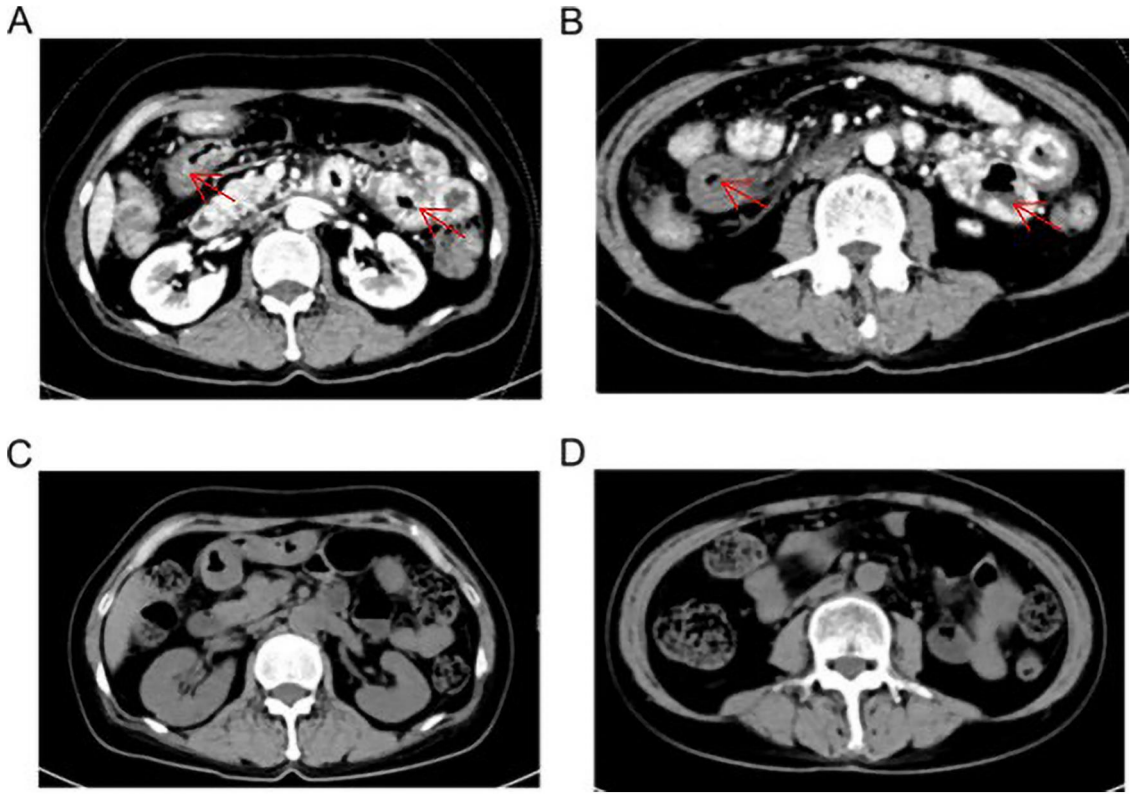

FIGURE 3
(A,B) Jejunal wall thickening and ascites. **(C,D)** Resolution after corticosteroid therapy.

bilateral limb edema. The WBC count was 24.6×10^9 cells/L (92% neutrophils), the albumin level was 29 g/L, and the D-dimer level was 6.1 mg/L FEU. The lactate level on admission was not measured. Lower-limb Doppler and CT angiography excluded thrombosis. Abdominal CT showed focal jejunal wall thickening and ascites (Figures 3A, B).

Broad-spectrum antibiotics were initiated (ertapenem, piperacillin–tazobactam, and later escalated to tigecycline). Despite 5 days of antibiotic therapy, the symptoms worsened. Further testing showed an erythrocyte sedimentation rate of 25.0 mm/h, a C-reactive protein level of 8.83 mg/dL, a total complement result of 60.0 U/mL, an immunoglobulin M level of 0.418 g/L, and an immunoglobulin E level of 3.1 IU/mL. Antinuclear and anti–double-stranded DNA antibodies were negative, and the eosinophil percentage was 0. Recurrent melena lowered hemoglobin levels to 83 g/L. Gastroscopy and colonoscopy with biopsy showed neither vasculitis nor granulomas. When an immune-mediated etiology was reconsidered, intravenous methylprednisolone 80 mg daily was started. Abdominal pain alleviated within 12 hours. Methylprednisolone was continued (80 mg daily for 3 days and then 40 mg daily for 5 days). Limb edema resolved, inflammatory marker levels decreased, and a follow-up CT scan confirmed resolution of jejunal wall thickening and ascites (Figures 3C, D). At the 7-year follow-up, no recurrence occurred.

Discussion

AARS: what it is and what it is not

These three cases share a clinical pattern that we term AARS: acute abdominal pain with imaging evidence of bowel wall edema, yet preserved hemodynamics and normal lactate levels, followed by rapid response to corticosteroids. The key differential considerations in our cases (IgA vasculitis, eosinophilic gastroenteritis, ischemic bowel, and Crohn's disease) were each considered and either supported or excluded based on clinical and laboratory features (10–13). The diagnostic evaluation of the three patients is summarized in Table 1.

It is worth noting that AARS does not replace these diagnoses. A patient eventually diagnosed with IgA vasculitis already has a well-defined disease entity with established criteria (10). AARS serves a different purpose: it addresses the window before that diagnosis is made. When a patient arrives in the emergency department with acute abdominal pain and imaging shows alarming bowel wall changes, the immediate question should not be "what specific disease is this?" Rather, it should be "does this patient need surgery now, or can I safely try conservative management?" AARS offers a preliminary answer to this question.

AARS is proposed as a clinical, syndrome-level diagnosis and not as a new disease entity. Its defining feature is a clinico-pathological process consistent with hypersensitivity, and the consistent effectiveness of antiallergic therapy constitutes a therapeutic (*ex juvantibus*) basis for the label: we observed a clinical phenomenon, and treatment directed toward hypersensitivity worked. Therefore, we do not speculate on the

TABLE 1 Clinical features, investigations, treatment, and outcomes of the three patients.

Feature	Case 1	Case 2	Case 3
Age/sex	91/F	78/F	57/F
Comorbidities	Type 2 diabetes mellitus; hypertension	Type 2 diabetes mellitus	Psoriasis; hearing–speech impairment
Onset to presentation	12 h	24 h	3 days
Vital signs	HR, 89 beats/min; BP, 132/65 mmHg; T, 36.1 °C	HR, 97 beats/min; BP. 113/60 mmHg	Afebrile; HR, 121 beats/min; BP, 143/94 mmHg; no signs of hypoperfusion
WBC (neutrophils, %)	5.93×10^9/L (64%)	19.5×10^9/L (88%)	24.6×10^9/L (92%)
Eosinophils	Normal	Normal	0%
Lactate (mmol/L)	1.1	1.3	Not measured
CRP	10.9 mg/L	21.95 mg/L	88.3 mg/L
D-dimer (mg/L FEU)	1.18	Not performed	6.1
Main CT findings	Diffuse small bowel wall edema, pelvic free fluid, and portal venous gas	Small bowel wall edema (lower abdomen/pelvis), mesenteric fat stranding, and free fluid	Focal jejunal wall thickening and ascites
Vascular assessment	No mesenteric vessel occlusion or perforation on CTA	No active bleeding, thrombosis, or perforation on CTA	Lower-limb Doppler US and CT angiography: no thrombosis
Immunological tests	Not performed	Not performed	ANA and anti-dsDNA: negative; total complement, 60.0 U/mL; IgM, 0.418 g/L; IgE, 3.1 IU/mL; ESR, 25 mm/h
Endoscopy/biopsy	Not performed	Not performed	Gastroscopy and colonoscopy with biopsy: no vasculitis or granulomas
Other relevant findings	—	—	Melena; hemoglobin nadir, 83 g/L
Corticosteroid regimen	Methylprednisolone 80 mg on day 1 and then 40 mg daily for days 2 and 3	Methylprednisolone 80 mg daily for 3 days and then 40 mg daily for 4 days	Methylprednisolone 80 mg daily for 3 days and then 40 mg daily for 5 days
Antibiotics	Imipenem (empirical)	Empirical antibiotics	Ertapenem, piperacillin–tazobactam, and then tigecycline
Time to response	Marked radiological improvement within 48 h	48 h	12 h
Length of stay (days)	6	8	39
Follow-up	Asymptomatic at 2 months	Asymptomatic at 3 months	No recurrence at 7 years

HR, heart rate; BP, blood pressure; CTA, computed tomography angiography; US, ultrasound; ANA, antinuclear antibody; ESR, erythrocyte sedimentation rate.

specific molecular mechanisms involved, which remain to be defined by future studies. The absence of eosinophilia or elevated IgE levels does not argue against a hypersensitivity process because many hypersensitivity reactions, particularly non–IgE-mediated ones, present without these findings. Similarly, tissue biopsy is neither suitable nor feasible for every patient, particularly older or frail emergency patients; the framework is designed precisely for the stage at which such information is not yet available.

The clinico-radiological mismatch

The three cases share a striking dissociation: CT findings that would typically raise concerns for surgical pathology (bowel wall edema, ascites, and even portal venous gas) but hemodynamic stability and a lactate level below 2.0 mmol/L.

Portal venous gas has historically been considered ominous, but accumulating evidence shows that in the absence of bowel necrosis signs, conservative management can be successful (2). Similarly, diffuse bowel wall edema, although concerning, may reflect immune-mediated inflammation rather than irreversible ischemia. The crucial distinction in our cases was the combination of stable vitals, normal lactate levels, and the absence of pneumatosis intestinalis or free air—features that, taken together, suggested a reversible process rather than surgical bowel compromise.

The findings on lactate levels fit this interpretation. Hypersensitivity reactions can themselves progress to shock, and shock induced by any cause increases lactate levels; conversely, patients with comparable abdominal imaging results due to extensive infectious inflammation typically show markedly elevated lactate levels. In the case of our patients, lactate levels remained normal (1.1 and 1.3 mmol/L in cases 1 and 2, respectively), supporting, although not proving, a non-ischemic, non-infectious process. A normal serum lactate level does not, however, by itself exclude early mesenteric ischemia or other significant surgical pathologies; lactate is therefore a supporting feature of the framework rather than a mandatory criterion. The hemodynamic course points the same way: had the abdominal pathology implied by the imaging results been infectious or surgical in nature, hemodynamic compromise would be expected, yet our patients remained stable throughout. An isolated heart rate of 121 beats/minute with normal blood pressure and no signs of hypoperfusion, as in case 3, does not constitute hemodynamic instability. The speed of the response to corticosteroids reinforces the mismatch further: infectious diseases do not resolve within hours to days of steroid initiation.

Immune-mediated conditions underlying AARS

Several established conditions can produce AARS.

IgA vasculitis (Henoch–Schönlein purpura) is a systemic IgA-mediated small vessel vasculitis with gastrointestinal involvement in over half of the patients (10). Intestinal leukocytoclastic vasculitis produces edema and pain that can be severe enough to mimic a surgical abdomen (8). Corticosteroids can rapidly reduce inflammatory edema and alleviate pain (14, 15).

EGE is characterized by eosinophilic infiltration of the gastrointestinal tract (11). Glucocorticoids are the preferred conservative treatment, with typical response within days (16–18). A diagnostic–therapeutic trial of corticosteroids can provide useful information even before biopsy results are available.

Lupus enteritis is an abdominal manifestation of systemic lupus erythematosus (SLE) and can be the sole presenting feature of the disease (19). Enhanced CT typically shows bowel wall thickening ("target sign"), mesenteric vascular congestion ("comb sign"), and ascites. Most patients respond rapidly to steroid therapy (20, 21).

Eosinophilic granulomatosis with polyangiitis (EGPA) can also involve the gastrointestinal tract (22). Notably, cases of EGPA-associated acute cholecystitis diagnosed preoperatively have improved with the use of glucocorticoids alone, whereas those diagnosed postoperatively had more complications (23), underscoring the value of preoperative recognition.

Pathophysiological considerations

The favorable response to corticosteroids and the absence of systemic decompensation suggest that AARS involves localized immune-mediated microvascular dysfunction and intestinal wall edema, rather than progressive structural damage. Glucocorticoids suppress excessive release of inflammatory mediators, reduce capillary permeability, and relieve intestinal wall edema (24, 25). However, their precise mechanisms remain unclear. The allergic/immunological evidence in this case is insufficient, and the immunological nature of AARS still needs to be verified through prospective studies.

The treatment sequence supports this interpretation. In case 3, symptoms worsened during the 5 days of escalating broad-spectrum antibiotics and they improved within 12 h of corticosteroid initiation. Had the process been a conventional bacterial infection, effective antibiotics should have produced improvement, and corticosteroids would not be expected to resolve an uncontrolled infectious process and they might aggravate it. The rapid and sustained response to corticosteroids therefore argues for an immune-mediated, rather than, infectious mechanism. Nonetheless, we acknowledge that in cases 1 and 2, antibiotics were given concurrently, and therefore, the contribution of each treatment could not be fully separated; we read the steroid response as supportive and not confirmatory.

AARS: a preliminary diagnostic framework

Based on our three cases and the literature on immune-mediated abdominal conditions, we propose a preliminary recognition framework:

Core features

1. Hemodynamic stability: normal blood pressure without progressive tachycardia; isolated tachycardia with normal

blood pressure and no signs of hypoperfusion does not constitute instability.
2. Clinico-radiological mismatch: imaging shows diffuse bowel wall edema, ascites, or portal venous gas, but clinical severity does not match the imaging alarm.

Supporting features

1. Lactate level <2.0 mmol/L: an elevated lactate level is associated with bowel ischemia and adverse outcomes (26), but a normal level does not exclude early or intermittent ischemia; this feature is supportive and not mandatory.
2. No evidence of mechanical obstruction or active bleeding in a contrast-enhanced CT scan.
3. Inflammatory markers may be normal or elevated without corresponding organ dysfunction.
4. Poor response to empirical antibiotics alone.
5. Findings suggestive of immune-mediated conditions (eosinophilia, elevated levels of IgE and autoimmune markers, and a history of atopic or autoimmune disease); their absence does not exclude a hypersensitivity process.

Caveats

1. Hemodynamic instability, lactate level >2.0 mmol/L, pneumatosis intestinalis, or clear peritoneal signs should prompt surgical evaluation.
2. AARS is a transitional framework and not a final diagnosis; workup for specific etiologies must proceed in parallel.
3. These criteria are derived from three cases and require prospective validation.

Management principles

All three patients received conservative management with corticosteroids, bowel rest, and intravenous fluids. In each case, the decision to start corticosteroids followed the same reasoning: empirical anti-infective therapy had failed or was deemed insufficient. The diffuse and uniform nature of the bowel involvement was considered more consistent with an immune-mediated process than with conventional bacterial infections, and after careful assessment, we adjudicated that corticosteroids were unlikely to cause adverse effects and were likely to benefit the patient. Symptom reduction occurred within 12–48 h. The general approach is given as follows:

1. Close hemodynamic monitoring,
2. Bowel rest with intravenous fluid resuscitation,
3. Corticosteroid therapy, with dose individualized to severity,
4. Serial monitoring of lactate and inflammatory marker levels,
5. Repeat imaging if the clinical status changes, and
6. Concurrent workup for the underlying etiology (autoimmune serology, allergy testing, and endoscopy/biopsy as appropriate).

The AARS framework does not preclude surgical consultation. Any clinical deterioration, new peritoneal signs, or failure to alleviate symptoms should trigger surgical reassessment. An equally important factor is dynamic re-evaluation: serial abdominal examinations, repeat lactate measurement, and repeat imaging whenever the clinical course is concerning. Such a disciplined reassessment allows the framework to avoid misdiagnosis without encouraging overtreatment; this balance (avoiding unnecessary laparotomy without delaying necessary surgery) is the purpose of this framework.

Conclusions

AARS is proposed as a preliminary recognition framework and not as a new diagnosis, for identifying patients who present with acute abdominal pain, preserved hemodynamics, and imaging findings disproportionate to clinical severity, while being supported by normal lactate levels. Its purpose is to help emergency physicians recognize patients who do not require surgery so that unnecessary surgical procedures can be avoided, with the definitive diagnostic workup proceeding in parallel. Corticosteroids may be considered on an individual basis when an immune-mediated etiology is reasonably suspected and competing infectious and surgical causes have been evaluated.

Data availability statement

The raw data supporting the conclusions of this article will be made available by the authors without undue reservation.

Ethics statement

The studies involving humans were approved by the Ethics Committee of Beijing Jishuitan Hospital, Capital Medical University. The studies were conducted in accordance with the local legislation and institutional requirements. The participants provided their written informed consent to participate in this study. Written informed consent was obtained from the individual(s) for the publication of any potentially identifiable images or data included in this article.

Author contributions

MY: Data curation, Writing – original draft. XiL: Data curation, Writing – original draft. XuL: Formal analysis, Writing – review & editing. LG: Writing – review & editing. ZT: Conceptualization, Writing – review & editing.

Funding

The author(s) declared that financial support was received for this work and/or its publication. This work was supported by the Beijing Jishuitan Hospital Academic Leader Fund (grant No. XKDTR20230*). The funder had no role in study design, data

collection and analysis, decision to publish, or preparation of the manuscript.

Conflict of interest

The author(s) declared that this work was conducted in the absence of any commercial or financial relationships that could be construed as a potential conflict of interest.

Generative AI statement

The author(s) declared that generative AI was not used in the creation of this manuscript.

Any alternative text (alt text) provided alongside figures in this article has been generated by Frontiers with the support of artificial intelligence, and reasonable efforts have been made to ensure accuracy, including review by the authors, wherever possible. If you identify any issues, please contact us.

Publisher's note

All claims expressed in this article are solely those of the authors and do not necessarily represent those of their affiliated organizations, or those of the publisher, the editors and the reviewers. Any product that may be evaluated in this article, or claim that may be made by its manufacturer, is not guaranteed or endorsed by the publisher.

References

1. Yew KS, George MK, Allred HB. Acute abdominal pain in adults: evaluation and diagnosis. *Am Fam Physician*. (2023) 107(6):585–96.

2. Mayumi T, Yoshida M, Tazuma S, Furukawa A, Nishii O, Shigematsu K, et al. Practice guidelines for primary care of acute abdomen 2015. *J Hepatobiliary Pancreat Sci*. (2016) 23(1):3–36. doi: 10.1002/jhbp.303

3. Börner N, Kappenberger A-S, Weber S, Scholz F, Kazmierczak P, Werner J. The acute abdomen: structured diagnosis and treatment. *Dtsch Arztebl Int*. (2025) 122(5):137–44. doi: 10.3238/arztebl.m2025.0019

4. Barazanchi AWH, Xia W, MacFater W, Bhat S, MacFater H, Taneja A, et al. Risk factors for mortality after emergency laparotomy: scoping systematic review. *ANZ J Surg*. (2020) 90(10):1895–902. doi: 10.1111/ans.16082

5. Zhang LY, Liu ZW, Ma EL, Yu JC, Qiu HZ. Negative results of laparotomy for acute abdomen: causes and preventions. *Med J PUMCH*. (2015) 6(1):35–7. doi: 10.3969/j.issn.1674-9081.2015.01.007

6. Chhetri RK, Shrestha ML. A comparative study of pre-operative with operative diagnosis in acute abdomen. *Kathmandu Univ Med J (KUMJ)*. (2005) 3(2):107–10.

7. Lan H, Yang T, Zhou L, Lv J, Huang X. Eosinophilic gastroenteritis without identifiable allergens in an adult: a case report. *SAGE Open Med Case Rep*. (2025) 13:2050313X–241312935. doi: 10.1177/2050313X241312935

8. Sandhu K, McDonald K, Langmead L, Deb P. Terminal ileitis: a rare gastrointestinal manifestation of IgA vasculitis in a child. *BMJ Case Rep*. (2024) 17(5):e240990. doi: 10.1136/bcr-2020-240990

9. Muñoz-Urbano M, Sangle S, D'Cruz DP. Lupus enteritis: a narrative review. *Rheumatology (Oxford)*. (2024) 63(6):1494–501. doi: 10.1093/rheumatology/kead689

10. Audemard-Verger A, Pillebout E, Guillevin L, Thervet E, Terrier B. IgA vasculitis (Henoch-Schönlein purpura) in adults: diagnostic and therapeutic aspects. *Autoimmun Rev*. (2015) 14(7):579–85. doi: 10.1016/j.autrev.2015.02.003

11. Shoda T, Taylor RJ, Sakai N, Rothenberg ME. Common and disparate clinical presentations and mechanisms in different eosinophilic gastrointestinal diseases. *J Allergy Clin Immunol*. (2024) 153(6):1472–84. doi: 10.1016/j.jaci.2024.03.013

12. Ahmed M. Ischemic bowel disease in 2021. *World J Gastroenterol*. (2021) 27(29):4746–62. doi: 10.3748/wjg.v27.i29.4746

13. Torres J, Mehandru S, Colombel JF, Peyrin-Biroulet L. Crohn's disease. *Lancet*. (2017) 389(10080):1741–55. doi: 10.1016/S0140-6736(16)31711-1

14. Weiss PF, Feinstein JA, Luan X, Burnham JM, Feudtner C. Effects of corticosteroid on Henoch-Schönlein purpura: a systematic review. *Pediatrics*. (2007) 120(5):1079–87. doi: 10.1542/peds.2007-0667

15. Yi F, Bai Z, Li Y, Xu X, Guo X, Qi X. A good response to glucocorticoid for Henoch-Schönlein purpura with abdominal pain and gastrointestinal bleeding in an adult: a CARE case report. *Medicine (Baltimore)*. (2020) 99(1):e18602. doi: 10.1097/MD.0000000000018602

16. Li K-W, Ruan G-C, Liu S, Xu T-M, Ma Y, Zhou W-X, et al. Long-term prognosis and its associated predictive factors in patients with eosinophilic gastroenteritis. *World J Gastroenterol*. (2024) 30(2):146–57. doi: 10.3748/wjg.v30.i2.146

17. Liu L, Liang XY, He H, Huang H, Jia LP. Clinical features of eosinophilic gastroenteritis with ascites. *Z Gastroenterol*. (2013) 51(7):638–42. doi: 10.1055/s-0033-1335326

18. Chen MJ, Chu CH, Lin SC, Shih SC, Wang TE. Eosinophilic gastroenteritis: clinical experience with 15 patients. *World J Gastroenterol*. (2003) 9(12):2813–6. doi: 10.3748/wjg.v9.i12.2813

19. Chowichian M, Aanpreung P, Pongpaibul A, Charuvanij S. Lupus enteritis as the sole presenting feature of systemic lupus erythematosus: case report and review of the literature. *Paediatr Int Child Health*. (2019) 39(4):294–8. doi: 10.1080/20469047.2018.1504430

20. Chaparro CA, Bernal-Macías S, Muñoz OM. Lupus enteritis as systemic lupus erythematosus main manifestation: two case reports. *SAGE Open Med Case Rep*. (2024) 12:2050313X–241247433. doi: 10.1177/2050313X241247433

21. Matsuyama S, Fukuda A, Ohana M. Gastrointestinal: lupus enteritis with duodenojejunal fistula causing intestinal obstruction and gastrointestinal perforation. *J Gastroenterol Hepatol*. (2024) 39(2):220–1. doi: 10.1111/jgh.16373

22. Nguyen Y, Guillevin L. Eosinophilic granulomatosis with polyangiitis (Churg-Strauss). *Semin Respir Crit Care Med*. (2018) 39(4):471–81. doi: 10.1055/s-0038-1669454

23. Ozaka S, Kodera T, Tsutsumi K, Fukuda M, Iwao M, Hirashita Y, et al. Acute cholecystitis associated with eosinophilic granulomatosis with polyangiitis that responded to glucocorticoid therapy. *Intern Med*. (2023) 62(10):1501–6. doi: 10.2169/internalmedicine.0437-22

24. Reichardt SD, Amouret A, Muzzi C, Vettorazzi S, Tuckermann JP, Lühder F, et al. The role of glucocorticoids in inflammatory diseases. *Cells*. (2021) 10(11):2921. doi: 10.3390/cells10112921

25. Strehl C, Ehlers L, Gaber T, Buttgereit F. Glucocorticoids—all-rounders tackling the versatile players of the immune system. *Front Immunol*. (2019) 10:1744. doi: 10.3389/fimmu.2019.01744

26. Lange H, Jäckel R. Usefulness of plasma lactate concentration in the diagnosis of acute abdominal disease. *Eur J Surg*. (1994) 160(6–7):381–4.