Case Reports in Dermatological Medicine

WILEY

CASE REPORT OPEN ACCESS

Cutaneous Intravascular Large B-Cell Lymphoma Presenting as Hemophagocytic Lymphohistiocytosis

Shamsu S. Bello[1] | Joseph J. Mulvey[1] | Joanna Harp[2] | Cynthia M. Magro[2]

[1]Department of Pathology, Montefiore Medical Center, The University Hospital of Albert Einstein College of Medicine, Bronx, New York, USA | [2]Department of Dermatopathology, Weill-Cornell Medical College and New York Presbyterian Hospital, New York, New York, USA

Correspondence: Cynthia M. Magro (cym2003@med.cornell.edu)

Received: 31 March 2025 | **Revised:** 10 April 2026 | **Accepted:** 13 April 2026

Academic Editor: Semonti Nandi

Keywords: hemophagocytic lymphohistiocytosis | intravascular large B-cell lymphoma | non-Hodgkin lymphoma

ABSTRACT

Intravascular large B-cell lymphoma (IVLBCL) is an uncommon and aggressive subtype of non-Hodgkin lymphoma defined by the proliferation of large malignant B cells confined within small blood vessels. This neoplasm can present with different nonspecific symptoms, including fever, altered mental status, livedoid skin rashes, hepatosplenomegaly, and cytopenias, often complicating its diagnosis. The main categories are classical (formerly designated as Western), hemophagocytic variant (formerly designated as Asian), and primary cutaneous IVLBCL. A distinctly severe manifestation is hemophagocytic lymphohistiocytosis (HLH), a hyperinflammatory syndrome characterized by exaggerated immune activation and macrophage activation manifested by phagocytosis of hematopoietic cells including neutrophils, red blood cells, and platelets. We describe a 72-year-old female who presented with features reminiscent of an autoinflammatory syndrome including fever and hyperferritinemia followed by clinical features concerning for HLH. She developed a reticulated skin rash. Following skin biopsy, a diagnosis was rendered of IVLBCL complicated by HLH. The pathophysiology and other aspects of the literature pertaining to IVLBCL and HLH are reviewed.

1 | Introduction

Intravascular large B-cell lymphoma (IVLBCL) is a rare B-cell neoplasm that is restricted to intravascular growth pattern (particularly small-sized vessels) [1]. It classically presents as widespread disease in extranodal sites, with a preponderance for the bone marrow, but other organs can be affected [2]. Nodal involvement is not usually seen. It is an extremely uncommon type of lymphoma affecting both genders with a slight male predominance. It has an age-adjusted incidence rate of around 0.095 cases per 1,000,000 individuals in the United States, with an increasing incidence over time [3]. There are three types of IVLBCL described in the literature. The classical subtype is predominantly observed in Western countries and mainly presents with nonspecific symptoms such as fever of unknown origin, central nervous system involvement, and skin manifestations; it was formerly designated as the Western variant. The classical subtype may also involve other organs, leading to a wide range of clinical presentations [4, 5]. The second subtype is the one associated with hemophagocytic lymphohistiocytosis (HLH) which was formerly designated as the Asian variant, and it is characterized by pancytopenia, hepatosplenomegaly, and systemic inflammation. This form of IVLBCL usually lacks neurological abnormalities and skin manifestations [6]. There is a third variant which is the one confined to the skin compatible with primary cutaneous IVLBCL. It has a better prognosis compared to the classic and HLH variants.

The pathogenesis of IVLBCL-induced HLH is orchestrated by an excessive immune response. The neoplastic B-cells can trigger a hyperinflammatory state by producing high levels of cytokines

This is an open access article under the terms of the Creative Commons Attribution License, which permits use, distribution and reproduction in any medium, provided the original work is properly cited.

Copyright © 2026 Shamsu S. Bello et al. *Case Reports in Dermatological Medicine* published by John Wiley & Sons Ltd.

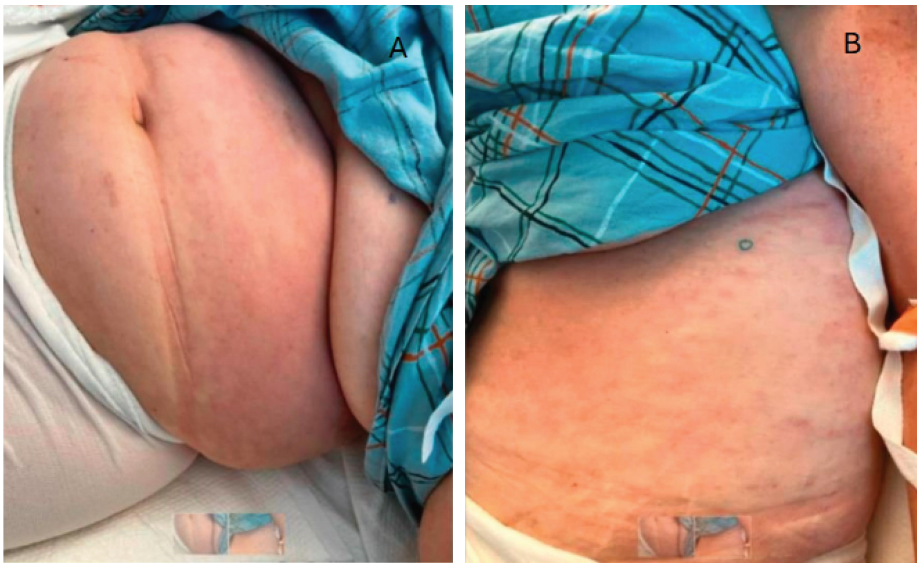

FIGURE 1 | (A, B) Photomicrograph showing livedo-like erythematous patches on the abdomen and trunk.

such as interferon-gamma (IFN-γ), tumor necrosis factor-alpha (TNF-α), and interleukin-6 (IL-6). These cytokines activate macrophages and cytotoxic T-cells, leading to hemophagocytosis, where activated macrophages ingest hematopoietic cells, such as red blood cells [7, 8]. In addition, genetic mutations involving the NF-κB signaling pathway and immune checkpoint regulators contribute to immune escape and persistent activation of the immune system. Mutations in genes like MYD88 and CD79B are frequently observed and are associated with the activation of proinflammatory pathways [9].

The clinical course of the disease is aggressive, with a 5-year overall survival (OS) rate ranging from 46.3% to 52%. Poor prognostic factors include, but are not limited to, old age, nodal involvement, bone marrow involvement, high International Prognostic Index (IPI) scores, and treatment regimen (lack of anthracycline-based chemotherapy and treatment without rituximab are associated with worse outcomes) [10, 11].

We present a case of the HLH variant of IVLBCL diagnosed with skin biopsy. The clinical features, light microscopic findings, and the pathophysiology of HLH in the setting of IVLBCL are discussed.

2 | Case Presentation

The patient was a 72-year-old female with a history of hypertension, presenting with new-onset fever temporarily relieved by Tylenol ingestion and severe generalized weakness. She subsequently developed reticulated erythematous patches covering approximately 50% of the abdomen and back (Figure 1). On admission, laboratory findings included anemia with hemoglobin of 7.9 mg/dL (baseline: 11 g/dL; normal range: 12.3–15.3 g/dL), ferritin of 1800 ng/mL (normal range: 10–150 ng/mL), hypertriglyceridemia (1154 mg/dL; normal value < 150 mg/dL), elevated haptoglobin, positive direct Coombs test for IgG and C3, high C-reactive protein (CRP) of 197 (normal value < 0.3 mg/dL), and high erythrocyte sedimentation rate (ESR) of 67 (normal range: 0–30 mm/hr). In addition, a bone marrow biopsy showed a minute atypical B-cell population identified by flow cytometry. The B-cells did not constitute a large percentage of the bone marrow cellularity (estimated to be around 2%-3%). However, the gastrointestinal evaluation and infectious disease workup were negative.

Rheumatology was concerned about adult Still's disease; hence, the patient was started on an 11-day high-dose methylprednisolone (40 mg every 8 h) on Day 2 of admission. On Day 12 of admission, the patient received a single dose of tocilizumab (anti-

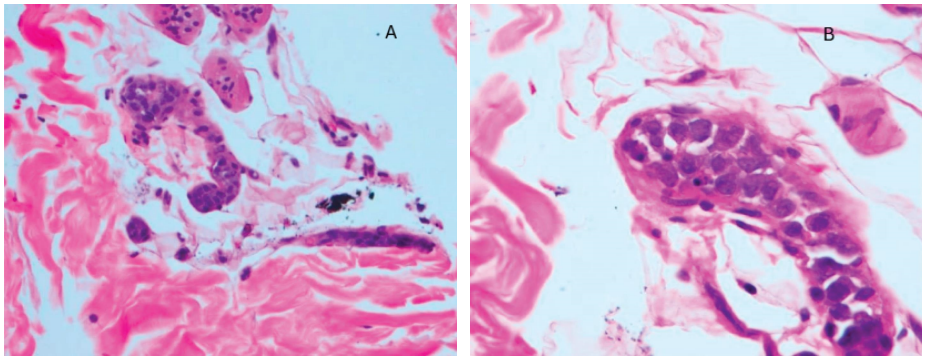

FIGURE 2 | H&E ((A) 40X, (B) 100X) photomicrograph showing a high-power view of atypical lymphocytes with hyperchromatic pleomorphic nuclei with irregular nuclear contour situated within small-sized dermal blood vessels.

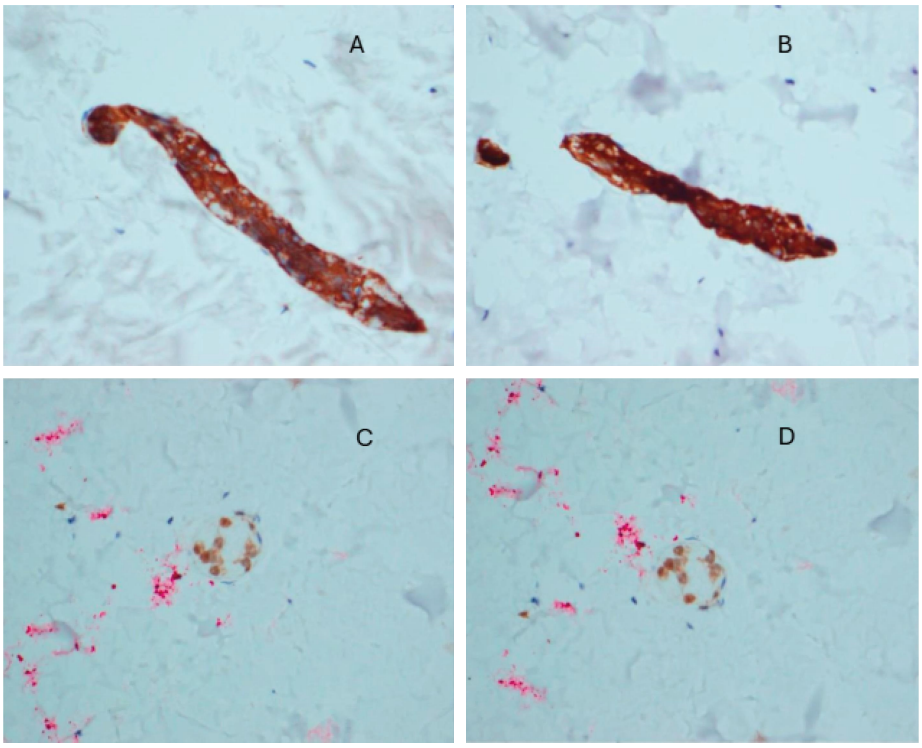

FIGURE 3 | Photomicrograph (all at 40X magnification) showing intravascular neoplastic cells exhibiting strong membranous staining for CD20 (A), strong membranous staining for CD79a (B), nuclear staining of moderate intensity for PAX5 (C), and nuclear staining of moderate intensity for BCL6 (D).

IL-6R), followed by a 5-day course of anakinra (IL-1 receptor antagonist) for the treatment of refractory adult Still's disease, with no improvement of symptoms. At this point, she met the diagnostic criteria for HLH (fever, hemoglobin < 9 [normal range: 12.3–15.3 g/dL], triglycerides > 265 [normal value < 150 mg/dL], ferritin > 3000 [normal range: 10–150 ng/mL], and IL-2Ra > 2 standard deviations above the upper limit of normal [normal range: 532–1891 pg/mL]). The patient was then maintained on prednisolone 60 mg daily for HLH treatment with minimal improvement. About 3 weeks after admission, a biopsy of the abdominal skin exhibiting livedoid change was performed. The skin biopsy was diagnostic of IVLBCL (as described below).

The skin biopsy showed highly atypical large lymphocytes residing quiescently within the vascular lumen of many dermal and subcutaneous microvessels (Figure 2). The affected vessels were primarily capillaries and venules. The extent of vascular occlusion was more evident in the mid and deeper aspects of the biopsy and in the microvessels of the adventitial dermis. The atypical cells were in the range of 15–20 μm in size and exhibited round, oval, or irregularly contoured nuclei with enlarged nucleoli. Additionally, a few endoneurial vessels contained similar atypical cells. There were occasional intravascular histiocytes exhibiting reniform nuclei and cytoplasmic cellular debris, whereby they were juxtaposed to neoplastic B-cells.

The malignant intravascular cells throughout the dermis and fat were extensively highlighted by CD20 (Figure 3(A)), CD79a (Figure 3(B)), and PAX5 (Figure 3(C)), confirming the B-cell lineage of these neoplastic cells. The B-cells further showed a strong nuclear staining pattern for BCL6 (Figure 3(D)) but were negative for CD10 (Figure 4(B)). The CD163 stain highlights intravascular macrophages and demonstrates their close association with intravascular neoplastic B-cells (Figure 4(A)). Table 1 summarizes the important immunophenotype for this case.

No molecular testing was conducted in this case, as the IVLBCL diagnosis was based on morphology and immunohistochemical results.

Following the diagnosis of IVLBCL, a positron emission tomography (PET) scan revealed a nonenlarged spleen with diffuse avidity, a few subcentimeter thoracic and abdominal lymph nodes with avidity, and left adrenal avidity. Furthermore, the CSF examination revealed a few atypical lymphocytes. Consequent to the IVLBCL diagnosis, the patient was commenced on polatuzumab vedotin (Polivy), rituximab, cyclophosphamide, doxorubicin, and prednisone (Pola-R-CHP) and high-dose methotrexate therapy. The treatment course was complicated by neutropenic fever managed with piperacillin/tazobactam. Currently (5 months after IVLBCL treatment initiation), the patient has completed 6 cycles of Pola-R-CHP and 3 cycles of high-dose methotrexate therapy with clinical improvement. Furthermore, a repeat PET scan showed a reduction in spleen and lymph node avidity. The plan is to repeat the chemotherapy regimen and perform a total body scan for further improvement and, hopefully, remission.

3 | Discussion

We have presented a case of IVLBCL complicated by HLH. The neoplastic cells were large and showed BCL6 positivity, suggesting a germinal center phenotype. There were CD163-immunostained intravascular histiocytes, with cytoplasmic

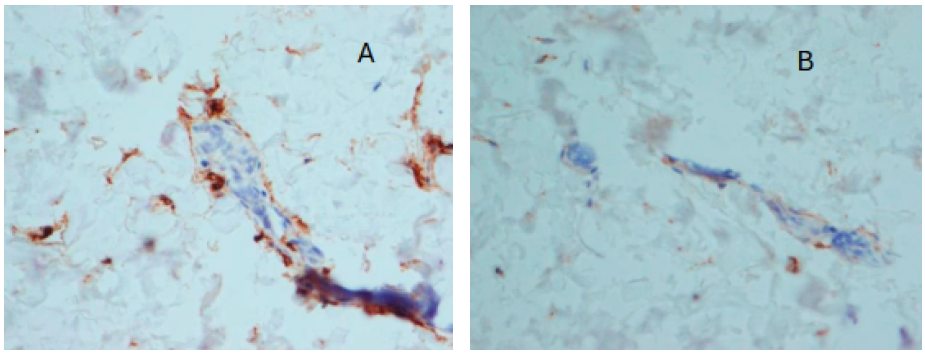

FIGURE 4 | Photomicrograph showing rare intravascular monocytes closely juxtaposed to the neoplastic cells as highlighted by CD163 ((A) 40X). The neoplastic cells show negative immunostaining for CD10 ((B) 40X).

TABLE 1 | The staining protocol for IVLBCL.

Marker	Description	Result in our case
CD20	B-cell marker, positive in most IVLBCL cases	Positive
CD79a	B-cell marker, positive in most IVLBCL cases	Positive
PAX5	B-cell marker, positive in most IVLBCL cases	Positive
BCL6	Germinal center marker, positive in a subset of IVLBCL cases	Positive
CD10	Germinal center marker, typically negative in IVLBCL	Negative
CD163	Macrophage marker	Positive

cellular debris, situated in proximity to the malignant B-cells. We hypothesize that this microscopic appearance represents the intimate interaction between the neoplastic cells and intravascular macrophages, with subsequent activation and cytokine elaboration, a phenomenon that underlies the pathophysiologic mechanism of IVLBCL-induced HLH.

IVLBCL is an uncommon form of non-Hodgkin lymphoma (NHL) characterized by the proliferation of neoplastic B-cells exclusively within the lumen of blood vessels [12]. Similar to this case, patients may present with fever, respiratory symptoms, cytopenias, elevated serum lactate dehydrogenase levels, hypotension, dermatological manifestations, and hepatosplenomegaly [13]. As described in this patient, IVLBCL is documented to cause HLH, a severe disease characterized by hemophagocytosis, hyperferritinemia, hypertriglyceridemia, and hypofibrinogenemia, among other symptoms [8, 13, 14]. Secondary IVLBCL occurs from recurrence or transformation of a previously diagnosed B-cell lymphoma, potentially having a different prognosis [15, 16].

The diagnosis of IVLBCL can be made through histological examination of either a cutaneous lesion (as in this case) or random biopsies of normal skin [17]. Due to the proclivity of the neoplastic cells to localize to blood vessels of the fat, the ideal sites of biopsy should be abundant in subcutaneous fat, and therefore, three random biopsies from the thigh, abdomen, and buttock are ideal. Microscopically, IVLBCL is characterized by large, atypical lymphocytes within the lumen of small blood vessels. Like the case described above, the neoplastic cells are positive for CD20, CD79a, and PAX5. Variable staining may be observed for MUM1, BCL6, BCL2, and CD5, whereas CD3 and CD10 are typically negative [18, 19].

The malignant cells in IVLBCL are postulated to originate from either a late-stage germinal center B-cell (as described in this patient) or post-germinal center B-cells based on the staining for BCL6 and CD5, respectively [20, 21]. Kanda and colleagues supported this claim in a study that demonstrated the presence of frequent mutations involving the genes for immunoglobulin heavy-chain (IgH) variable region in the majority of IVLBCL cases, indicating that these neoplastic cells have undergone somatic hypermutation, a phenomenon that occurs in the germinal center [20].

The intravascular localization of neoplastic B-cells in IVLBCL is multifactorial. There is typically an absence of CD29 (β1 integrin) and CD54 (ICAM-1), which are essential for lymphocyte trafficking and transvascular migration [22]. Also, the expression of chemokines like CXCR3 by the tumor cells may facilitate their intravascular retention [23].

HLH in the setting of IVLBCL was first reported in the medical literature by Dufau et al. in 2000, where they described the clinical and pathological features of the condition in two patients [24]. Since then, eight additional cases have been further described in the literature, highlighting the extreme rarity of this entity [9, 25, 26]. IVLBCL-induced HLH is more frequently reported in Asian populations compared to Western populations, with median age of patients within the seventh decade and a slight male preponderance [6, 10]. The outcome of patients with IVLBCL and HLH is generally poor, with a median survival of a few months, even in the setting of aggressive treatment [27].

HLH in the setting of IVLBCL is a complex phenomenon that is believed to occur because of multiple mechanisms, including bone marrow tumor infiltration and macrophage activation [6, 28]. The activated macrophages in this case were often found adjacent to the neoplastic B-cells. The macrophages can express

programmed death-ligand 1 (PD-L1), which may contribute to immune evasion by the tumor cells [9]. There is also an associated inability of cytotoxic T-lymphocytes and natural killer cells to lyse the activated macrophages, resulting in the amplification of downstream proinflammatory cytokines [29]. A cytokine storm ensues and is hallmarked by elevated TNF-α, IFN-γ, and IL-6, which lead to the clinical manifestation of HLH [9, 22, 25].

Finally, according to the recommendations of the North American Consortium for Histiocytosis (NACHO), IVLBCL presenting with HLH-like features is categorized as a disease that mimics HLH rather than representing true HLH [30].

Funding

No funding was received for this manuscript.

Consent

Informed consent was obtained from the patient for publication of this report.

Conflicts of Interest

The authors declare no conflicts of interest.

Data Availability Statement

The data are available for the journal review.

References

1. S. H. Swerdlow, E. Campo, S. A. Pileri, et al., "The 2016 Revision of the World Health Organization Classification of Lymphoid Neoplasms," *Blood* 127, no. 20 (2016): 2375–2390, https://doi.org/10.1182/blood-2016-01-643569.

2. M. V. Irigoín, C. Oliver, G. Gualco, and G. D. Galvez, "Intravascular Large B-Cell Lymphoma Presented as Hemophagocytic Lymphohistiocytosis," *Hematology Transfusion and Cell Therapy* 45, no. 1 (2021): 116–118, https://doi.org/10.1016/j.htct.2021.05.008.

3. D. J. Rajyaguru, C. Bhaskar, A. J. Borgert, A. Smith, and B. Parsons, "Intravascular Large B-Cell Lymphoma in the United States (US): a Population-Based Study Using Surveillance, Epidemiology, and End Results Program and National Cancer Database," *Leukemia and Lymphoma* 58, no. 9 (2017): 2080–2088, https://doi.org/10.1080/10428194.2017.1287363.

4. M. Ponzoni, E. Campo, and S. Nakamura, "Intravascular Large B-cell Lymphoma: a Chameleon with Multiple Faces and Many Masks," *Blood* 132, no. 15 (2018): 1561–1567, https://doi.org/10.1182/blood-2017-04-737445.

5. V. Brunet, S. Marouan, J. P. Routy, et al., "Retrospective Study of Intravascular Large B-cell Lymphoma Cases Diagnosed in Quebec: a Retrospective Study of 29 Case Reports," *Medicine* 96, no. 5 (2017): e5985, https://doi.org/10.1097/md.0000000000005985.

6. T. Murase, S. Nakamura, K. Kawauchi, et al., "An Asian Variant of Intravascular Large B-Cell Lymphoma: Clinical, Pathological and Cytogenetic Approaches to Diffuse Large B-Cell Lymphoma Associated with Haemophagocytic Syndrome," *British Journal of Haematology* 111, no. 3 (2000): 826–834, https://doi.org/10.1046/j.1365-2141.2000.02426.x.

7. E. J. Vick, K. Patel, P. Prouet, and M. G. Martin, "Proliferation Through Activation: Hemophagocytic Lymphohistiocytosis in Hematologic Malignancy," *Blood Advances* 1, no. 12 (2017): 779–791, https://doi.org/10.1182/bloodadvances.2017005561.

8. M. Miyahara, M. Sano, K. Shibata, et al., "B-Cell lymphoma-associated Hemophagocytic Syndrome: Clinicopathological Characteristics," *Annals of Hematology* 79, no. 7 (2000): 378–388, https://doi.org/10.1007/s002770000155.

9. B. Gonzalez-Farre, J. E. Ramis-Zaldivar, N. Castrejón de Anta, et al., "Intravascular Large B-Cell Lymphoma Genomic Profile is Characterized by Alterations in Genes Regulating NF-κB and Immune Checkpoints," *The American Journal of Surgical Pathology* 47, no. 2 (2022): 202–211, https://doi.org/10.1097/pas.0000000000001978.

10. T. Murase, M. Yamaguchi, R. Suzuki, et al., "Intravascular Large B-cell Lymphoma (IVLBCL): a Clinicopathologic Study of 96 Cases with Special Reference to the Immunophenotypic Heterogeneity of CD5," *Blood* 109, no. 2 (2007): 478–485, https://doi.org/10.1182/blood-2006-01-021253.

11. A. Bonnet, C. Bossard, G. Ludovic, et al., "Clinical Presentation, Outcome, and Prognostic Markers in Patients with Intravascular Large B-Cell Lymphoma, a Lymphoma Study Association (LYSA) Retrospective Study," *Cancer Medicine* 11, no. 19 (2022): 3602–3611, https://doi.org/10.1002/cam4.4742.

12. M. Ponzoni, A. J. M. Ferreri, E. Campo, et al., "Definition, Diagnosis, and Management of Intravascular Large B-Cell Lymphoma: Proposals and Perspectives from an International Consensus Meeting," *Journal of Clinical Oncology* 25, no. 21 (2007): 3168–3173, https://doi.org/10.1200/jco.2006.08.2313.

13. T. Okuno, S. Iwata, H. Hayakawa, K. Miyao, and T. Kajiguchi, "Clinical Features of Intravascular Large B-cell Lymphoma: a single-institute Retrospective Analysis," *[Rinsho ketsueki] The Japanese Journal of Clinical Hematology* 60, no. 3 (2019): 184–190, https://doi.org/10.11406/rinketsu.60.184.

14. S. Canna and R. A. Marsh, "Pediatric Hemophagocytic Lymphohistiocytosis (HLH)," *Blood* 135, no. 16 (2020).

15. X. F. Zhao, A. M. Sands, P. T. Ostrow, R. Halbiger, J. T. Conway, and A. Bagg, "Recurrence of Nodal Diffuse Large B-Cell Lymphoma as Intravascular Large B-Cell Lymphoma: Is an Intravascular Component at Initial Diagnosis Predictive?" *Archives of Pathology & Laboratory Medicine* 129, no. 3 (2005): 391–394, https://doi.org/10.5858/2005-129-391-rondlb.

16. K. Asagoe, W. Fujimoto, T. Yoshino, et al., "Intravascular Lymphomatosis of the Skin as a Manifestation of Recurrent B-cell Lymphoma," *Journal of the American Academy of Dermatology* 48, no. 2 (2003): S1–S4, https://doi.org/10.1067/mjd.2003.112.

17. C. M. Magro, C. Stephan, and T. Kalomeris, "The Utility of the Normal Thin Section Skin Biopsy in the Assessment of systemic/extracutaneous Disease and Small Fiber Neuropathy," *Clinics in Dermatology* 42, no. 6 (2024): 646–667, https://doi.org/10.1016/j.clindermatol.2024.09.020.

18. Y. Han, Q. Li, D. Wang, et al., "Case Report: Intravascular Large B-Cell Lymphoma: a Clinicopathologic Study of Four Cases with Review of Additional 331 Cases in the Literature," *Frontiers in Oncology* 12 (2022): 883141, https://doi.org/10.3389/fonc.2022.883141.

19. Y. Kong, B. Dai, W. Sheng, et al., "Intravascular Large B-Cell Lymphoma with Cutaneous Manifestations: A Clinicopathologic, Immunophenotypic and Molecular Study of Three Cases," *Journal of Cutaneous Pathology* 36, no. 8 (2008): 865–870, https://doi.org/10.1111/j.1600-0560.2008.01168.x.

20. M. Kanda, J. Suzumiya, K. Ohshima, et al., "Analysis of the Immunoglobulin Heavy Chain Gene Variable Region of Intravascular Large B-Cell Lymphoma," *Virchows Archiv* 439, no. 4 (2001): 540–546, https://doi.org/10.1007/s004280100398.

21. M. Kanda, J. Suzumiya, K. Ohshima, K. Tamura, and M. Kikuchi, "Intravascular Large Cell Lymphoma: Clinicopathological, Immuno-Histochemical and Molecular Genetic Studies," *Leukemia & lymphoma/Leukemia and lymphoma* 34, no. 5-6 (1999): 569–580, https://doi.org/10.3109/10428199909058485.

22. M. Ponzoni, G. Arrigoni, V. E. Gould, et al., "Lack of CD 29 (Beta1 Integrin) and CD 54 (ICAM-1) Adhesion Molecules in Intravascular Lymphomatosis," *Human Pathology* 31, no. 2 (2000): 220–226, https://doi.org/10.1016/s0046-8177(00)80223-3.

23. M. Kato, K. Ohshima, M. Mizuno, et al., "Analysis of CXCL9 and CXCR3 Expression in a Case of Intravascular Large B-cell Lymphoma," *Journal of the American Academy of Dermatology* 61, no. 5 (2009): 888–891, https://doi.org/10.1016/j.jaad.2009.02.007.

24. J. P. Dufau, A. Le Tourneau, T. Molina, et al., "Intravascular Large B-Cell Lymphoma with Bone Marrow Involvement at Presentation and Haemophagocytic Syndrome: Two Western Cases in Favour of a Specific Variant," *Histopathology* 37, no. 6 (2000): 509–512, https://doi.org/10.1046/j.1365-2559.2000.00980.x.

25. J. Wen, J. Xu, J. Ji, et al., "Intravascular Large B-cell Lymphoma as a Covert Trigger for Hemophagocytic Lymphohistiocytosis Complicated With Capillary Leak Syndrome: a Case Report and Literature Review," *Frontiers in Immunology* 15 (2024): 1403376, https://doi.org/10.3389/fimmu.2024.1403376.

26. L. Veloza, C. Y. Tsai, B. Bisig, et al., "EBV-Positive Large B-cell Lymphoma with an Unusual Intravascular Presentation and Associated Haemophagocytic Syndrome in an HIV-Positive Patient: Report of a Case Expanding the Spectrum of EBV-Positive Immunodeficiency-Associated Lymphoproliferative Disorders," *Virchows Archiv* (2021).

27. A. J. Ferreri, G. P. Dognini, E. Campo, et al., "Variations in Clinical Presentation, Frequency of Hemophagocytosis and Clinical Behavior of Intravascular Lymphoma Diagnosed in Different Geographical Regions," *Haematologica* 92, no. 4 (2007): 486–492, https://doi.org/10.3324/haematol.10829.

28. E. Siddall, M. Khatri, and J. Radhakrishnan, "Capillary Leak Syndrome: Etiologies, Pathophysiology, and Management," *Kidney International* 92, no. 1 (2017): 37–46, https://doi.org/10.1016/j.kint.2016.11.029.

29. C. Gioia, M. Paroli, R. Izzo, et al., "Pathogenesis of Hemophagocytic Lymphohistiocytosis/Macrophage Activation Syndrome: A Case Report and Review of the Literature," *International Journal of Molecular Sciences* 25, no. 11 (2024): 5921, https://doi.org/10.3390/ijms25115921.

30. M. B. Jordan, C. E. Allen, J. Greenberg, et al., "Challenges in the Diagnosis of Hemophagocytic Lymphohistiocytosis: Recommendations from the North American Consortium for Histiocytosis (NACHO)," *Pediatric Blood and Cancer* 66, no. 11 (2019): e27929, https://doi.org/10.1002/pbc.27929.